

Faculty of veterinarian science, Szent Istvan University
Department and clinic of Equine medicine

OSTEOMYELITIS IN FOALS, A RETROSPECTIVE CASE SERIES

Ine Refseth

Supervisor: Dr. Balázs Tóth, MS, MSc, Dipl. ACVIM & ECVIM
Department and clinic of Equine medicine
Szent Istvan University
Budapest 2015

Summary

In this study we examined cases involving osteomyelitis in foals without concurrent septic arthritis, we concentrated the study around cases of e-type osteomyelitis where the synovial structure was not involved. Looking particularly into clinical etiology, diagnostic approaches and treatment. To gain a better understanding of the differences, we compared the findings with findings in previous published studies on septic arthritis/ osteomyelitis. Though several studies are done on osteomyelitis with concurrent septic synovitis, not much is known about osteomyelitis without synovial involvement.

To gain a better understanding of this topic we reviewed cases from Hagyard Equine Medical Institute on osteomyelitis without concurrent septic synovitis. Foals were included in the study if they were under 1 year old, have radiographic or other imaging evidence of osteomyelitis and exhibit relevant clinical signs.

In our study we found that the most common bacteria isolated was *Rhodococcus equi*, most foals presented with leukocytosis and hyperfibrinogenemia. The septic focus could be found all over the body but the most common placement was the vertebral column. No typical antibiotic combination was administered, though Clarithromycin was the most commonly chosen antibiotic. We also had a 90% survival rate and the number of horses raced was similar to studies published on osteomyelitis/septic arthritis.

Compared to the previous published studies the survival rate in our study was significantly higher, the number of *Rhodococcus equi* was also significantly higher. In our study hyperbaric oxygen therapy was used as additional therapy, this is not documented in previously published studies.

Table of Contents

SUMMARY	2
1. INTRODUCTION	4
2. REVIEW OF THE LITERATURE	5
2.1 FEATURES OF OSTEOMYELITIS	5
2.2 OSTEOMYELITIS IN FOALS	5
2.2.1 <i>Predisposing factors</i>	5
2.2.2 <i>Causative agents of Osteomyelitis</i>	6
2.2.3 <i>Pathogenesis of Osteomyelitis.</i>	7
2.2.4 <i>Clinical findings</i>	9
2.2.5 <i>Diagnosis</i>	9
2.2.6 <i>Treatment</i>	11
2.2.7 <i>Prognosis</i>	12
3. MATERIALS AND METHODS	14
3.1 CASE SELECTION	14
3.2 COLLECTION OF DATA	14
3.3 LABORATORY AND CLINICAL METHODS	15
3.4 LITERATURE DATA ANALYSIS	15
3.5 STATISTICS	16
4. RESULTS	17
4.1 SIGNALMENT, HISTORY, AND PHYSICAL EXAMINATION	17
4.2 DIAGNOSTIC EVALUATION	18
4.3 MICROBIOLOGIC FINDINGS	20
4.4 HOSPITALIZATION	21
4.5 TREATMENT	21
4.6 ADDITIONAL THERAPIES	22
4.7 OUTCOME	23
5. DISCUSSION	25
6. ACKNOWLEDGMENTS	30
7. REFERENCES	31

1. Introduction

Osteomyelitis can occur in several forms, in adult horses it is most commonly originated from an external trauma or from an iatrogen source. In foals a hematogenous route of infection is more common. Hematogenous osteomyelitis may occur in neonates or in sucklings secondary of distant septic foci that gained access to the systemic circulation. According to the scientific data and anecdotal sources, osteomyelitis can occur in any osseous structure with an epiphyseal growth plate, however is most often noted adjacent to septic synovial structures following local invasion of infection and far less commonly seen as a seldom entity.

Several other studies were documented in which osteomyelitis was seen in combination with septic synovial structures. Data describing septic osteomyelitis without concurrent synovial involvement are scarce. There is an overall paucity of information regarding etiology, localization, diagnostic criteria, treatment options and prognosis in this clinical entity. To obtain objective data regarding hematogenous septic osteomyelitis, without concurrent septic synovial involvement, I have reviewed medical records from Hagyard Equine Medical Institute from 2007 to 2015 using the inclusion criteria outlined previously. Following analysis of the data, a comparison regarding determining parameters were carried out to those published about osteomyelitis with concurrent septic synovial structures.

2. Review of the literature

2.1 Features of Osteomyelitis

Osteomyelitis is defined as a microorganism initiated inflammatory process of an osseous structure, leading to periosteal inflammation and structural demise of the bone (Lew and Waldvogel, 2004). The process might be soliter, disseminated or multicentric. Terminology is often imprecise as clinically osteitis and osteomyelitis is difficult to distinguish (Goodrich, 2006). Infections in the bony structures can be divided into two main groups, those that occur iatrogenically in cases of diagnostic or therapeutic interventions and those that occur “naturally” via traumatic hematogenous route (Richardson and Ahern, 2012).

2.2 Osteomyelitis in foals

The age groups, in which septic hematogenous osteomyelitis can occur more commonly, include neonates and sucklings. Osteomyelitis is considered as a life threatening or career ending disease due to its manifestation and possible long-term sequelae. Osteomyelitis might be a fatal consequence of septic arthritis and synovitis (Firth, 1983; Firth et al., 1980). It can occur through several routes in foals including traumas, penetrating injuries and or via hematogenous spread of infection (Firth, 1983).

Due to high morbidity of equine neonatal sepsis, osteomyelitis, osteitis and septic arthritis occurs secondarily and considered as one of the most severe and devastating complications of bacteremia and septicemia (Hardy, 2006)

2.2.1 Predisposing factors

Since septic osteomyelitis in foals is primarily caused via the hematogenous route and as a complication of neonatal septicemia the preexisting factors of the latter can also lead to osteomyelitis. Septicemia is still considered to have a major role in neonatal mortality (Paradis, 1994), even though recent studies demonstrate that the prognosis has improved due to advancements in neonatal intensive care (Sanchez et al., 2008). Similarly a recent study has revealed that the survival rate of osteomyelitis with concurrent septic synovitis

has increased due to improved prevention, early recognition and surveillance in large breeding operations (Neil et al., 2010).

The predisposing factors of septicemia can be of maternal (or prenatal) and postnatal origin. The most important prenatal factors include dystocia, placentitis and premature separation of the placenta among others (Sanchez, 2005). Failure of transfer of passive immunity (FTPI) by immunoglobulins is considered as the most crucial postnatal factor.

The umbilicus, respiratory tract and the gastrointestinal tract are the main routes of infection, with the umbilicus traditionally regarded as the most common route of infection, though recently the intestines are believed to have a more significant role (Sanchez, 2005). Interestingly a study done by Sanchez et al. (2008) showed that “*an association between omphalitis and infectious orthopedic conditions is not evident*”.

2.2.2 Causative agents of Osteomyelitis

Several studies have collected data about causative agents of osteomyelitis/ septic arthritis. The most common bacteria in early studies discovered the role of *Enterobacter spp*, *E.coli*, *Actinobacillus spp*, *Salmonella spp*. and *Streptococcus spp*. (Firth, 1983). Recent studies show that isolates from joints include mainly *Streptococcus spp*, followed by *Staphylococcus spp.*, while *E. coli* is most commonly isolated from bone and *Salmonella* from blood (Neil et al., 2010). The latter is in agreement with older studies (Firth, 1983). Several studies have elucidated the increased proportion of Gram-positive organisms from septic synovial structures and from hemocultures (Mars and Palmer, 2001; Neil et al., 2010).

According to a different study, *E.coli* continues to be the most common bacteria isolated via hemoculture while organism including *Actinobacillus*, *Salmonella* and enteric gram negative bacteria traditionally having had higher incidence, started to get less common by now (Sanchez et al., 2008). The same study also showed a link between gram-negative bacteria and the development of osteomyelitis (Sanchez et al., 2008). Other literature sources from the same decade, revealed that *Actinobacillus*, *Salmonella* and enteric gram-negative bacteria still are among the most commonly isolated bacteria in septicemic and bacteremic foals (Stewart et al., 2002; Marsh and Palmer, 2001). Since osteomyelitis is

considered as a manifestation of hematogenous spread of bacteria, organisms able to cause bacteremia are expected to cause the disease as well. In addition *Rhodococcus equi* is a common bacteria isolated from extrapulmonary sites including the physis and this should be taken into consideration when formulating a treatment regimen (Braid et al., 1990). Cases of osteomyelitis caused by *Rhodococcus equi* have been reported (Firth et al., 1993;). The study published by Reuss et al. (2009) presented that among the types of extrapulmonary infections caused by *Rhodococcus equi* only 3% of the 150 foals suffered from osteomyelitis, while the proportion of synovitis was slightly higher at (9%). Cases have been reported both in foals with and without pneumonia, having this in mind *Rhodococcus equi* should always be considered especially in foals originating from farms where the organism is endemic (Reuss et al, 2009).

2.2.3 Pathogenesis of Osteomyelitis.

The pathogenesis of osteomyelitis is quite different depending on the age of the horses, while adult horses mainly develop osteomyelitis as a consequence of iatrogenic infection, secondary to surgeries both with and without surgical implants (plates and screws). Foals mostly develop it as a result of septicemia and bacteremia in young age (Goodrich, 2006)

The anatomical structure and vascular network of bone is a well-known contributor to osteomyelitis and has been well described. The nutrient artery supplies the metaphysis with blood. In addition to this, a transphyseal vessel exists in young foals, this connects the blood supply of the epiphysis with that of the metaphysis (Firth, 1983). A sluggish blood flow and low oxygen tension develop in the venous sinusoids and vascular loops of the metaphysis providing the bacteria a better environment to colonize and replicate (Firth and Poulos, 1987).

Four different types of hematogenous infections are currently accepted, S-, E-, P- and T-type infections.

An s-type infection involves only the synovial membranes and fluid, foals suffering from this type of infection tend to be neonates, usually less than 2 weeks of age. The larger joints are most commonly involved, with the femorotibial and the tarsocrural being the most common. Any other articular structure can be affected and a tendency of several

joints affected is often seen. The axial skeleton, tarsal joint and interphalangeal joints are rarely represented in this group (Richardson and Ahern, 2012).

E- type infections involve the expanding epiphysis in a growing animal, more specifically the articular epiphyseal complex. This type of infection is more commonly seen in older, suckling foals, but similarly multiple joints could be involved even though single articular E-type infections are also frequently seen. Insufficient transfer of immunoglobulins or preexisting bacterial diseases are not infrequent. As with s-type infection any joint can be involved but the most common ones are tibia, radius, talus and distal femur (Richardson and Ahern, 2012)

When the infection mainly involves the long bone physis and the infection is seen on the metaphyseal side of the growth plate it is identified as a P-type infection. The infection can extend into the nearby joints but may also occur without involving any joint. In cases where extension into the joint happens, this usually occurs close to the attachment of the joint capsule. Foals diagnosed with p-type are usually a few weeks to a few months old (Richardson and Ahern, 2012). Nevertheless, p-type infections were reported in neonatal foals in a more recent study (Neil et al., 2010).

The last type is the t-type infection of the small carpal and tarsal bones in premature foals (Richardson and Ahern, 2012).

The role of age in the different type of infection appears to be due to the changes in the vascular supply. In neonatal foals the bacteria lodge in the subchondral bone and the synovial membrane due to the transphyseal vessel. This vessel closes as the foal gets older and the infection is more commonly seen in the metaphyseal loop (Firth, 1983).

The most commonly reported sites of osteomyelitis are the femur, tibia and third metacarpal /metatarsal bones (Firth and Goedegebuure, 1988), although osteomyelitis in ribs (Neil et al., 2010), vertebrae (Reuss et al., 2009) and even the patella can occur (Kay et al. 2012).

2.2.4 Clinical findings

Foals presented with lameness should always be considered as having potential septic synovial structures until proven otherwise. Similarly, foals suffering from septicemia are at risk of developing complications including osteomyelitis, although recognition of the disease is usually delayed several days to weeks following the clinical signs of septicemia. Painful sites, heat and swelling as general indications of inflammation are often accompanying the lameness. Periarticular edema and joint effusion are typically seen in cases of S- and E-type infection. In cases where the physis is involved, effusion depends on the localization of the infection according to the growth plate. Physeal infection can occur both with joint effusion but also without, where the infection rather breaks through the skin than into the joint. In joints or bones that are covered with thick muscle layers, palpation can be cumbersome and other diagnostic methods might be necessary (Hardy, 2006).

Some of the clinical signs will depend on the location of osteomyelitis is situated. For example a foal presenting with stiffness and pain of the upper neck region in combination with torticollis may look like a neurological problem, where further investigation may show osteomyelitis of the spine (Roberts et al., 2010). Thorough examination of a foal exhibiting spinal ataxia may reveal osteomyelitis lesion in the occipital bone (Morresey et al., 2010). Lameness might be hidden for a period of time and foals present with swellings in various places (Neil et al., 2010).

In addition to lameness, foals suffering from osteomyelitis are known to have pyrexia, leukocytosis and mature neutrophilia (Marresey, et al, 2010; Kelleher and MacDonald, 2007). Newquist and Baxter (2007) has documented that foals suffering from osteomyelitis have an increase in plasma fibrinogen concentration and that a concentration of $\geq 900\text{mg/dL}$ should be considered as a clinical sign of osteomyelitis.

2.2.5 Diagnosis

Traditionally, radiographs of the affected bones and clinical findings during physical examination are adequate to strongly suspect osteomyelitis/septic arthritis. Since

radiography is limited and insensitive in early stages of osteomyelitis, misdiagnosis is common (Newquist and Baxter, 2009). It is believed that the infection must have caused 50-70% demineralization of bone for osteomyelitis to show on plain radiographs (Goodrich, 2006), which may take up to 2 weeks from the beginning of the process. In addition to radiography, ultrasonography is thought to be a potential diagnostic tool. It is proposed that in cases where osteomyelitis is suspected but could not be confirmed via radiographs, ultrasound might serve as a complementary tool. Such as demonstrated in the three cases with rib osteomyelitis documented by Neil et al. (2010).

Advanced imaging techniques such as CT, MRI and Nuclear scintigraphy could be utilized in the diagnostic work-up or further characterization of a suspected osteomyelitis. Nuclear scintigraphy can be especially useful to identify osteomyelitis in unusual locations, such as the vertebrae and the occipital bone (Hardy, 2006). MRI has been used in a case of osteomyelitis in the occipital bone, where the X-rays did not reveal any abnormalities but changes seen on the MRI were consistent with osteomyelitis (Morresey et al., 2010)

As previously stated most of the foals suffering from osteomyelitis and septic arthritis often have a multisystemic disease, thus evaluation of the leukogram is unspecific as a diagnostic tool in case of septic arthritis. Synovial fluids, on the other hand, are considered helpful for diagnostics purposes, monitoring the progression and detecting causative agents (Trumble, 2005). Alterations of these parameters could have several origins, although paired together with clinical signs including lameness, can provide a suspicion of osteomyelitis.

Plasma fibrinogen, an acute phase marker of inflammation, has been evaluated by Newquist and Baxter (2009). The authors compared foals suffering from osteomyelitis with or without adjacent septic arthritis, foals suffering from septic arthritis alone, foals suffering from pneumonia, and a group of clinically healthy foals. Interestingly this study showed that foals diagnosed with osteomyelitis, both with and without adjacent septic arthritis, had plasma fibrinogen levels above 900 mg/dL. In comparison those diagnosed with septic arthritis alone or with pneumonia had a considerably lower fibrinogen level. Based on this it is shown that measurement of plasma fibrinogen concentration can be a relatively specific diagnostic tool (Newquist and Baxter, 2009). In contrast to this, another

study found fibrinogen of little use since only one of 8 foals diagnosed with patellar osteomyelitis had plasma fibrinogen >900mg/dL (Kay et al., 2012).

In all cases of osteomyelitis and septic arthritis, isolation of the causative agent should be attempted. In septic arthritis synovial fluid can be collected and gram stained as well as cultured via enrichment media (Hardy, 2006). A bacterial culture from the synovial fluid not only ensures proper usage of antibiotics but also helps the practitioner to give a more accurate prognosis to the owner (Taylor et al., 2010). The study performed by Taylor et al. (2010) revealed only 32.5% positive cultures from the synovial fluid. This demonstrates that the sensitivity of synovial growth is poor. This is likely due to low number of live bacteria, lack of proper enrichment media or poor handling of the collected samples (Stoneham, 1997).

In regards to osteomyelitis, aspiration can be attempted from the affected site with the help of fluoroscopic or radiographic guidance (Hardy, 2006). Because these infections are often accompanied with a systemic infection, simultaneous blood culture is a reasonable way to determine potential causative agents. For this purpose large veins should be used and sampling should be aseptically performed with immediate transfer of blood into appropriate enrichment medium (Sanchez, 2005).

2.2.6 Treatment

Traditionally osteomyelitis is treated with systemic antibiotics alone, but that has on several occasions showed to be inefficient due to different properties of parenteral antibiotic choices available for veterinary use. Today, the recommended treatment may also include surgical debridement if possible as well as systemic antibiotics (Goodrich and Nixon, 2004). Recent studies and case reports advocated the efficacy of systemic antibiotics alone in cases where surgical approach is not a viable option (Neil et al., 2010). Lawrence and Fraser (2012) described two successful outcomes with systemic treatment exclusively. Surgical intervention should be considered when the initial treatment doesn't lead to the expected progress (Koch and Witte, 2012).

When choosing antibiotics for the initial treatment of osteomyelitis there are certain criteria that should be considered: bacterial spectrum; the most likely organism;

pharmacokinetic properties; and antimicrobial sensitivity pattern in the geographic area (Koch and Witte, 2012). Prior to antimicrobial results a combination of B-lactames and aminoglycosides is the most common choice (Goodrich and Nixon, 2004), which provides a broad spectrum and a reasonable efficacy against commonly expected bacteria (Marsh and Palmer, 2001; Sanchez et al., 2008). As mentioned earlier some geographic variations of bacteria causing osteomyelitis can occur and this should also be taken into consideration when choosing the initial antibiotics (Koch and Witte, 2012).

In all cases of osteomyelitis a needle aspiration of the affected site and/or blood culture sample should be collected to obtain microbiological data (Hardy, 2006, Close et al., 2010). This should not be the only criteria used while choosing antibiotics, since studies shows that only 33% of blood cultures, will result in isolation of an organism in suspected septicaemia/bacteraemia cases (Marsh and Palmer, 2001). The low sensitivity of blood cultures further emphasizes the importance of attempting needle aspiration from the affected site under permitting circumstances. The patient should be closely monitored and revision of the antibiotic regimen should be considered following further demise or no evidence of improvement within 3-5 days (Close et al., 2010). Close et al. 2010 highlighted the importance of the continuous evaluation, as they reported no clinical improvement in a foal treated with amikacin-sulphate and Potassium penicillin G according to antimicrobial sensitivity (Close et al. 2010).

2.2.7 Prognosis

The prognosis and short term outcome of septic arthritis and osteomyelitis have changed over the last decades; early studies showed a poor prognosis with as low as 23% survival (Steel et al., 1999). It is also reported that foals suffering from septic arthritis together with osteomyelitis have a worse prognosis than animals with septic arthritis alone (Hardy, 2006). A more recent study reported higher short-term survival than earlier, as many as 80.6% was reported to survive (Neil et al., 2010). Though there are differences between case selection and geographic location in these studies, it was concluded that the higher survival rate is due to better trained personnel on the stud farms and more advanced diagnostic and treatment modalities (Neil et al., 2010).

Long-term survival also seems to have the same tendency as short-term survival. In earlier studies it was shown that of the ones that survived to discharge, only one third survived to racing age (Steel et al., 1999). While Neil et al. (2010) reported that 48% of hospitalized foals and 65,8% of those that survived short-time ended up racing and that when the foals reached racing age the factors affected the short-time survival prognosis did not affect the probability of the foal starting in a race (Neil et al., 2010).

Osteomyelitis in the patella reported by Key et al. (2012) states good prognosis for long-term survival and this may be accomplished with an early, aggressive, medical and surgical treatment is provided (Key et al., 2012).

2.2.7a Factors affecting prognosis

Several aspects are believed to affect the outcome of osteomyelitis and septic arthritis, such as the severity and extension of infection, single or multiple joint involvement, localization of infection, whether or not osteomyelitis is accompanied with septic arthritis, systemic condition of the foal and the time of identification and establishment of treatment (Hardy, 2006). The most recent and largest study also revealed that foals diagnosed with osteomyelitis on several sites had a poorer prognosis for short time survival, and for future athletic career. This study did not find any relationship between the location and the short-term survival. On the other hand, they found that foals with P-type infection had a better prognosis, regarding future athletic career than those diagnosed with P-/E- type infection. Foals that had a poor systemic condition had less chance of being discharged and to reach race age. While those that reached race age, the systemic condition did not affect their probability to race (Neil et al. 2010). Even though the prognosis for a positive outcome of osteomyelitis has improved, it should be still considered as guarded and a positive outcome relies on early recognition and proper treatment (Neil et al., 2010; Kay et al., 2012).

3. Materials and methods

3.1 Case selection

Medical records from foals treated at Hagyard Equine Medical Institute between 2007 and 2015 were reviewed and cases with a diagnosis of osteomyelitis without concurrent septic synovitis were selected. To be included in the study the foal had to be less than one year old, had to have radiographic or other imaging evidence of osteomyelitis and exhibit relevant clinical signs (lameness, fever, clinicopathologic alterations). Foals with osteomyelitis with adjacent septic arthritis, or secondary to penetrating wounds, surgery or intra-articular injections were excluded.

3.2 Collection of data

Information obtained from affected animals included signalment (year of admission, age of foals at admission (weeks), breed and gender). Information recorded from the initial physical examination at presentation included rectal temperature, heart rate, respiratory rate, capillary refill time (seconds), degree of lameness (AAEP score) (Ross and Dyson, 2011) and presence of neurological signs were also recorded.

Biochemical findings (total Co₂, total calcium, phosphorus, sodium, chloride, potassium, magnesium, anion gap, glucose, creatinine, serum urea nitrogen, total protein, fibrinogen, bilirubin, globulin and albumin concentration and activity of alkaline phosphatase (ALP), creatine kinase (CK), aspartate aminotransferase (AST), gammaglutamyl transferase (GGT) activity were collected.

Hematologic data (PCV, MCV, MCHC, hemoglobin concentration total white blood cell count, segmented neutrophil band neutrophil count, presence of toxic neutrophils, lymphocyte, and platelet count) and coagulation parameters (PT, PTT) were obtained. Blood culture results and intralesional cultures results (positive or negative), type of organism (Gram positive, negative or anaerobe) recorded.

Length of hospitalization, complications during hospitalization, as well as information on administered antibiotics, anti-inflammatories, plasma or blood transfusion were also

gathered. Radiographic, ultrasonography, scintigraphy and magnetic resonant imaging findings were utilized to define the ultimate diagnosis and localization of the septic focus. Characteristic imaging findings were considered consistent with the diagnosis of osteomyelitis as described in detail elsewhere (Ross and Dyson, 2011).

3.3 Laboratory and Clinical Methods

Blood samples for culture were obtained after clipping and shaving the hair, aseptic preparation of the skin, and removal of 20-40 mL of blood into a sterile syringe from a jugular vein or following sterile placement of an intravenous catheter. The sampling needle then was discarded and separate needles were used to inoculate 3-7 mL of blood into each of the commercially available blood culture bottles. Bacteriological culture were taken from the site of the lesion, and inoculated in blood culture bottles.

For routine biochemical and hematologic analysis, blood was either collected from a large peripheral vein (cephalic, femoral, or saphenous) or from the jugular catheter at the time of catheter placement. Blood was placed into glass tubes containing heparin for serum biochemistry and immunoglobulin qualification, EDTA for hematology, and sodium citrate for fibrinogen concentration. Blood also was collected anaerobically into 3 mL plastic syringes, the dead space of which was filled with sodium heparin (1,000 IU/mL) for blood gas analysis. Venous samples were collected as described above, and arterial samples were collected from either the dorsal metatarsal or the transversal cubital artery. Hemograms were performed with a commercial automated multichannel blood cell counting system with differential counts performed by manual cytological examination of a blood smear. Serum biochemistry was performed with a commercial automated analyzer. Immunoglobulin concentration was determined semi-quantitatively with a commercially available concentration immunoassay technology test. Fibrinogen concentrations were measured with a commercial automated analyzer or with heat precipitation tests.

3.4 Literature data analysis

The data gathered in the current study was compared towards the data collected and published in two previous studies; *Retrospective study of 108 foals with septic osteomyelitis* by Neil et al., 2010 and *Factors associated with prognosis for survival and*

athletic use in foals with septic arthritis: 93 cases by Steel et al., 1999. The data compared were culture results, number of cases with leukocytosis, hyperfibrinogenemia, radiographic findings, short-term outcome (foals survived) and long term follow up (foals raced).

3.5 Statistics

Statistics were performed with commercially available software. Distribution of the data was tested with the Shapiro-Wilk normality test. Continuous data was expressed as medians and ranges, mean and standard deviation. Chi-square test was used to test the differences between categorical variables of the current study and previously published studies. One-way ANOVA with the Bonferroni correction was used to compare this study and other similar studies including cases on osteomyelitis including septic synovitis. For all analyses described above, a 2-sided P- value <0.05 was considered significant.

4. Results

4.1 Signalment, History, and Physical examination

Twenty Thoroughbred foals met the requirement to be included in this study. Among them 10 fillies and 10 colts were present, Further descriptive data is presented Table 1.

Parameters	Sample size (n=)	Mean±SD	Median (min/max)
Age (weeks)	19	12.79±11.73	12 (2-52)
Rectal temperature (°C)	20	38.9±0.43	38,9(37.8-39.5)
Heart rate (bpm)	19	83.68±24.57	80 (82-130)
Respiratory rate	19	33±11.71	32 (18-60)
Lameness score (AAEP)	9	3.44±0.88	3(2-5)

Table 1 Age and Physical examination parameters

The largest age group was 1-3 months (5-12 weeks), which included 55% of the foals. Ten out of the twenty cases had received antibiotic treatment before hospitalization. Seven out of the 20 foals was previous diagnosed with other diseases such as diarrhea (n=1), pneumonia (n=3), septicemia (n=1), rib fracture (n=1) and thromboembolism (n=1).

Ten of the foals (50%) were febrile (>38.9°C) and 7 foals (35%) were tachycardic. Eleven of the twenty (55%) foals presented with lameness, the degree of lameness according to the AAEP ranged from 2 to 5 grades (see Table1). Seven out of the eleven (63.6%) foals that were lame had received antibiotic treatment prior to hospitalization and the duration of lameness previous to hospitalization was not recorded. In addition three (15%) of the foals presented with neurological signs, two with ataxia and one with stupor.

The suspected septic focus of origin was known in 20% (4/20) of the foals, and in every case this was believed to be the lungs. Three of the foals where the lungs were suspected to be the septic focus of origin, had prior to hospitalization been diagnosed and treated for pneumonia.

4.2 Diagnostic evaluation

The descriptive continuous data for the hematology is detailed in Table 2. Eight (53%) of the foals presented with leukocytosis (>14.3K/uL). Comparative data of the hematology is presented in Table 3. Ten (50%) foals presented with neutrophilia (>8K/uL), lymphocytes and platelets were within normal ranged in all foals.

Parameter	Sample size (n=)	Mean±SD	Median (min/max)
WBC (K/uL)	15	17.2±7.27	15.1(7.5-32.8)
Neutrophils (K/uL)	12	11.8±6.33	10.75(4.0-26.1)
Lymphocytes (K/uL)	12	4.27±3.95	3.3(0-16.0)
Platelets (K/μL)	12	422.4±183.8	405.5(153-737)
Plasmafibrinogen on admission (g/dL)	15	726.7±194.5	700(400-1000)
Plasmafibrinogen prior to discharge (g/dL)	10	580±253.9	500(200-1100)
RBC (M/μL)	12	9.33±1.54	9.13(7.41-11.60)
PCV(%)	12	33.48±3.96	32.5(28.6-40.3)
Hemoglobin (g/dL)	12	11.64±1.48	11.1(9.8-14.0)
MCV (fL)	12	36.08±2.68	35.5(32-40)
MCHC (31.0-37.0 g/dL)	12	34.67±1.69	34.6(32.0-37.8)

Table 2. Hematology results, Mean±SD, median and min/max.

Plasma fibrinogen concentration on initial blood work (Table 2) was available for 15 foals, 12 of 15 (80%) presented with hyperfibrinogenemia (>400g/dL). Four of 15 foals (26.7%) had serum fibrinogen concentration above 900g/dL.

For 10 of the 20 foals the fibrinogen levels prior to discharge were available; for 8 of 10 (80%) foals the hyperfibrinogenemia was still not resolved, 7 (87.5%) of these were decreased but still above 400g/dL, while for one foal (12.5%), the fibrinogen level had increased from 800g/dL to 1100g/dL The remaining hematology (Table 2) was within reference ranges for all foals.

Comparative data between the current study and previously published studies concerning hematology can be seen in Table 3

Parameter	Current study	Neil et al., 2010	Steel et al., 1999	P-value
Leucocytosis	8/15	36/68	21/48	0.571
Leucopenia	0/15	1/68	6/48	0.0128
Hyperfibrinogenemia	12/14	59/68	48/48	0.175

Table 3 Comparison data of hematology.

Serum biochemistry at admission was available in 6 of 20 cases, the mean±SD of the relevant parameters can be seen in Table 4. Two foals presented with hyperphosphatemia (>5.8mg/dL). The remaining parameters were within physiological ranges.

Parameters	Reference ranges	Sample size (n=)	Mean±SD	Median (min-max)
Glucose (mg/dL)	76-199	6	134.83±15.39	134.5(116-154)
BUN (mg/dL)	11-26	6	6.67±0.82	6.5 (6-8)
Creatinine (mg/dL)	0.8-1.8	6	1.12±0.17	1.1(0.9-1.4)
Phosphorus (mg/dL)	1.3-6.0	6	5.48±1.21	5.55(4.1-6.8)
Calcium (mg/dL)	11.6-13.3	6	11.37±0.87	11.5(10.2-12.4)
Sodium (mEq/L)	133.0-140.0	6	133.5±1.87	133.5(131-136)
Potassium (mEq/L)	2.5-5.0	5	4.14±0.45	4.3(3.4-4.6)
Chloride (mEq/L)	97-105	6	99.67±3.61	98(97-106)
Carbon dioxide (mEq/L)	25-32	6	25.5±3.62	26.5(19-29)
Anion gap (mEq/L)		6	8.33±1.63	8.5(6-10)
Total protein (g/dL)	6.0-7.9	6	5.78±1.07	5.95(3.8-6.8)
Albumin (g/dL)	3.4-4.1	6	2.68±0.47	2.8 (1.8-3.2)
Globulin (g/dL)		6	3.1±0.75	2.95(2.0-4.0)
AST (U/L)	127-399	6	153.83±30.9	156(107-201)
ALP (U/L)	25.360	6	557.33±207.23	629.5(261-765)
GGT (IU/L)	3-38	6	35.83±21.24	32(13-63)
Bilirubin (mg/dL)	0.7-2.5	6	1.15±0.68	1.25(0-2.0)
CK (U/L)	67-377	6	121.5±51.02	114.5(55-204)

Table 4 Descriptive data of serum biochemical parameters.

Fifteen out of the 20 (75%) foals had radiographic images available; in addition to radiography 4/20 (20%) foals were diagnosed using ultrasonographic imaging and one by scintigraphy. The location of osteomyelitis is presented in Figure 1.

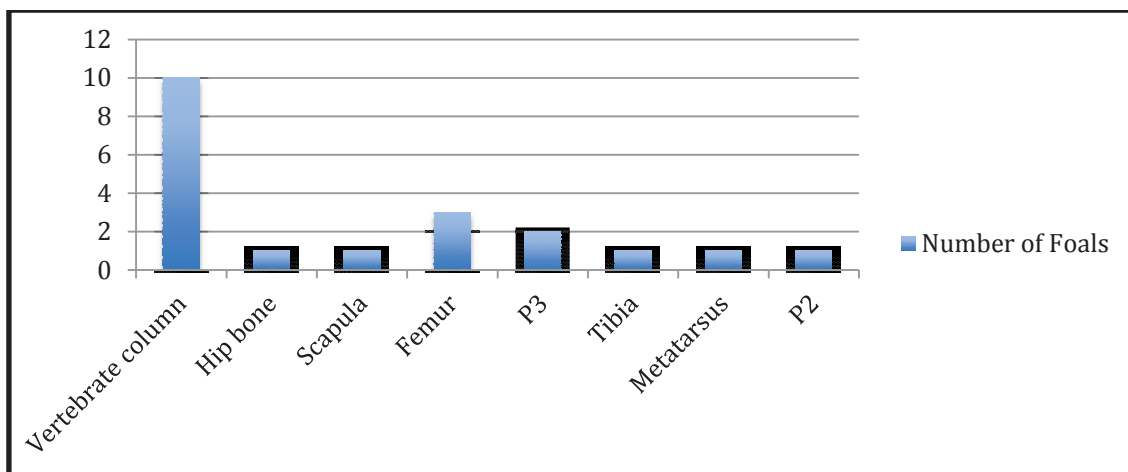


Figure 1 Placement of septic focus.

4.3 Microbiologic findings

Microbial cultures were taken from 19/20 foals, out of these 13 (68.4%) had lesional cultures taken and 6 (31.5%) had blood cultures taken. Nine of the 13 (69.2%) foals that had positive lesional cultures, out of these 6 (46.2%) were positive with *Rhodococcus equi* and 1-1 each for the following *Beta hemolyzing Streptococcus* (n=1), *Alpha hemolyzing Streptococcus* (n=1) and *Staphylococcus* (n=1). *Rhodococcus equi* was significantly more commonly cultured in this study compared to other studies (Neil et al., 2010; Steel et al., 1999) ($p < 0.0001$) Further details are presented in Table 5.

Bacteria cultured	Current study	Neil et al., 2010	Steel et al., 1999	P-value
Rhodococcus equi	6/13	1/45	1/58	<0.0001
Beta streptococcus	1/13	3/45	4/58	0.788
Alpha streptococcus	1/13	6/45	5/58	0.469
Staphylococcus	1/13, 7.7%	7/45	1/58	1

Table 5 Results of microbiological data and statistical comparison to previous study.

In the foals that had blood cultures taken 3, 1 and 1 of the 6 were positive *Rhodococcus equi*, *Actinobacillus* and *Staphylococcus* respectively. None of the foals were diagnosed with the same bacteria from the intralesional culture and the blood culture.

4.4 Hospitalization

Length of hospitalization of the foals ranged from 0 to 20 days with a mean of 8.9 ± 6.86 days. During this period 8 of 20 (40%) foals developed complications such as diarrhea (n=3), abscessation over the septic focus (n=4), and septic joint (n=1). In the cases where diarrhea occurred it was suspected to be due to development of antibiotic induced colitis caused by *Clostridium difficile* infection and the foals were taken off the treatment until the diarrhea abated and treatment was continued.

4.5 Treatment

Eight of the twenty foals (40%) responded well to their first antibiotic combination while the remaining 12 (60%) were changed to a new combination. Figure 2. shows the percentage of foals receiving the different antibiotics as first and second choice.

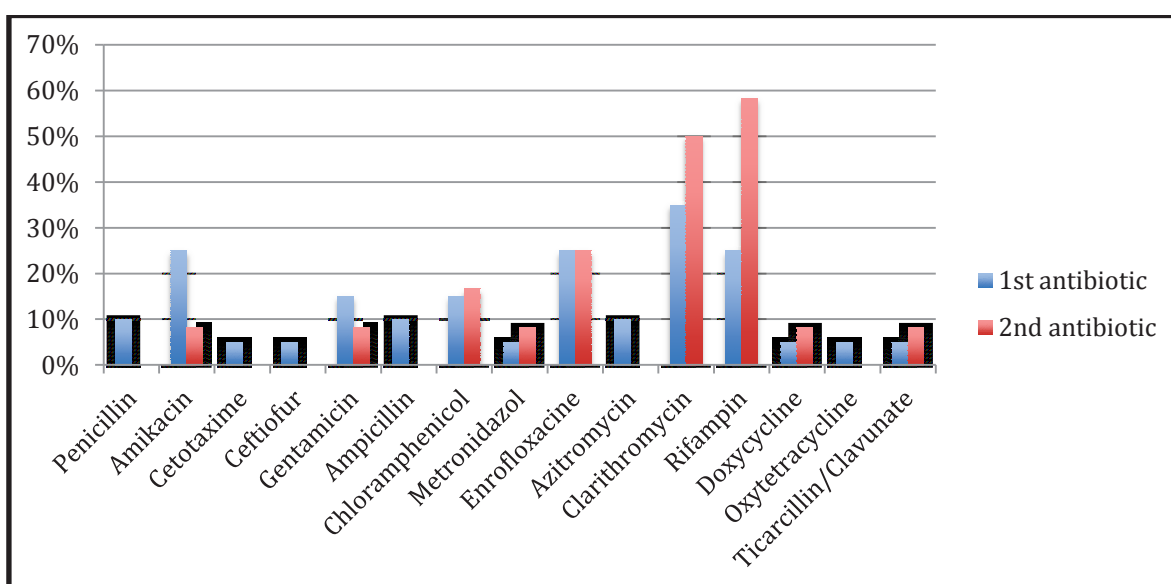


Figure 2 Antibiotic used as first and second choice.

The length of systemic antibiotics varied in the different cases, foals were kept on intravenous or intramuscular antibiotics then changed over to oral antibiotics until they were clinically sound, and the radiographs were showed eradication of the infection. The mean of antibiotic use was 26.25 ± 13.75 days, median of 26 days, ranged from 8-70 days. The length of hospitalization, antibiotic treatment, oral and peroral antibiotic treatment is presented in Table 6.

Foal	Length of hospitalization	Length of antibiotic treatment	Length of oral antibiotic treatment	Length of parenteral antibiotic treatment
1	0	31	31	0
2	18	31	31	6
3	6	24	24	0
4	10	8	8	0
5	20	30	30	20
6	20	14	9	14
7	4	18	16	9
8	2	12	0	12
9	11	26	26	0
10	12	26	14	12
11	0	32	32	32
12	0	70	70	4
13	11	23	23	8
14	17	42	42	16
15	12	26	9	17
16	15	29	29	7
17	9	14	13	10
18	8	14	14	10
19	0	41	41	0
20	3	34	34	17

Table 6 Length of hospitalization and antibiotic treatment.

4.6 Additional therapies

In addition to systemic antibiotics the foals received different anti-inflammatory, analgesic and supportive therapy (see Figure 4). Hyperbaric treatments were given in 13/20 (65%) cases and the average numbers of treatments were 11.75 ± 3.19 ranging from 7-15 treatments. In four foals intralesional treatment was also preformed, 3 of 4 (75%) were injected with amikacin and one foal (25%) with imipenem.

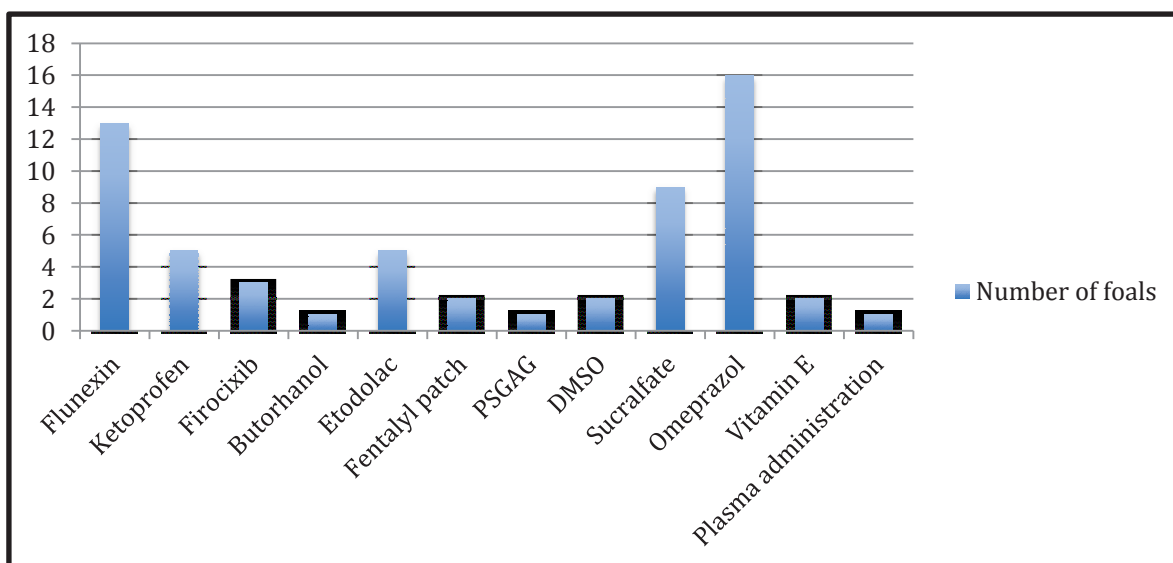


Figure 3 Supportive therapy

4.7 Outcome

Eighteen of the 20 (90%) foals survived to be discharged, out of the two that died one had the septic focus in the scapula and was euthanized due to poor prognosis. The other foal was also euthanized due to poor prognosis and necropsy revealed severe osteomyelitis in the L5 vertebrae. The survival rate in this study was significantly higher ($p=0.047$) compared to the survival in two other studies (Neil et al., 2010 and Steel et al., 1999). See Table 7

Parameters	Current study	Neil et al., 2010	Steel et al., 1999	P-value
Foal survived	18/20	87/108	73/93	0.047
Horses raced	7/12	52/108	18/62	0.201

Table 7 Outcome

Long-term follow up was available in 12 cases. One foal had died for unknown reasons, 3 foals were registered but not raced, 7 out of the 12 (58%) foals ended up racing or going into training for racing. One foal was a yearling at the time of this study and was sold on the yearling sale 2015. See Table 8.

Parameters	Number of foals	Mean±SD	Median (Min/max)
Number of starts	12	4.6±5.2	3(0-16)
Number of wins	12	0.7±0.95	0.5(0-3)
Number of 2nds	12	0.6±0.97	0(0-3)
Number of 3rds	12	0.3±0.67	0(0-2)
Earnings	12	22275±43895	7762(0-143774)

Table 8 Race starts and wins

5. Discussion

In this retrospective case study we found that the survival rate was 90%, the most common bacteria found was *Rhodococcus equi*, the most commonly affected site were the vertebrae. The most common clinicopathologic findings were hyperfibrinogenemia and leukocytosis, the most common antibacterial use was Clarithromycin and the most common additional treatment was hyperbaric pressure oxygen therapy.

Rhodococcus equi is reported in certain case studies (Morresey et al., 2010; Reuss et al., 2009), while in retrospective works concerning septic arthritis or osteomyelitis, other bacteria are more frequently isolated (Steel et al., 1999; Neil et al. 2010). In our study we found a significantly ($p < 0.001$) higher number of *Rhodococcus equi* isolates in comparison to previously published studies (Neil et al., 2010; Steel et al., 1999). Though, it should be taken into consideration that those studies involved osteomyelitis with concurrent infection of synovial structure and the focus of our study was osteomyelitis without concurrent septic synovitis. It is also possible that the prevalence of *Rhodococcus equi* has increased in the recent years and the regions, where the other studies were conducted do not encounter the threatening appearance of extrapulmonary *Rhodococcus equi*. The low incidence of *Alfa hemolyzing Streptococcus*, *Beta hemolyzing Streptococcus*, and *Staphylococcus* was in agreement with the previous studies. Interestingly, none of the cases had evidence of salmonellosis despite that fecal cultures are part of the routine diagnostic work-up in foals presenting with signs of sepsis to Hagyard Equine Medical Institute. In addition to the lack of salmonella isolates, none of the other commonly reported pathogens in septic arthritis/ osteomyelitis (*Enterobacteria*, *E.coli*) (Steel et al., 1999; Smith et al., 2004) were detected in this study population. An explanation to this could be the exclusion of cases with concurrent infected synovial membranes.

Only five of the foals that had lesional cultures taken had concurrent blood cultures taken. Since organisms both from blood and affected sites are challenging to isolate (Marsh and Palmer, 2001; Neil et al., 2010; Steel et al., 1999), it is recommended to attempt both methods in order to obtain more data. The largest age group of foals in this study was between 1 and 3 months old when they presented to the hospital. This seems to be within the age group reported in previous publications.

Even though osteomyelitis is considered as one of the least common extrapulmonary disorders associated with *Rhodococcus equi*, it might be one of the most severe and career threatening ones (Reuss et al., 2009). It is important to note that extrapulmonary disorders often can occur without concurrent sign of pneumonia. This highlights the importance of screening for extrapulmonary *Rhodococcus equi* manifestations in farms endemic for *Rhodococcus equi* (Reuss et al., 2009).

Among clinicopathologic data, leukocytosis was only present in about half of the cases, which is in agreement with anecdotal veterinary reports about insensitivity of blood work in cases of septic osteomyelitis or septic arthritis. The latter of which highlights the importance of joint fluid analysis and further diagnostic work-up.

Hyperfibrinogenemia was the leading clinicopathologic alteration. Newquist and Baxter (2009) suggested in their study that plasma fibrinogen concentration above 900g/dL could be an indicator of physeal and epiphyseal osteomyelitis. Nevertheless, only one third of the foals presented with hyperfibrinogenemia had plasma fibrinogen concentration above 900g/dL during hospitalization. This might be due to regional differences and early recognition of these cases due to more advanced surveillance at the Kentucky breeding operations.

Radiological lesions were found in 75% of the foals in this study, the other foals were diagnosed with ultrasound and scintigraphy. Digital radiography may be insensitive and limited to be the gold standard diagnostic tool, as part of the spinal column and the proximal limbs cannot be adequately imaged with this technique. In addition radiographic lesions may not be noted until 50-70% demineralization of bone has occurred (Goodrich, 2006). Our result suggests that ultrasonography can be a great supplement for diagnostics as suggested by Neil et al., (2010), for instance in cases where septic focus is situated in the scapula, femur or vertebrae.

The septic focus was spread all over the body, the most commonly affected part of the body was the vertebral column, 50% of the foals had lesions in one or more vertebrae. No other case series are published on osteomyelitis without concurrent septic synovitis, which makes this finding difficult to compare. Several cases have been reported on osteomyelitis

in the vertebrae not only *Rhodococcus equi*, but also *Salmonella* has been isolated (Crabtree and Jorgensen, 2012; Roberts et al., 2010). Reuss et al. (2009) reported that 2 % of extrapulmonary lesions in foals due to *Rhodococcus equi* were found in form of osteomyelitis in the spines.

All foals were treated with systemic antibiotics either parenterally or orally. It was the attending clinician's discretion based on signalment, clinical signs and clinicopathologic data, what type of antibiotic was primarily selected. Thus, no common antibiotic combination can be recommended based on this study. Prior to antimicrobial results a combination of B-lactames and aminoglycosides are proposed to be the most common choices (Goodrich and Nixon, 2004), despite poor penetration properties into lesions. As osteomyelitis was commonly thought to be caused by *Rhodococcus equi*, clarithromycin was the most common antibiotic used (35%), followed by amikacin, rifampin and enrofloxacin (25% each). Clarithromycin does not seem to be common in previous studies including septic arthritis/ osteomyelitis (Steel et al., 1999; Neil et al, 2010) nor in studies done on bacteremia in foals (Sanchez et al., 2008). This is explained by the low number of *Rhodococcus equi* isolates in previously published studies in comparison to what was isolated in this study. Revision of the antibiotic therapy was based upon lack of clinical response or obtained microbiological information. All cases in this study exhibited favorable response to either the initial or the revised antibiotic therapy. The results in this study suggest that a wide variety of antibiotics might be used successfully in cases of osteomyelitis, but as mentioned in other cases, a change of antibiotic is indicated when no or inadequate clinical improvement is seen in 3-5 days following initiation of treatment (Close et al., 2010).

Today surgical debridement of the site of osteomyelitis is recommended as a part of the treatment plan (Goodrich and Nixon, 2004; Koch and Witte, 2012). Due to difficulties of approaching the lesion site in many of the cases in the current study, surgical debridement was not performed and the result from the current study indicates that osteomyelitis can be well managed with systemic antibiotics alone.

Length of systemic antibiotic treatment had a mean duration of 26 days and ranged from 8-70 days. Due to inadequate follow up records, the complete length of antibiotic therapy in some cases was not obtainable. It is therefore a possibility that the mean of duration was

even longer in some cases. Nevertheless, the duration in this study is already longer than in previously published studies (Neil et al. 2010; Close et al., 2010).

Prolonged therapy in the current study may be due to the exclusion of septic arthritis cases, in which joint treatment and joint lavage can be performed, which can shorten the length of systemic antibiotic therapy.

Contrary to previously published studies, foals were treated with hyperbaric oxygen therapy as an additional treatment. Hyperbaric oxygen therapy is used to increase the amount of molecular oxygen solved in the plasma, which may contribute to improved tissue oxygenation, improved oxidative burst and faster recovery (Slovic, 2008). In the current study 13/20 foals received hyperbaric oxygen therapy ranging from 7-15 treatments, which in addition to other management and treatment strategies may have contributed to a significantly improved survival rate. Based on our findings and previous survival data, hyperbaric therapy could be the primary factor of the better short and long-term success rate.

Ninety percent of the cases survived to discharge, the remaining 10% were euthanized due to poor prognosis. These numbers are significantly higher than in previous studies (Neil et al., 2010; Steel et al., 1999). It should be additionally taken in to consideration that e-type osteomyelitis cases evaluated in this study are considered more difficult to treat than s-type cases investigated in previous studies (Neil et al., 2010, Steel et al., 1999).

The long-term outcome was known in 14 cases, and additional two foals were yearlings at the stage of the data collection. One of these foals was euthanized due to poor prognosis while the other one was sold at the yearling sale in 2015. Fifty percent of foals went into racing, training for racing or sales; this proportion is similar to previously published studies (Neil et al., 2010; Steel et al., 1999).

In summary, this study showed that *Rhodococcus equi* is a common isolate in cases of osteomyelitis without concurrent synovitis. The survival rate was higher than in previously published studies and the most common site of infection was the vertebrae. The prognosis of osteomyelitis should be considered good with early and aggressive treatment.

Despite the 10 year long record searching in one of the highest case load hospital of the world, further data expansion using multi-center design would be necessary to establish a more optimal scientific basis for generalized conclusion of septic e-type osteomyelitis in foals without concurrent synovial involvement.

6. Acknowledgments

This thesis work has been extremely interesting and rewarding. First I would like to thank my supervisor Dr. Balázs Tóth for his expert guidance and thoughts on my work. Secondly I would like to thank Dr. Nathan M. Slovis and Lindsay Kenyon at Hagyard Equine Medical Institute for letting me use the Hagyard records and helping me during my data collection. Lastly I would like to thank my family for their advice and support during this period.

7. References

- Baird, A., Taylor, J. and Watkins, J. (1990). Debridement of septic physical lesions in 3 foals. *Cornell vet*, 80, pp.85-95.
- Balwin, J., Cooper, W., Vanderwall, D. and Erb, H. (1991). Prevalence (treatment days) and severity of illness in hypogammaglobulinemic and normogammaglobulinemic foals. *Journal of the American Veterinary Medical Association (JAVMA)*, 198, pp.423-428.
- Close, K., Gerard, M., Davidson, G. and Schramme, M. (2010). Successful treatment of infectious (Salmonella type III: 44) polyarthritis and osteomyelitis in a 4-week-old foal. *Equine Veterinary Education*, 23(3), pp.121-126.
- Crabtree, J. and Jorgensen, A. (2012). Cervical Vertebral Osteomyelitis With Secondary Septic Arthritis of the Atlantoaxial Joint in a Foal: A Case Report. *Journal of Equine Veterinary Science*, 32(9), pp.599-606.
- FIRTH, E. (1983). Current concepts of infectious polyarthritis in foals. *Equine Veterinary Journal*, 15(1), pp.5-9.
- Firth, E. and Goedegebuure, S. (1988). The site of focal osteomyelitis lesions in foals. *Veterinary Quarterly*, 10(2), pp.99-108.
- Firth, E. and Poulos, P. (1982). Blood vessels in the developing growth plate of the equine distal radius and metacarpus. *Research in Veterinary Science*, 33, pp.159-166.
- Firth, E. and Poulos, P. (1987). Development of the epiphysis, metaphysics and diaphysis in the foal. *Proc am Assoc Equine Pract*, 33, pp.787-794.
- FIRTH, E., ALLEY, M. and HODGE, H. (1993). Rhodococcus equi-associated osteomyelitis in foals. *Australian Veterinary Journal*, 70(8), pp.304-307.
- Firth, E., Dik, K., Goedegebuure, S., Hagens, F., Verberne, L., Merkens, H. and Kersjes, A. (1980). Polyarthritis and Bone Infection in Foals. *Zentralblatt für Veterinärmedizin Reihe B*, 27(2), pp.102-124.
- Goodrich, L. (2006). Osteomyelitis in Horses. *Veterinary Clinics of North America: Equine Practice*, 22(2), pp.389-417.
- Goodrich, L. and Nixon, A. (2004). Treatment options for osteomyelitis. *Equine Veterinary Education*, 16(5), pp.267-280.
- Hardy, J. (2006). Etiology, Diagnosis, and Treatment of Septic Arthritis, Osteitis, and Osteomyelitis in Foals. *Clinical Techniques in Equine Practice*, 5(4), pp.309-317.
- Hepworth-Warren, K., Wong, D., Fulkerson, C., Wang, C. and Sun, Y. (2015). Bacterial isolates, antimicrobial susceptibility patterns, and factors associated with infection and outcome in foals with septic arthritis: 83 cases (1998–2013). *Journal of the*

American Veterinary Medical Association, 246(7), pp.785-793.

- Kay, A., Hunt, R., Rodgerson, D., Spirito, M., Santschi, E. and Payne, R. (2012). Osteomyelitis of the Patella in Eight Foals. *Veterinary Surgery*, p.n/a-n/a.
- Kelleher, M. and MacDonald, D. (2007). Cortical Osteitis of The Humeral Diaphysis Caused by *Rhodococcus Equi*. *Journal of Equine Veterinary Science*, 27(7), pp.317-319.
- Koch, C. and Witte, S. (2012). Septic osteitis and osteomyelitis in foals - are antimicrobials alone enough?. *Equine Veterinary Education*, 25(2), pp.67-73.
- Lawrence, C. and Fraser, B. (2012). Septic osteitis of the axial border of the proximal sesamoid bones in two foals. *Equine Veterinary Education*, 25(2), pp.63-66.
- Lew, D. and Waldvogel, F. (2004). Osteomyelitis. *The Lancet*, 364(9431), pp.369-379.
- Marsh, P. and Palmer, J. (2001). Bacterial isolates from blood and their susceptibility patterns in critically ill foals: 543 cases (1991-1998). *Journal of the American Veterinary Medical Association*, 218(10), pp.1608-1610.
- Morresey, P., Garrett, K. and Carter, D. (2010). *Rhodococcus equi* occipital bone osteomyelitis, septic arthritis and meningitis in a neurological foal. *Equine Veterinary Education*, 23(8), pp.398-402.
- Neil, K., Axon, J., Begg, A., Todhunter, P., Adams, P., Fine, A., Caron, J. and Adkins, A. (2010). Retrospective study of 108 foals with septic osteomyelitis. *Australian Veterinary Journal*, 88(1-2), pp.4-12.
- Neil, K., Charman, R. and Vasey, J. (2010). Rib osteomyelitis in three foals. *Australian Veterinary Journal*, 88(3), pp.96-100.
- Newquist, J. and Baxter, G. (2009). Evaluation of plasma fibrinogen concentration as an indicator of physeal or epiphyseal osteomyelitis in foals: 17 cases (2002–2007). *Journal of the American Veterinary Medical Association*, 235(4), pp.415-419.
- Paradis, M. (1994). Update on neonatal septicaemia. *Veterinary Clinics of North America: Equine practice*, 10, pp.109-134.
- Reuss, S., Chaffin, M. and Cohen, N. (2009). Extrapulmonary disorders associated with *Rhodococcus equi* infection in foals: 150 cases (1987–2007). *Journal of the American Veterinary Medical Association*, 235(7), pp.855-863.
- Richardson, D. and Ahern, B. (2012). Synovial and Osseous Infections. In: J. Auer and J. Stick, ed., *Equine Surgery*, 4th ed. St. Louse, Missouri: Elsevier, Saunders, pp.1189-1201.
- Roberts, B., Reimer, J., Woodie, J. and Reed, S. (2010). Septic arthritis of the first and second cervical vertebral articulations with vertebral osteomyelitis in a foal caused by *Salmonella*. *Equine Veterinary Education*, 22(7), pp.328-333.

- Ross, M. and Dyson, S. (2011). *Diagnosis and management of lameness in the horse*. St. Louis, Mo.: Elsevier/Saunders.
- Sanchez, L. (2005). Equine Neonatal Sepsis. *Veterinary Clinics of North America: Equine Practice*, 21(2), pp.273-293.
- Sanchez, L., Giguère, S. and Lester, G. (2008). Factors associated with survival of neonatal foals with bacteremia and racing performance of surviving Thoroughbreds: 423 cases (1982–2007). *Journal of the American Veterinary Medical Association*, 233(9), pp.1446-1452.
- Slovits, N. (2008). Review of Equine Hyperbaric Medicine. *Journal of Equine Veterinary Science*, 28(12), pp.760-767.
- SMITH, L., MARR, C., PAYNE, R., STONEHAM, S. and REID, S. (2004). What is the likelihood that Thoroughbred foals treated for septic arthritis will race?. *Equine Veterinary Journal*, 36(5), pp.452-456.
- Steel, C., Hunt, A. and Adams, P. (1999). Factors associated with prognosis for survival and athletic use in foals with septic arthritis; 93 cases (1987-1994). *Journal of the American Veterinary Medical Association*, 215, pp.973-977.
- Stewart, A., Hinchcliff, K., Saville, W., Jose-Cunilleras, E., Hardy, J., Kohn, C., Reed, S. and Kowalski, J. (2002). Actinobacillus sp. Bacteremia in Foals: Clinical Signs and Prognosis. *J Vet Int Med*, 16(4), p.464.
- Stoneham, S. (1997). Septic arthritis in the foal: practical considerations on diagnosis and treatment. *Equine Veterinary Education*, 9(1), pp.25-29.
- TAYLOR, A., MAIR, T., SMITH, L. and PERKINS, J. (2010). Bacterial culture of septic synovial structures of horses: Does a positive bacterial culture influence prognosis?. *Equine Veterinary Journal*, 42(3), pp.213-218.
- Trumble, T. (2005). Orthopedic Disorders in neonatal foals. *Veterinary clinics equine practice*, 21, pp.357-385.
- Vos, N. and Ducharme, N. (2008). Analysis of factors influencing prognosis in foals with septic arthritis. *irvetj*, 61(2), p.102.
- Wilson, W. and Madigan, J. (1989). Comparison of bacteriologic culture of blood and necropsy specimens for determining the cause of foal septicemia: 47 cases (1978–1987). *Journal of the American Veterinary medicine Association*, 195, pp.1759–1763.