

Department and Clinic of Equine Medicine,
Faculty of Veterinary Science, Szent István University, Budapest

CASTRATION OF THE STALLION
(Equisurf – Mediawork)

Luzia Carla Klauser

Supervisor:
Dr. Gábor Bodó PhD, Dipl. ECVS

Budapest

2014

Table of contents

1. Introduction	4
2. Pre-operative considerations	6
2.1 Clinical history and anamnesis	6
2.2 Clinical examination	6
2.3 Pre-operative medication	7
2.4 Self-evaluating questions	7
3. Embryonic development of the gonads	8
3.1 Self-evaluating questions	9
4. Anatomy and Physiology of the gonads	10
4.1 Scrotum	10
4.2 Tunics	11
4.3 Cremaster muscle	11
4.4 Testis	12
4.5 Epididymis	12
4.6 Inguinal Canal	13
4.7 Gubernaculum	13
4.8 Spermatic cord	14
4.9 Self-evaluating questions	14
5. Surgical Instruments	16
5.1 Emasculators	16
5.2 Self-evaluating questions	18
6. Positioning of the patient	19
6.1 Standing castration	19
6.2 Recumbent castration	20
6.3 Self-evaluating questions	21
7. Surgical techniques for the castration of normal horses	22
7.1 Open technique	22
7.2 Closed technique	22
7.3 Semi-closed technique	22
7.4 Advantages and disadvantages of described techniques	23
7.5 Removal of the testes	23
7.6 Skin closure	24
7.7 Self-evaluating questions	24
8. Surgical approach	26
8.1 Scrotal approach	26
8.2 Inguinal approach with primary wound closure (Swiss technique)	26
8.3 Laparoscopic intra-abdominal ligation of spermatic cord	28
8.4 Vasectomy	29
8.5 Immunologic castration	30
8.6 Self-evaluating questions	30
9. Monorchidism and Cryptorchidism	32
9.1 Monorchidism	32
9.2 Cryptorchidism	32

9.3 Self-evaluating questions	33
10. Surgical approaches for cryptorchid stallions	35
10.1 Inguinal approach	35
10.2 Parainguinal approach	36
10.3 Suprapubic paramedian approach	36
10.4 Flank approach	37
10.5 Laparoscopic method	37
10.5.1 Standing laparoscopic cryptorchidectomy	38
10.5.2 Recumbent laparoscopic cryptorchidectomy	38
10.6 Self-evaluating questions	39
11. Post-operative recommendations	40
11.1 Post-operative medication	40
11.2 Self-evaluating questions	41
12. Complications	42
12.1 Postoperative swelling and oedema	43
12.2 Haemorrhages	44
12.3 Evisceration	45
12.4 Protrusion of omentum	46
12.5 Septic funiculitis	47
12.6 Clostridial infection of the castration wound	47
12.7 Septic peritonitis	48
12.8 Penile damage	48
12.9 Hydrocele	49
12.10 Continued masculine behaviour	49
12.11 Respiratory infection	50
12.12 Self-evaluating questions	50
13. Conclusion	52
14. Acknowledgements	53
15. References	54
15.1 Literature references	54
15.2 Figure references	57

1. Introduction

Castration of the stallion is one of the most frequently performed surgical procedures in equine practice (Schumacher 1996). Indications for castration are to exclude horses unsuited for the genetic pool from breeding, to eliminate masculine and aggressive behaviour, and to treat testicular trauma, neoplasia and inguinal herniation (Shoemaker, et al. 2004). Open, closed and semi-closed techniques are available for castration of horses and, depending on the circumstances, the procedure may be performed in a standing and sedated animal or recumbent under general anaesthesia (Searle, et al. 1999). Most horses are castrated between 1 to 2 years of age before the onset of strong masculine behaviour (Schumacher 2006).

To deliver the best results possible and to prevent complications regarding this surgical procedure, a profound knowledge of the embryonic development, anatomy and physiology of the male reproductive organ is crucial. Several surgical methods and associated advantages and disadvantages have been described. Although surgical castration of the horse is considered a routine procedure, complications arise frequently and lead to the most common malpractice claims against equine practitioners in North America (Wilson and Quist 1992).

Castration of stallions is considered a routine procedure commonly performed by first-line veterinarians. Therefore, a professional education on the various aspects of castration, including the anatomy, surgical procedures, and associated complications, can be considered highly important. The recent development of computational technology is known to have significant potential to facilitate learning of students. At the University of Bern, an e-learning program designed to educate veterinary students on the various aspects of equine internal medicine and surgery has recently been developed. However, an interactive learning system, specifically designed to teach veterinary students the various aspects associated with performing surgical castration of the stallion, is lacking.

Therefore, the aims of this thesis were 1) to write a chapter about equine castration, which is to be added to the already existing e-learning program “equisurf” in Bern, in German language; 2) to write the first chapter of an e-learning program for the Szent István

University, in English language. The different chapters of this Doctoral Thesis will cover all the steps of a castration, involving the anamnesis and clinical history, embryologic development, important anatomical structures, surgical procedures, and associated complications and are illustrated with pictures, schematic drawings and videos.

With the help of this media work, students will be able to study the different castration techniques and associated complications online. Each chapter is followed by some self-evaluating questions to give the students an immediate feedback on their acquired knowledge, with the aim of improving the current curriculum for veterinary students of our faculty.

This thesis is a collaboration between the Vetsuisse Faculty ISME Pferdeklinik in Bern, Switzerland and the Szent István University, Faculty of Veterinary Science in Budapest, Hungary.

2. Pre-operative considerations

2.1 Clinical history and anamnesis

The first step of every veterinary procedure involves a conversation with the owner. In case of castration of the horse, the owner should be clearly informed about the different surgical methods available, and their possible complications. A general anamnesis has to be taken before the surgery to detect co-morbidities. Questions of anamneses include: Have there been any previous surgeries or anaesthesia? Is the horse under current medication? What age and breed is the stallion?

Make sure the vaccination protocol is up to date; especially the tetanus prophylaxis should be current (Searle, et al. 1999). If the horse has not been vaccinated in the previous 6 months, a tetanus toxoid booster should be administered preoperatively (Kilcoyne 2013). If the vaccination status is unknown, then tetanus antitoxin should be administered in addition to a tetanus toxoid (Kilcoyne 2013).

2.2 Clinical examination



Figure 1: General physical examination

Castration is an elective procedure and should only be performed after a thorough examination of the patient. A general physical examination is performed, involving the assessment of body temperature, respiratory system and circulatory system (Figure 1) with the aim of evaluating the patient's general health status. External examination of the reproductive tract consists of palpation of the testicles and the scrotum. The presence of both testicles and absence of herniation are investigated. Sedation of the horse may be required to inspect the inguinal area in case of a fractious stallion. Cryptorchidism or inguinal herniation changes the anaesthesia protocol and castration method applied, and

therefore these conditions should be recognised prior to surgery, (Schumacher 2006), (Mair, et al. 2013). Occasionally an inguinal testicle that was not palpable without sedation becomes palpable in the anaesthetized horse (Moll, Pelzer und Pleasant 1995).

2.3 Pre-operative medication

The use of antibiotics prior to surgery is debatable and generally based on the preference of the clinician. Some veterinarians administer procaine penicillin before surgery depending on adverse weather conditions or unhygienic conditions in the field (Kilcoyne 2013). The pre-operative use of non-steroidal anti-inflammatories, like phenylbutazone or flunixin meglumine can be recommended in some cases (Kilcoyne 2013).

2.4 Self-evaluating questions

1. What are important questions when taking the history?
 - a. Does your horse have any other illnesses?
 - b. Did it have a congenital hernia?
 - c. Is the horse under current medication?
 - d. All of the above

2. What vaccination is necessary prior to castration?
 - a. Rabies
 - b. Equine Influenza
 - c. Tetanus
 - d. West Nile

3. What drugs are appropriate prior to surgical castration?
 - a. Flunixin-meglumine
 - b. Phenylbutazone
 - c. Penicillin procaine
 - d. Dexamethasone

3. Embryonic development of the gonads

The embryonic gonad differentiates into a testis about 5.5 weeks after the onset of gestation, when it lies on the ventral aspect of the mesonephric kidney. A retroperitoneal cord of mesenchyme crosses the abdominal cavity from the caudal pole of the testis towards the site of the future scrotum, which forms into the gubernaculum (Smith 1975). At around 6 weeks of gestation, the interstitial cells of the testis begin to multiply (Figure 2). At 5 months of gestation, the testes reach a size as found in a mature stallion. It lies in close contact with the internal inguinal ring and the kidney at this time (Schumacher 1992). Between 7 and 10 months of gestation, the gubernaculum shortens and the testicle atrophies again to one tenth of its former size, followed by an expansion of the epididymis and the ligamentum caudae epididymis, to dilate the vaginal ring and inguinal canal (Smith 1975). The dilation of the inguinal ring, contraction of the gubernaculum and increase in intra-abdominal pressure force the testicle into the inguinal ring (Schumacher 1992). The colt is born with the testes within the inguinal canal, because the volume of extra-abdominal gubernaculum prevents the testis from completely descending into the scrotum. The gubernacular tissue reduces continuously during the first few weeks of life, allowing the testicle to descend further into the scrotum (Smith 1975).

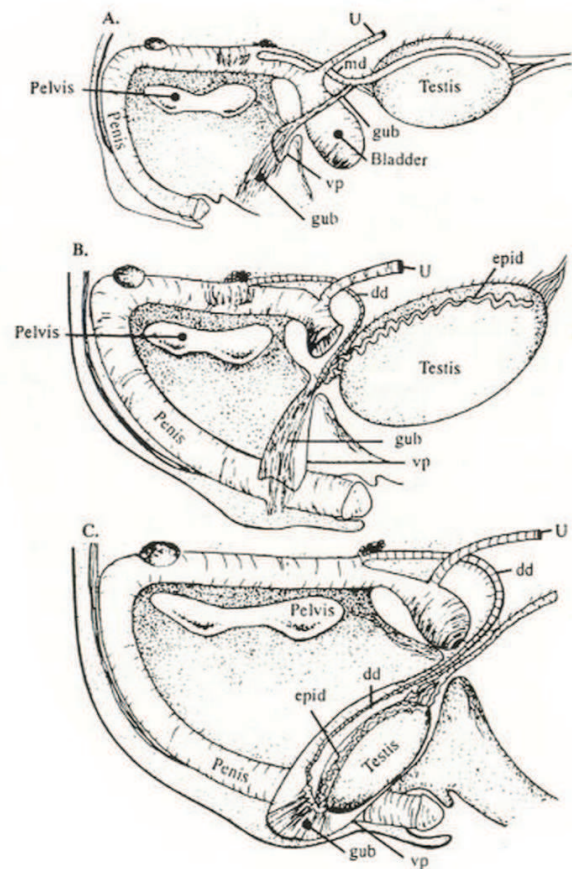


Figure 2: Testicular descent into the scrotum of the horse foetus

A: Foetus at 75 days of gestation

B: Foetus at 175 days of gestation

C: Foetus near term at 330 days of gestation

3.1 Self-evaluating questions

4. Where is the embryonic gonad found?
 - a. In close proximity to the liver
 - b. On the ventral aspect of the mesonephric kidney
 - c. Right cranial to the pelvis
 - d. Dorsal to the bladder

5. Which structures are important for testicular descent?
 - a. The testicle
 - b. The gubernaculum
 - c. The epididymis
 - d. The plexus pampiniformis

6. In which position are the testicles found right after birth?
 - a. In the abdomen
 - b. In the scrotum
 - c. In the inguinal canal
 - d. On the ventral aspect of the mesonephric kidney

4. Anatomy and Physiology of the gonads

4.1 Scrotum

The scrotum is a dual-chambered protuberance of skin and muscles. It is composed of the skin, the tunica dartos and the stratum subdartoicum. The skin of the scrotum is thin, only sparsely covered with hair and usually pigmented (Figure 3). The raphe scroti divides both sides and is continuous with the raphe of the prepuce, penis and perineum. The skin contains a high number of sweat glands, which aid in scrotal thermoregulation (Wissdorf, et al. 2002). The tunica dartos closely adheres with the overlying skin, and contains involuntary muscle cells, which relax with heat and contract with cold to regulate the temperature in the testicle (Schumacher 2006). The septum scroti extends from the tunica dartos and divides the scrotum into a right and a left pouch and is recognized externally by the raphe scroti. The tunica dartos is lined by the stratum subdartoicum and a double lined fascia spermatica externa, which is a separation of the fascia trunci profundi (Wissdorf, et al. 2002). The vascular supply to the scrotum originates from the arteria pudenda externa. The nerves of the scrotum extend from the nervus genitofemoralis. Lymphatic drainage is accomplished by the superficial inguinal lymph nodes (Schumacher 2006).

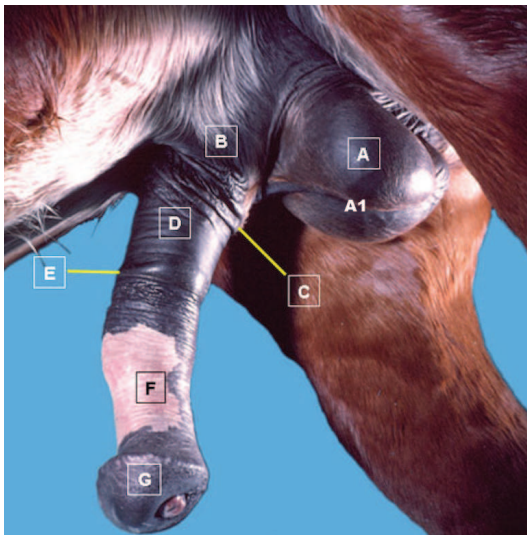


Figure 3: Male sexual organs

- A: Scrotum
- A1: Raphe scroti
- B: Prepuce,
- C: Preputial orifice
- D: Preputial fold
- E: Preputial ring
- F: Free part of penis
- G: Glans

4.2 Tunics

The tunica vaginalis is an extension of the abdominal peritoneum (Figure 4) and lines the inguinal canal and the scrotum. It consists of a visceral and a parietal tunic. The visceral tunic is tightly adhered to the tunica albuginea of the testicle and the parietal tunic is continuous with the parietal peritoneum and forms a sac that is referred to as the vaginal process (Nickel, Schummer und Seiferle 1979).

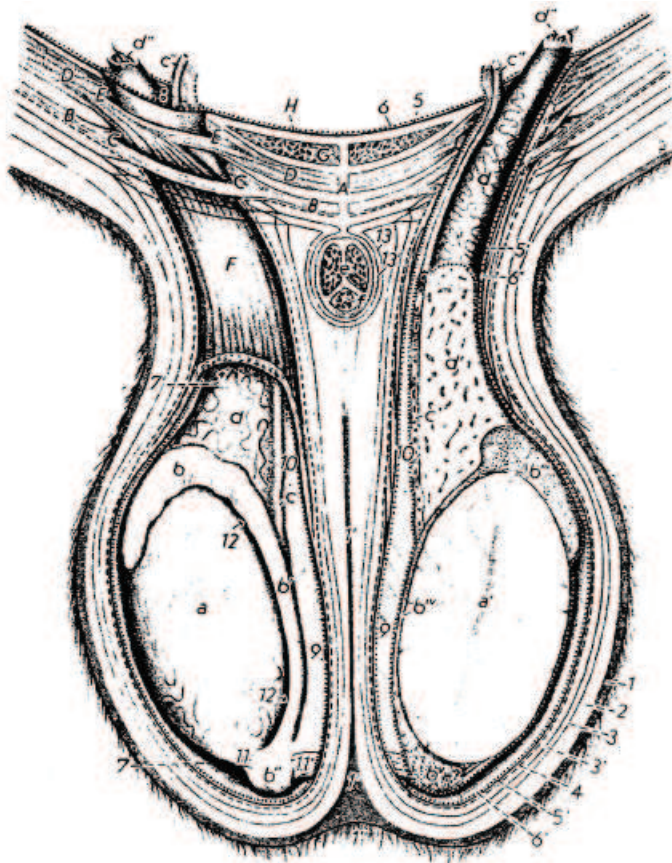


Figure 4: Tunics

- 1: Skin and tunica dartos
- 1': Scrotal septum
- 1'': Scrotal raphe
- 2: Loose subdartoic tissue
- 3, 3': External spermatic fascia
- 4: Cremasteric fascia
- 5: Transverse fascia
- 5': Internal spermatic fascia
- 6: Parietal peritoneum
- 6': Tunica vaginalis parietalis
- 7, 7': Vaginal cavity
- 8: Vaginal ring
- 9: Mesorchium
- 10: Mesofuniculum
- 11: Proper ligament of testis
- 11': Ligament of tail of epididymis
- 12: Testicular bursa

4.3 Cremaster muscle

The cremaster muscle is an extension of the internal abdominal oblique muscle and the transverse abdominal muscle (Figure 5). The cremaster muscle inserts laterally and caudally into the vaginal process and is covered by the fascia cremasterica. It can contract quickly and elevates the vaginal process with its contents into the inguinal region, which plays an important role in thermoregulation (Wissdorf, et al. 2002).

4.4 Testis

The functions of the testicles are to produce spermatozoa and hormones, which control spermatogenesis, sexual differentiation, sexual characteristics and libido. Usually the left testicle (Figure 5) is larger, suspended more ventrally and lies further caudally than the right testicle. Both testicles lie in the scrotum with their axis nearly horizontal with the epididymis attached to the dorsolateral border (Schumacher 2006).

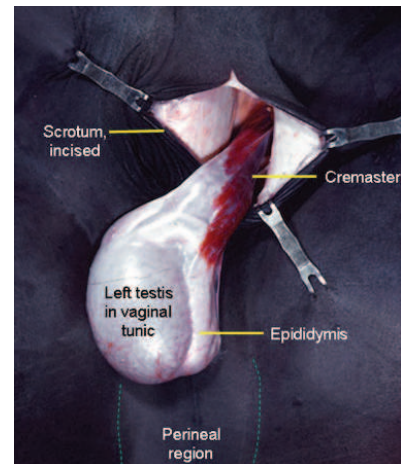


Figure 5: Testis and cremaster muscle

4.5 Epididymis

The epididymis is formed by the numerous convolutions of the single epididymal duct within a connective tissue matrix and appears spongy in section due to the coiled duct (Dyce, Sack und Wensing 2002).

The epididymis consists of three parts: the head (caput), the body (corpus) and the tail (cauda) (Figure 6) and is attached by the ligamentum testis proprium to the caudal aspect of the testicles. The spermatozoa are stored in the epididymis until ejaculation and undergo maturation during this time (Nickel, Schummer und Seiferle 1979).

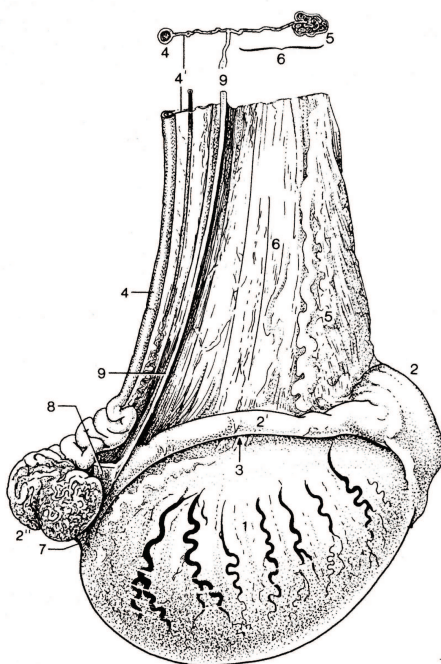


Figure 6: Lateral view of the right testis of a stallion

- 1: Testis
- 2: Head of epididymis
- 2': Body of epididymis
- 2'': Tail of epididymis
- 3: Testicular bursa
- 4: Deferent duct
- 5: Plexus pampiniformis
- 6: Mesorchium
- 7: Proper ligament of testis
- 8: Ligament of tail of epididymis

4.6 Inguinal Canal

The inguinal canal is formed by the internal inguinal ring and by the external inguinal ring (Figure 7). It serves as a canal for the ductus deferens, testicular nerves and the testicular artery and veins, which form the pampiniform plexus (Dyce, Sack und Wensing 2002). The deep inguinal ring is a dilatable opening between the internal abdominal oblique muscle, the rectus abdominis muscle, prepubic tendon and inguinal ligament. The superficial inguinal ring is a slit in the external abdominal oblique muscle (Searle, et al. 1999). The peritoneum lines the wall of the inguinal canal and forms the tunica vaginalis (Schumacher 2006).

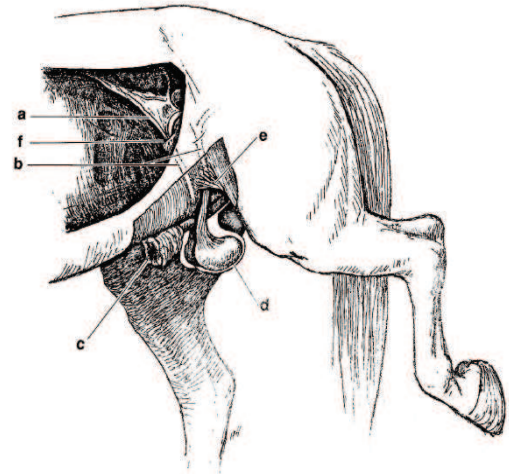


Figure 7: Genital organs

- a: Testicular artery and vein
- b: Spermatic cords
- c: External lamina of the prepuce
- d: Testis within scrotum
- e: External inguinal ring
- f: Internal inguinal ring

4.7 Gubernaculum

The gubernaculum testis is proximally attached to the caudal pole of the testis and fixes distally to the scrotum. It has a crucial function in the descent of the testis (Figure 8-10) during the embryological development and guides the foetal testis from its original position (ventral to the kidney) into its final destination within the scrotum.

The gubernaculum testis can be divided into three parts (Schumacher 2006):

1. **Proper ligament of the testis** (*Lig. testis proprium*): cranial part; connects the tail of the epididymis to the testicle
2. **Ligament of the tail of the epididymis** (*Lig. caudae epididymis*): middle part; connects the tail of the epididymis to the parietal tunic
3. **Scrotal ligament** (*Lig. scroti*): caudal part; connects the parietal tunic to the bottom of the scrotum

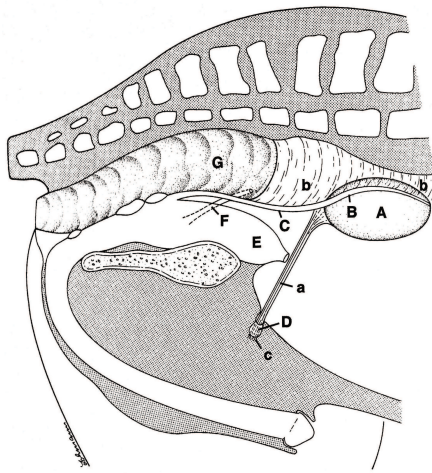


Figure 8: Schematic drawing of the testicular descent; High dorsal position of the testicle

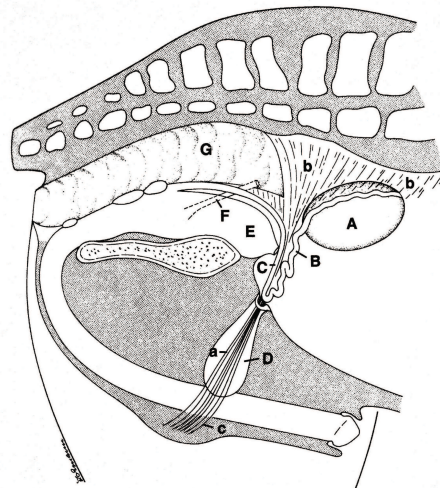


Figure 9: Schematic drawing of the testicular descent; Descent of epididymis and gubernaculum

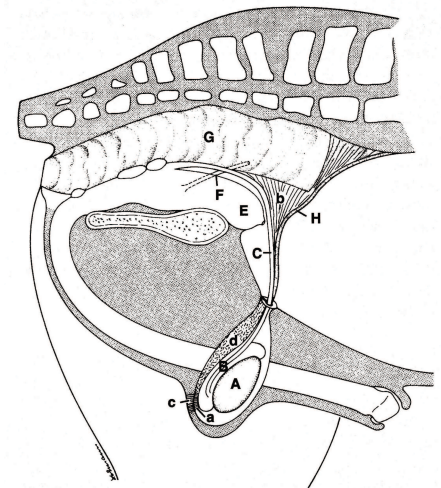


Figure 10: Schematic drawing of the testicular descent; Testicle takes place in scrotum

- A: Testicle
- B,C: Mesonephric duct
- D: Vaginal process
- E: Urachus

- F: Urether
- G: Rectum
- H: Testicular artery
- a: Proper lig. of testis

- b: Mesorchium
- c: Scrotal ligament
- d: Mesofuniculus

4.8 Spermatic cord

The spermatic cord is covered by the visceral part of the vaginal tunic. It is formed by the testicular artery and vein (which form the plexus pampiniformis), lymphatic veins, the testicular plexus of nerves accompanying the vessels, bundles of smooth muscles and the ductus deferens. The plexus pampiniformis functions as a heat exchanger according to the counter flow principle: Venous blood returning from the testicle cools the arriving arterial blood and thus plays an important role in thermoregulation.

The ductus deferens is enclosed in its own serosal fold, the mesoductus (Nickel, Schummer und Seiferle 1979). When castrating, the emasculators, depending on the applied technique, usually crush the whole spermatic cord.

4.9 Self-evaluating questions

7. Which three layers compose the scrotum?
 - a. Tunica dartos
 - b. Skin
 - c. Tunica vaginalis
 - d. Stratum subdartoicum

8. Which structures aid in thermoregulation of the testicle?
 - a. Skin with sweat glands
 - b. Plexus pampiniformis
 - c. Cremaster muscle
 - d. Tunica dartos

9. The tunica vaginalis is an extension of what structure?
 - a. The scrotum
 - b. The tunica albuginea
 - c. The vaginal process
 - d. The abdominal peritoneum

10. What is the function of the cremaster muscle
 - a. Tenses the scrotum
 - b. Helps in the descent of the testis
 - c. Elevates the epididymis
 - d. Elevates the vaginal process

11. What is true for the right testicle?
 - a. It is larger than the left testicle
 - b. It is smaller than the left testicle
 - c. It is suspended more ventrally than the left testicle
 - d. It is suspended more dorsally than the left testicle

12. What part of the gubernaculum attaches the epididymis to the testicle?
 - a. The proper ligament of the testis (Lig. testis proprium)
 - b. The ligament of the tail of the epididymis (Lig. caudae epididymis)
 - c. The scrotal ligament (Lig. scroti)
 - d. None of the above

13. Where are the spermatozoa stored?
 - a. In the epididymis
 - b. In the ductus deferens
 - c. In the testicle
 - d. In the scrotum

14. What structure is not a part of the spermatic cord?
 - a. Tunica vaginalis
 - b. Testicular nerves
 - c. Epididymis
 - d. Mesoductus

5. Surgical Instruments

Castration of the stallion is a surgical procedure requiring a set of fundamental instruments allowing a safe and quick surgical procedure with few complications. However, there is no 'standard' surgical set for castrating horses, since various surgical instruments can be used depending on the applied technique and the positioning of the animal.

In every surgery, the basic instruments include:

- General surgical set containing forceps, haemostats, scissors, needle holder and sterile gauze
- Surgical blade
- Emasculator
- Suture material
- Sterile gloves and drapes
- Ropes for restraint

5.1 Emasculators

Emasculators are tools used to castrate livestock. Various types of emasculators have been described for the castration of the stallion. These include the following:

- **Sand emasculator:** crushing of the spermatic cord and compressing the blood vessels at the same time.



Figure 11: Sand's castration clamp

- **Bertschy's (Serra modified) emasculator with ratchet:** crushing and cutting at the same time. The jaws of the emasculators are curved with blades oriented parallel to the cord, so that the cord is evenly crushed and the chance of accidentally cutting the cord is decreased.

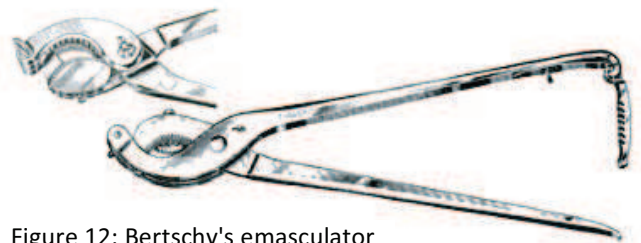

Figure 12: Bertschy's emasculator

- **Reimer emasculator:** crushes the cord and cuts with a blade on a separate handle to avoid cutting before the cord is not satisfactorily crushed.



Figure 13: Reimer emasculator

- **Improved White's emasculator:** has a double crushing blade. The cord has to be cut with a separate blade or scissors.



Figure 14: Improved White's emasculator

- **Verboczy triple crush emasculator:** this instrument has three actions; it clamps, crushes and cuts at the same time.



Figure 15: Verboczy emasculator

- **Henderson's castrating tool:** used with a hand drill, which uses the twisting action to close the severed cord. Minimizes blood loss and risk of haemorrhage, post-castration swelling, infection and trauma.

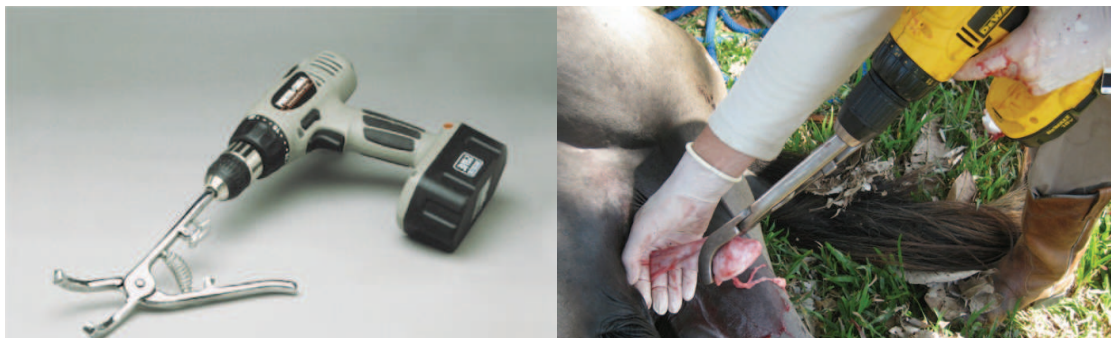

Figure 16, 17: Henderson's castration tool

The improved White's emasculator is the most commonly used emasculator in the United States, followed by Serra's and Reimer's emasculator (Moll, Pelzer und Pleasant 1995). The retrospective study of Moll et al. (1995) of 23'229 routine castrations showed a significant difference between the Serra's and the Reimer's emasculator with regards to excessive bleeding (1.76% vs. 2.44% of cases, respectively). However, the rate of complication was not

significantly different between the Serra's and the White's, nor between the White's and the Reimer's. The reason for the significantly higher rate found for the Reimer's in comparison to the Serra's is unclear, as the Reimer's crush the cord and then have a controlled cut with an attached scissors, while the Serra's crush at the same time as do the improved White's.

However, the biological importance of this difference remains questionable, therefore it is at the veterinary surgeon's discretion to choose his emasculator of choice. Much more important seem the correct application, as well as proper and adequate maintenance and cleaning of the surgical instruments. The importance of proper and adequately maintained surgical instruments cannot be overemphasized.

5.2 Self-evaluating questions

15. What is the advantage of the Henderson castration?
 - a. Triple crushing
 - b. Twisting action minimizes blood loss
 - c. Separate blade for cutting
 - d. Crushing and cutting at the same time

16. What is the main difference between the Sand and the Reimer emasculator?
 - a. Separate handle for cutting
 - b. Double crushing
 - c. Twisting action
 - d. Curved blades

6. Positioning of the patient

6.1 Standing castration

Careful selection of suitable candidates for standing castration is strongly recommended, as it can be difficult and dangerous for the surgeon if the horse is acting up during surgery. Docile stallions with well-developed testicles are the safest candidates for standing castrations (Schumacher 2006).

Standing castration is not recommended for the following candidates (Schumacher 2006):

- Small horses with poorly developed testicles
- Ponies due to the difficult approach because of their small size
- Mules and donkeys because of their athletic agility

Advantages of the standing castration are the lower costs and a smaller need for surgical assistance. In addition, castration of the standing horse is usually significantly faster. Last, this procedure can be a suitable option for horses that are considered risk patients for anaesthesia (Schumacher 2006).

Sedation of the horse is not always necessary, but advisable. Most commonly used drugs in combination, are α 2-agonists such as xylazine hydrochloride, detomidine, or pentazocine and butorphanol tartrate (Schumacher 2006). A nose twitch may also be applied to facilitate restraint (Kilcoyne 2013). The use of acepromazine or other phenothiazine derivatives should be avoided as it can cause priapism or long lasting penile prolapse (Schumacher 2006). Local analgesia is essential in standing castration. The scrotum is anaesthetized along the line of incision. The spermatic cords can be anaesthetized by injecting local anaesthetic solution like lidocaine or mepivacaine (Kilcoyne 2013). This ensures a good local anaesthesia but may cause haematomas, which could interfere with the application of emasculators. Another possibility is to inject local anaesthetic solution directly into the testicular parenchyma (Schumacher 2006). Scrubbing of the scrotum should be performed twice, before and after administering local anaesthesia solution (Schumacher 2006).

Prior to starting the surgical procedure, it is advised to wrap the tail to prevent contamination of the surgical field. The horse should be restrained by a competent handler, which is positioned on the same side of the horse as the surgeon. The surgeon should stay as close to the horse's shoulder as possible with extended knees (Figure 18), keep his head up and use reach of arms, to avoid kicking injuries (Schumacher 2006).

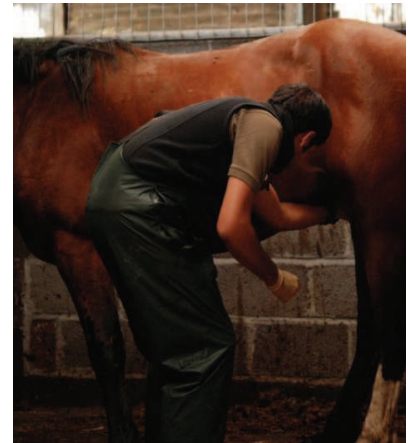


Figure 18: Surgeon's position in standing castration

6.2 Recumbent castration

Recumbent castration permits a better overview of the surgical field and a decreased risk for surgeon (Searle, et al. 1999). A requirement for recumbent castration is a clean, safe area for induction and recovery (Schumacher 2006). Usually, only a short-term general anaesthesia is necessary, which can be achieved with xylazine hydrochloride 1.1 mg/kg IV followed by ketamine 2.2-3.0 mg/kg IV. This method provides 10-15 minutes of anaesthesia and can be prolonged if butorphanol or diazepam is applied shortly after or together with xylazine hydrochloride. If more time is necessary, ketamine and xylazine hydrochloride can be reapplied at half the dose (Samper, Pycock und McKinnon 2007). If available, inhalational anaesthesia provides a safe and deep general anaesthesia and is generally preferred.

Once the patient has been anaesthetized, the horse is placed in lateral or dorsal recumbency. Lateral recumbency is less demanding for the cardiovascular system of the horse whereas dorsal recumbency provides a better reach of both testicles (Samper, Pycock und McKinnon 2007).



Figure 19: Castration in field with rope restraint

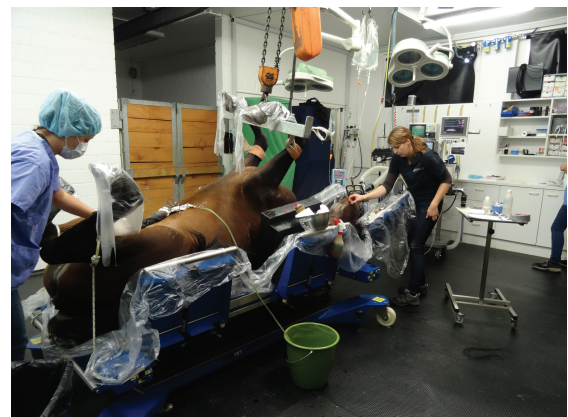

Figure 20: Castration in clinic in dorsal recumbency

6.3 Self-evaluating questions

17. What are suitable candidates for the standing castration?
 - a. Small horses
 - b. Docile stallions
 - c. Agile donkeys
 - d. Ponies

18. What are the advantages of the standing castration?
 - a. Lower costs
 - b. Faster
 - c. Less bleeding
 - d. Less assistance needed

19. What are the advantages of the recumbent castration?
 - a. Decreased risk for the surgeon
 - b. Faster
 - c. Better overview of the surgical field
 - d. Less assistance needed

7. Surgical techniques for the castration of normal horses

Castration of the stallion can be performed using a wide array of different techniques. These include open, closed and semi-closed castration, which are the most common procedures used to date. The stallion is castrated in standing or recumbent position with a scrotal or inguinal approach. The terms “open” or “closed” castration describe whether the parietal vaginal tunic is incised or not and do not describe whether the wound is left open to heal by secondary intention or sutured (Schumacher 2006).

In addition, alternative techniques include laparoscopic castration, vasectomy, and immunologic castration. These procedures will be discussed individually in the sections below.

7.1 Open technique

The open technique includes the incision of the parietal vaginal tunic. It is defined as incising the skin, the tunica dartos, the scrotal fascia and the parietal vaginal tunic (Moll, Pelzer und Pleasant 1995). The ligament of the tail of the epididymis, which attaches the parietal vaginal tunic to the tail of the epididymis, is severed. The fold of the mesorchium and mesofuniculum is transected and completely freed from the parietal tunic. The testicle is removed using an emasculator (Schumacher 2006). The open technique is probably the most commonly used technique in equine castration (Moll, Pelzer und Pleasant 1995).

7.2 Closed technique

With the closed technique, incisions are made in similar fashion as described for the open technique. However, when using the closed technique the parietal tunic is not incised (Searle, et al. 1999). The testicle is stripped manually of the scrotal fascia, still encapsulated by the tunica vaginalis. Thereafter, both testes are removed using an emasculator. With this technique, care should be taken not to include or sever the large pudendal vessels that lie within the scrotal fascia (Schumacher 2006).

7.3 Semi-closed technique

This technique is performed in similar fashion as described for the closed technique. However, for this technique a 2-3 cm long incision is made through the exposed parietal

tunic at the cranial end of the testis. A thumb is inserted into this incision to prolapse the testis out of the parietal tunic. The testicles are then removed together with the parietal tunic and the distal portion of the cord by emasculators. For that reason it can be considered a closed technique (Schumacher 2006).

7.4 Advantages and disadvantages of described techniques

The closed and the semi-closed technique have the advantage, that the removal of the parietal tunic decreases the risk of postoperative complications such as septic funiculitis or hydrocele. The advantage of the closed techniques is the decreased risk of eventration in horses with an unapparent inguinal hernia, but only if an additional ligature is placed proximal to the site of transection. Without ligation there is no difference between the closed or open technique when it comes to evisceration. The closed and semi-closed techniques require more dissection, for that reason an open castration is preferred when performing a standing castration (Schumacher 2006).

7.5 Removal of the testes

Emasculators are used to crush the cord, thereby providing haemostasis of the blood vessels within the spermatic cord. Emasculators are applied at a right angle to the spermatic cord (Figure 21) and loosely closed to avoid incorporation of skin. Care is

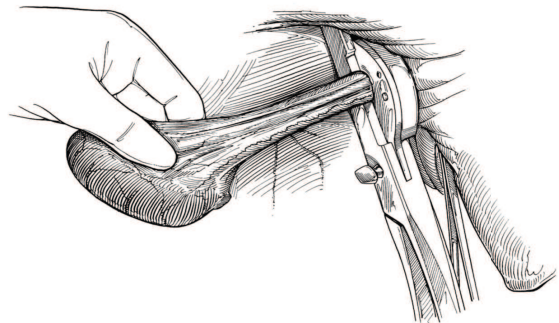


Figure 21: Removal of the testis using an emasculator

taken to hold the emasculator in such a way, that the wing-nut of the emasculators are facing the testicles, to ensure that the component that crushes the tissues is positioned proximally to the cutting part of the instrument. This position is said to be “nut-to-nut” and is especially important when emasculators have a cutting blade incorporated. The scrotal skin is pushed toward the abdomen and care is taken not to incorporate any skin before crushing of the cord is performed. The time between application and removal of the emasculator depends on the thickness of the cord. Efficient haemostasis is usually achieved after one minute of applied crushing. Alternatively, the parietal tunic and the cremaster muscle can be crushed separately from the testicular vessels and the ductus deferens, if the

cord has a large diameter. Emasculator blades that are slightly blunt are preferred over sharp ones, so that the cord is not sharply cut but partially torn, which helps with haemostasis. If emasculators without incorporated blades are used, the cord is cut 2-3 cm distally to the emasculator using a scalpel blade. Loose scrotal fascia is removed when protruding from the scrotal opening (Schumacher 2006).

7.6 Skin closure

The surgical incisions can be closed primarily or can be left open, so that the wound will heal by secondary intention. Primary closure (Figure 22) leads to a faster healing, decreases convalescence, minimizes postoperative treatment and excludes the possibility of eventration of intestines (Schumacher 2006).

However, primary closure requires strict aseptic technique and can only be performed in a surgical theatre (Palmer 1984).

Traditionally, the scrotal wounds are left open to heal by secondary intention, as this technique is more convenient. In addition, some surgeons prefer to stretch the incision (Figure 23) site to ensure adequate drainage of the wound. Nonetheless, the complication rate of castration with healing by secondary intention is markedly higher as compared with primary closure (Shoemaker, et al. 2004) (Moll, Pelzer und Pleasant 1995).

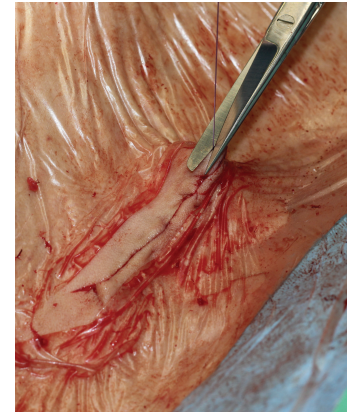

Figure 22: Primary wound closure

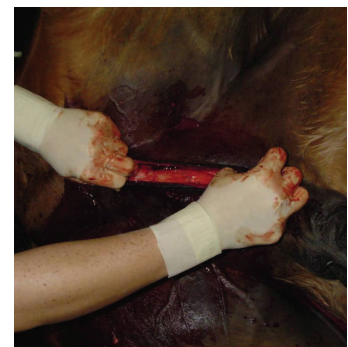

Figure 23: Stretching of the incision

7.7 Self-evaluating questions

20. Which structures are incised in the open technique?
- Skin, tunica dartos, scrotal fascia and parietal tunic
 - Skin, tunica dartos, scrotal fascia and visceral tunic
 - Skin, tunica dartos, parietal and visceral tunic
 - Skin, tunica dartos, visceral tunic and mesorchium

21. What structure is not incised using the closed technique?
- a. Visceral tunic
 - b. Tunica dartos
 - c. Scrotal fascia
 - d. Parietal tunic
22. What are the advantages of the primary closure of the skin in castrations?
- a. Decreases convalescence
 - b. Minimizes post operative treatment
 - c. Less complications
 - d. All of the above

8. Surgical approach

8.1 Scrotal approach

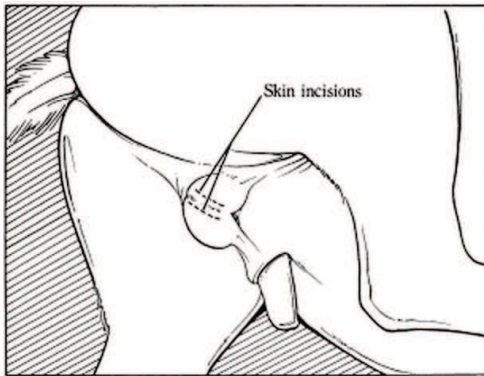


Figure 24: Scrotal approach

Probably the most commonly used technique for equine castration is the open technique with scrotal approach (Moll, Pelzer und Pleasant 1995). This method can be performed in standing and recumbent stallions.

Two incisions are made parallel to the raphe scroti (Figure 24), approximately 2 cm apart and 8 to 10 cm long, cutting through the scrotal skin, tunica dartos, scrotal fascia and parietal tunic (Searle, et al. 1999). The ligamentum caudae epididymis is severed or bluntly dissected and the cord is stripped digitally to remove the fascia as far proximal as possible. The use of a gauze sponge can facilitate the stripping of the subcutaneous tissue (Turner und McIlwraith 1983). The testis, epididymis and distal portion of the spermatic cord are completely freed from the parietal tunic. An emasculator is used to remove the testicle, leaving the parietal tunic in place (Schumacher 2006). Depending on the emasculator used, the cord is crushed and simultaneously cut with the emasculator's blade or separately with a scalpel blade. Care must be taken to apply the emasculator correctly without incorporating skin between its jaws and to prevent stretching the spermatic cord when emasculating. The wound can be closed with an intracutaneous, continuous suture or left open to heal by secondary intention, as described in the previous chapter.

The advantage of this approach is the possibility to perform the castration in standing and recumbent stallions as well as the application of the open, closed or semi-closed technique. However, the closed technique is preferred as it has a decreased risk of developing postoperative complications (Schumacher 2006).

8.2 Inguinal approach with primary wound closure (Swiss technique)

As described above, castrations with primary wound closure, have much lower complication rates than castrations with healing by secondary intention (Moll, Pelzer und Pleasant 1995) (Shoemaker, et al. 2004). With this in mind, a novel technique was developed to access the

testicles with an inguinal rather than a scrotal approach. The horse is castrated under general anaesthesia in dorsal recumbency. After locating the external inguinal ring by palpation, the testicles are pushed cranially into the region over the external inguinal ring (Figure 25). A 5-7 cm long skin incision is made over the testicle and stretched with the index fingers.

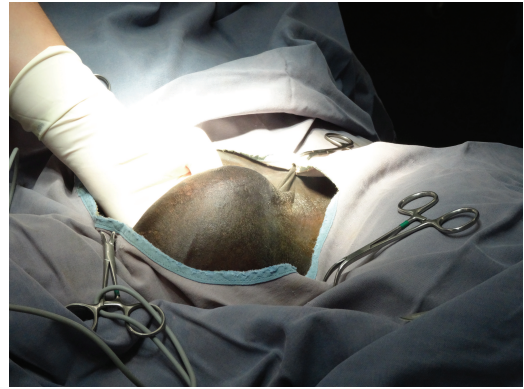
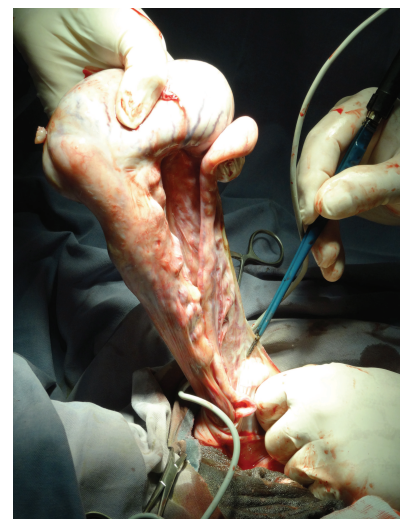


Figure 25: Pushing the testicle cranial over the region of the external inguinal ring

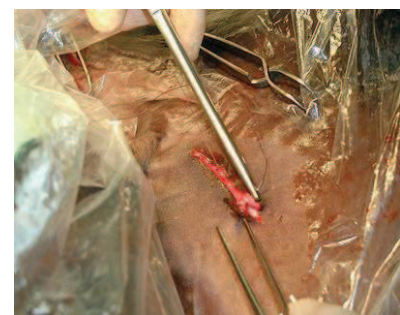The vaginal tunic is incised and grasped with 2 pean forceps on either side of the incision. The vaginal tunic is not separated from the surrounding tissue, thereby decreasing soft tissue trauma. The ligamentum caudae epididymis is identified by inserting the index finger into the vaginal process to exteriorize the testicle. The ligamentum is cut, while the mesorchium and distal part of the mesofuniculum are bluntly separated. Any bleeding vessels are cauterized (Figure 26). The spermatic cord is ligated twice with a transfixing ligature and a modified Miller's knot. Sutures are placed 1 cm apart and are positioned as far proximal as possible before removing the testicle. The pedicle is repositioned into the vaginal process after inspection for haemorrhage. The vaginal tunic and overlying fascia are closed with a simple continuous suture pattern (Figure 27). The skin is closed using a simple continuous, intracutaneous suture pattern (Kummer, et al. 2009).



Picture 26: Bleeding vessels are cauterized

Advantages of this surgical technique over the other techniques include little soft tissue trauma and a decreased rate of postoperative complications due to primary closure of the surgical wound. In addition, the inguinal skin seems to be less prone to inflammation compared to the scrotal skin, resulting in a lower incidence of inflammation and seroma formation (Kummer, et al. 2009).

Disadvantages of this technique include the higher costs and the extent duration of anaesthesia due to catheterisation of the bladder, aseptic preparation of the



Picture 27: Closure with simple continuous pattern

surgical site and a more elaborate surgical technique (Kummer, et al. 2009). However there were already two clinics where a postoperative inguinal herniation developed within 24 hours after surgery using this technique (Gàbor Bodó personal communication). The reason for this happening is most probably the increased space in the inguinal canal after the removal of the testicle with the spermatic cord. The complication is seldom, however it can happen.

8.3 Laparoscopic intra-abdominal ligation of spermatic cord

Laparoscopic surgery is based on the concept of triangulation, where the telescope and the instruments enter the abdomen from different angles. In this particular technique, the actual testes are not removed from the body, but the vascular supply and the deferent ducts are ligated, resulting in in-functional testes.

Feed should be withheld for 24 hours to improve intra-abdominal space for surgery. An additional effect of withholding feed is the decreased weight pressing against the diaphragm when horses are operated in a recumbent position tipped into the Trendelenburg position, where the head is lowered and the tail elevated. In addition, the peritoneal cavity is insufflated with carbon dioxide (Hendrickson 2006). The laparoscopic castration can either be done standing (Figure 28) or anaesthetized in dorsal recumbency (Rijkenhuizen und Grinwis 1999) (Wilson, Hendrickson und Cooley 1996). The standing approach is preferred due to the absence of the risk of general anaesthesia and complications associated with post-operative recovery (Rijkenhuizen und Grinwis 1999).

After sedating the patient, local infiltration anaesthesia is provided at the entry sites of the surgical instruments and the instruments are inserted. The middle portal is placed at the level of the ventral aspect of the tuber coxae, midway between the tuber coxae and the last rib, one portal 10 cm dorsal and 5 cm rostral and another portal 10 cm ventral of this. Before placing the portals the sites are infiltrated with 2% lidocaine or

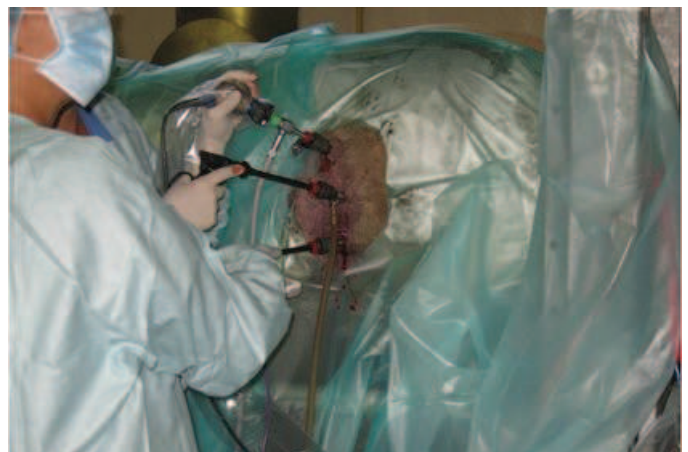

Figure 28: Laparoscopy in a standing horse

mepivacain (Hendrickson 2006). After visualising the anatomical structures of interest, the blood supply and the ductus deferens are ligated and transected laparoscopically with the testicles left in place.

During the first week after operation the size of the testicles increases due to the swelling caused by the deprivation of the blood supply. Thereafter, the testes start decreasing in size. Testosterone levels falls within 7 days to below detection level (Rijkenhuizen und Grinwis 1999).

The main advantage of laparoscopic surgery is that it is a minimally invasive procedure. However, there is a risk of postoperative revascularisation of the testes. Voermans et al. reported that 5.6% of inguinally retained testes and 3.4% of normally descended testicles failed to become completely necrotic following laparoscopic castration with ligation of the testicles (Voermans et al. 2006). The testicles were able to re-vascularize through an alternate blood supply via the cremasteric and/or external pudental artery. The laparoscopic method with the testicle left in place therefore cannot be recommended as a trustworthy method for castration (Voermans, Rijkenhuizen und Van der Velden 2006).

8.4 Vasectomy

A vasectomy can be performed in stallions if they are used as a teaser stallion to detect oestrus in breeding mares. The advantage of this procedure is that the stallion remains sexually active on a behavioural level, but cannot effectively ejaculate spermatozoa and therefore cannot impregnate mares accidentally.

The horse is anaesthetized in dorsal or lateral recumbency. An incision is created over each spermatic cord.

The ductus deferens is identified and ligated twice (Figure 29). One ligature is placed at its most proximal aspect, one at the most distal aspect. Thereafter, the segment of the ductus deferens in between the two ligatures is removed. Double-ligation is used to prevent the formation of a sperm granuloma and to decrease the likelihood of re-anastomosis (Schumacher 2006).

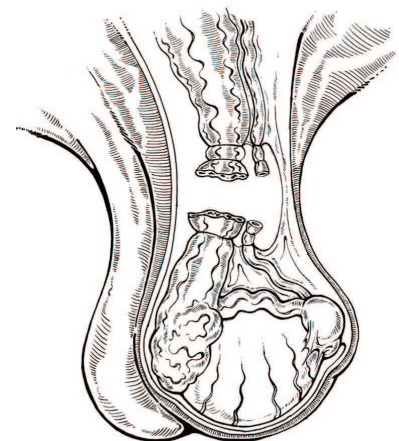


Figure 29: Ligated ductus deferens

8.5 Immunologic castration

Undesirable sexual behaviour can interfere with the athletic performance of a stallion. As a consequence of sexual behaviour, stallions can be extremely difficult to handle and can thereby fail to perform at their expected athletic potential (Dowsett, et al. 1993). Castration might make stallions more docile and easier to handle, but it also results in the operated stallion becoming infertile. Therefore, efforts have been made to design a method for immunologic, reversible castration, with the aim of reducing the negative side effects of sexual behaviour and retaining the ability of the stallion to reproduce.

In order to suppress the negative effects of active testicular function, there are several studies reporting on the immunization against luteinizing hormone-releasing hormone (LHRH) (Schanbacher und Pratt 1985) or gonadotropin-releasing hormone (GnRH) (Malmgren, Andresen und Dalin 2001). In these studies, immunisation resulted in the production of antibodies against GnRH (or LHRH respectively) in all stallions. The production of these antibodies resulted in decreased plasma testosterone concentrations, decreased testicular size and pronounced histological alterations within the testicular tissue. In addition, immunologic castration was shown to induce no adverse effects on sperm quality and motility (Turkstra, et al. 2005).

However, a significant individual variation among the stallions regarding the suppression of testicular function and libido was evident (Malmgren, Andresen und Dalin 2001). Therefore, before this vaccination can be applied in a clinical setting, further research is necessary to achieve a less variable response in immunosuppression.

8.6 Self-evaluating questions

23. What are the advantages of the inguinal approach?
 - a. Lower costs
 - b. Short duration of anaesthesia
 - c. Decreased rate of postoperative complications
 - d. Lower incidence of seroma formation

24. What is the concept of the laparoscopic intra-abdominal ligation of the spermatic cord?
- The testicles are ligated intra-abdominally, transected and exteriorized
 - The testicles are ligated intra-abdominally, transected and left in place
 - The testicles are ligated intra-abdominally and exteriorized
 - The testicles are ligated intra-abdominally and left in place
25. What are the advantages of the vasectomy?
- The horses can be used as teaser stallions
 - The horses only lose their male behaviour
 - The horses remain sexually active on behavioural level
 - None of the above
26. What are the consequences of immunologic castration?
- Production of antibodies against Testosterone
 - Production of antibodies against GnRH
 - Production of antibodies against LHRH
 - Production of antibodies against LH

9. Monorchidism and Cryptorchidism

Monorchidism and cryptorchidism are abnormalities of the testicles that are commonly seen in stallions. The knowledge of these diseases is imperative for the equine surgeon, since castration of stallions affected by these conditions involves a different surgical approach. In the sections below, a brief overview of these conditions is given. Thereafter, surgical approaches for castrating horses affected by these conditions are described.

9.1 Monorchidism

Monorchidism describes the rare situation of the absence of one testis. This condition can be congenital or acquired due to the failure of the surgeon to remove both testes. Monorchidism is more likely caused by testicular degeneration, for example due to torsion of the spermatic cord, rather than due to real congenital atresia. The degeneration can occur before birth in the undescended testis or in an abdominal testis after birth (Schumacher 2006). The presence of the vaginal process, remnants of the cremaster muscle, ductus deferens or testicular vessels within the inguinal canal, suggest that the monorchidism is acquired (Parks, et al. 1989).

To confirm monorchidism, human chorionic gonadotropin stimulation test is performed after the surgical removal of the contralateral testis (Parks, et al. 1989). This test is used to determine, whether further testicular leydig cells, capable of producing testosterone in response to chorionic gonadotropic, are present. If no increase in testosterone plasma levels is recognized, the absence of testicular tissue is confirmed (Parks, et al. 1989).

9.2 Cryptorchidism

Cryptorchidism is the failure of one or both testicles to descend into the scrotum (Cox, Edwards und Neal 1979). This condition can be unilateral or bilateral and is the most prevalent, nonlethal developmental defect in the horse (Bergin, et al. 1970). The prevalence for cryptorchidism is about 17% and is highest in Percherons, American Saddlebreds, American Quarterhorse, Ponies and crossbred horses. (Hayes 1986). Bilateral cryptorchidism occurs in up to 14% of the cryptorchid horses (Stickle und Fessler 1978).

Cryptorchid testicles can be found either in the inguinal canal (Figure 30) or in the abdominal cavity. Normal spermatogenesis does not occur in cryptorchid testicles, but the hormone production is usually not affected resulting in fertile stallions in case of unilateral cryptorchidism. Bilaterally cryptorchid stallions are sterile but still show stallion-like behaviour due to the continuous hormone production (Turner 2006), (Bergin, et al. 1970).

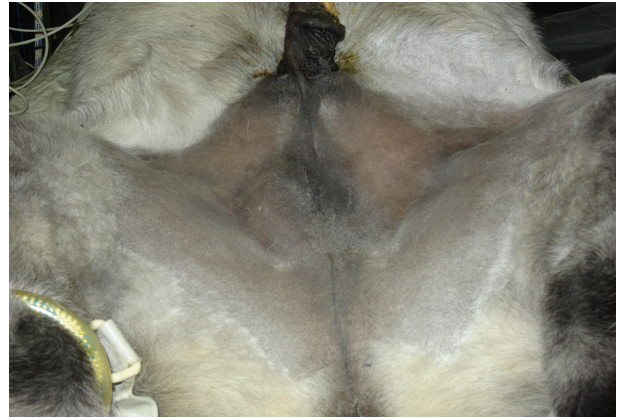

Figure 30: Cryptorchid Miniature Horse with the left testicle palpable retained in the inguinal canal

Improper function of the gubernaculum is thought to be the cause of failure of testicular descent (Bergin, et al. 1970). Another potential cause is the failure of the gubernaculum to expand, resulting in failure of the vaginal ring to enlarge sufficiently to allow the passage of the testicle into the scrotum (Schumacher 2006). The testicles may fail to regress to a small enough size to allow passage through the vaginal ring (Bergin, et al. 1970). Genetic studies indicate that hereditary factors are involved in this condition, although no plausible genetic mechanism was found yet (Schumacher 2006).

The failure of the right or left testicular descent occurs with nearly equal frequency (Stickle und Fessler 1978) (Cox, Edwards und Neal 1979), whereas abdominal testicular retention occurs more often than inguinal testicular retention. Seventy-five percent of the left testicles and 42% of the right testicles remain in the abdominal cavity (Stickle und Fessler 1978). This might be caused by the larger size of the left testicle during the stage of testicular regression (Smith 1975).

9.3 Self-evaluating questions

27. What is a monorchid stallion?
- The stallion possesses only one testicle
 - The stallion was born with only one testicle
 - The surgeon failed to remove both testicles
 - All of the above

28. What is true for cryptorchid stallions?
- a. Cryptorchid testicles can be found either in the inguinal canal or in the abdominal cavity
 - b. The hormone production is unaffected in the cryptorchid testicle
 - c. Spermatogenesis is not affected
 - d. Bilateral cryptorchid stallions are fertile

10. Surgical approaches for cryptorchid stallions

Surgical options to remove cryptorchid testicles include inguinal, parainguinal, suprapubic paramedian, and flank approaches or laparoscopic techniques in standing or recumbent positions.

10.1 Inguinal approach

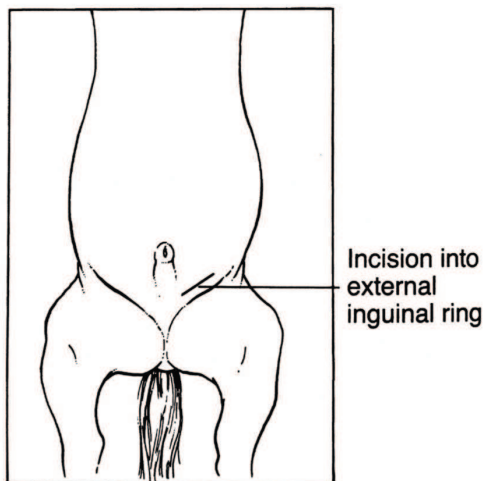


Figure 31: Inguinal approach

The horse is anaesthetized and placed in dorsal recumbency for the inguinal approach (Figure 31). An 8 to 15 cm long skin incision, depending on the size of the horse, is placed over the superficial inguinal ring (Cox 1993). The inguinal fascia is separated digitally to expose the inguinal ring. Testicles positioned within the inguinal canal can already be located at this time. To search for an abdominal testicle, the white parietal tunic of the vaginal process is identified. Another option is to identify the scrotal ligament exiting from the

superficial inguinal ring. Be careful not to mistake the genitofemoral nerve for the ligament (Schumacher 2006). Gentle traction on the scrotal ligament will evert the scrotal process (Valdez, et al. 1979). Opening the scrotal process permits the identification of the epididymis. Gentle traction on the epididymis will expose the ductus deferens followed by proper ligament of the testis and finally the attached testicle. The vaginal sac should always be opened and its components examined to avoid mistaking the descended tail of the epididymis for an abdominal testis (Schumacher 2006). The testicles are removed after crushing the cord using techniques as described for routine castration in chapter 8.

If the vaginal ring can accommodate more than the tips of the index and middle fingers, measures must be taken to avoid evisceration (Schumacher 2006). The inguinal canal can either be packed with sterile gauze for up to 36 hours or the superficial inguinal ring can be closed primarily (Searle, et al. 1999).

10.2 Parainguinal approach

A 4 cm long incision is made in the aponeurosis of the external abdominal oblique muscle, 1-2cm medial and parallel to the superficial inguinal ring (Schumacher 2006). The incision is centred over the cranial aspect of the ring (Figure 32). The inner abdominal oblique muscle is spread in the direction of the fibres before penetrating the peritoneum with the fingers (Wilson und Reinertson 1987). The vaginal ring can be palpated in caudolateral direction of the entry incision. The epididymis, ductus deferens, gubernaculum or testis can be identified, grasped and exteriorized. After excising the testicles, the aponeurosis is sutured using No 1 or 2 Vicryl or PDS suture material.

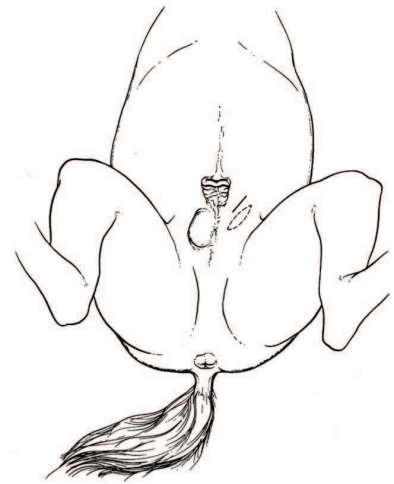

Figure 32: Parainguinal approach

Some surgeons prefer this approach because the vaginal ring is left intact (Wilson und Reinertson 1987). The aponeurosis can be sutured more easily than the inguinal ring and the approach permits a better exploration of the abdomen in case of an abdominally retained cryptorchid testicle (Wilson und Reinertson 1987).

If the vaginal process cannot be located using the inguinal approach, the incision can be converted into a parainguinal approach permitting the non-invasive removal of the testis (Schumacher 2006)

10.3 Suprapubic paramedian approach

An 8-15 cm long skin incision is made 5-10 cm lateral to the ventral midline, beginning at the level of the preputial orifice in the dorsal recumbent horse and extends caudally (Schumacher 2006). Subcutaneous vessels are routinely ligated. The abdominal tunic and the ventral sheath of the rectus abdominis muscle are incised, while the fibres of the dorsal sheath of the rectus abdominis muscle are separated bluntly. The dorsal rectus sheath, retroperitoneal fat and peritoneum are penetrated using manual manipulation, and the opening is widened that the surgeon's hand can be introduced into the abdomen. The testis is traced by its accessory structures and exteriorized. The testicles are removed using an emasculator or an écraseur if the testicle cannot be exteriorated sufficiently. In the case of a bilateral cryptorchid, botch testes can be removed through the same incision. After removal

of the testicles the abdominal tunic, the subcutis and the skin are each closed with a separate layer using interrupted or continuous sutures (Schumacher 2006).

10.4 Flank approach

The horse can be castrated in standing or recumbent position using the flank approach. A 10-15 cm long incision is made through the skin and subcutis in the paralumbar fossa of the affected side (Figure 33). If the horse is castrated in standing position, the incision site must be anaesthetized first. The external abdominal muscle is transected in the direction of the incision, while the internal abdominal oblique and the transversus abdominis muscle are transected along their fibres (grid technique).

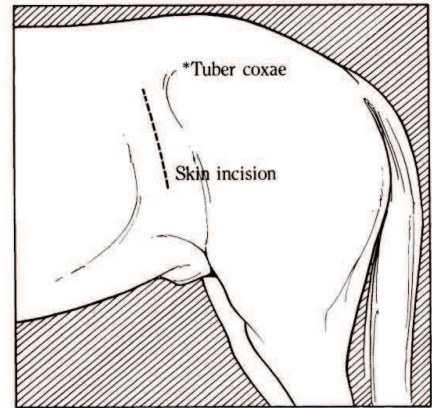


Figure 33: Flank approach

The peritoneum and retroperitoneal fat are perforated with the finger to locate and exteriorize the testicle. With the help of an *écraseur*, the testicular vasculature is transected to permit the exteriorisation of the testis (Swift 1972). An *écraseur* might not be needed if the testicle can be ligated in place in the abdomen or exteriorized for ligation. After removal the different layers (abdominal tunic, subcutis and skin) are closed separately with interrupted or continuous sutures (Swift 1972).

10.5 Laparoscopic method

Like in a normal castration, a laparoscopic approach can be used in either standing or recumbent position. Withholding feed from the animal and inflation of the peritoneal space with carbon dioxide creates an operating space and decreases the risk of penetrating organs when instruments are induced (Hendrickson 2006). Standing surgery does not require food withholding for as long as with patients in dorsal recumbency.

The laparoscopic approach allows direct visualization of the location of the testicles and is especially useful when a previous attempt to remove a cryptorchid testicle has failed (Hendrickson 2006).

10.5.1 Standing laparoscopic cryptorchidectomy

The benefits of the standing laparoscopic cryptorchidectomy are the absence of general anaesthesia and associated complications, and the improved detection of the testis. The horses are sedated and placed in stocks for the standing laparoscopic cryptorchidectomy (Hendrickson 2006). After the exploration of the abdomen and identification of both inguinal rings, the cryptorchid testicle is identified and infiltrated with 2% lidocaine. The retained

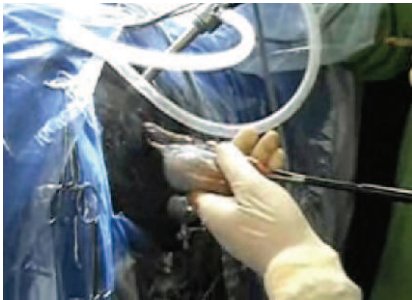


Figure 34: Laparoscopic removal of an abdominal cryptorchid testicle in standing position

testis is grasped for ligation and amputation and removed through an extended incision (Figure 34). The mesorchium can be either ligated with a modified Roeder knot or with the use of the “Ligasure” vessel-sealing device. The extended incision is sutured with a simple continuous pattern while the other portals are closed in a cruciate pattern (Hendrickson 2006).

10.5.2 Recumbent laparoscopic cryptorchidectomy

In case of fractious stallions not standing still in stocks for surgery, it is best to plan for general anaesthesia instead of a standing approach (Hendrickson 2006). The horse is placed in dorsal recumbency in the Trendelenburg position. This position involves elevation of the hindquarters by 30°. It has a negative impact on the cardiovascular system and is thus not really appreciated by anaesthesiologists. After aseptically preparing the region between the xiphoid and the pelvis, a 1 cm incision is made through the skin and linea alba, just rostral to the umbilicus. The abdomen is insufflated and explored before additional portals are created. After identifying the testis, it is ligated and amputated as described for the standing laparoscopic cryptorchidectomy (Hendrickson 2006).

Both techniques can be adapted in case of bilateral cryptorchids. In case of a unilateral cryptorchid, the descended testis is removed via standard castration (Hendrickson 2006).

10.6 Self-evaluating questions

29. What structures can one use to orientate oneself in the inguinal approach to be able to identify the abdominal testicle?
- The epididymis
 - The parietal tunic of the vaginal process
 - The scrotal ligament
 - The genitofemoral nerve
30. What are the advantages of the parainguinal compared to the inguinal approach?
- Permits a better exploration of the abdomen
 - It is easier to suture
 - The vaginal ring is left intact
 - All of the above
31. Which muscle is incised using the suprapubic paramedian approach?
- The ventral sheath of the rectus abdominis muscle
 - The dorsal sheath of the rectus abdominis muscle
 - The external abdominal oblique muscle
 - The internal abdominal oblique muscle
32. What are the benefits of the laparoscopic method?
- Direct visualization of the location of the testicles
 - Can be adapted in case of bilateral cryptorchids
 - Can be performed in standing and recumbent position
 - All of the above

11. Post-operative recommendations

During the first 24h after surgery, activity should be restricted to avoid haemorrhage from the testicular and scrotal vessels (Schumacher 2006).

In case of a castration with secondary wound closure it is advised to walk and trot twice a day for 15-20 minutes for the first 8 days after surgery to prevent swelling of the surgical site. Daily exercise is advised, to prevent the wound from closing too early, thereby facilitating wound drainage. Hydrotherapy can ensure a clean and open wound, but it has been reported that horses receiving excessive hosing of the surgical wound might more likely develop excessive swelling and infection of the scrotum (Moll, Pelzer und Pleasant 1995). Alternatively, the owner can begin to ride the horse 24-48 hours after surgery (Hunt 1991).

After a closed castration from an inguinal approach the horses are not exercised during the first week. The wound needs healing and thus only hand walking is advised in order to prevent dehiscence of the sutured wound.

Generally the horses need a slow build up: full exercise is advised only after 3 weeks time. Last, it is advised to keep the gelding away from mares for a minimum of 2 days, as spermatozoa are still active during this period.

11.1 Post-operative medication

According to a survey in the UK in 2005 (Price, et al. 2005), 45.4% of veterinarians did not provide post-operative administration of non-steroidal anti-inflammatory drugs following castration. Only 36.9% of veterinarians routinely administered additional analgesic drugs after surgery. A combined therapy with butorphanol and phenylbutazone was not superior to either drug used alone and there was no significant difference between the treatment with either butorphanol or phenylbutazone alone (Sanz, et al. 2009). Postoperative administration of non-steroidal anti-inflammatory drugs, as required, may help to control postoperative pain and swelling (Searle, et al. 1999). Recommended analgesic drugs are phenylbutazone, flunixin, eltenac, ketoprofen and carprofen (Price, et al. 2005).

11.2 Self-evaluating questions

33. What would you recommend to an owner regarding exercise after a castration with secondary wound closure?
- Exercise the horse as soon as possible
 - Restrict the activity during the first 24h after surgery
 - No exercise during the first week after surgery then slow build up
 - Walking and trotting twice a day for 15-20 min for the first 8 days after surgery
34. What would you recommend to an owner regarding exercise after a castration with primary wound closure
- Exercise the horse as soon as possible
 - Restrict the activity during the first 24h after surgery
 - No exercise for the first week after surgery then slow build up
 - Walking and trotting twice a day for 15-20 min for the first 8 days after surgery
35. What drugs are recommended for analgesia post castration?
- Butorphanol
 - Meloxicam
 - Ketoprofen
 - Phenylbutazone

12. Complications

Although castration is one of the most common surgical procedures in equine veterinary practice and is generally considered a routine procedure, it is also the most common cause of lawsuits filed against equine practitioners in North America (Wilson und Quist 1992). Complications can have both medical and financial consequences (Kummer, et al. 2009).

According to a retrospective study of 324 horses, 10.2% of castrated horses developed a complication after closed castration in either lateral recumbency or while standing (Kilcoyne, Watson und Kass 2013). Of these horses, 75.8% developed complications that required no emergency treatment, such as mild swellings, seromas, infections or fever. Only one horse (3%) developed eventration of the small intestine and was euthanized due to poor prognosis and financial constraint of the owner (Kilcoyne, Watson und Kass 2013). Therefore, although most complications following castration are mild, it should be borne in mind that life-threatening complications could occur.

Several factors have been associated with a higher complication rate:

First, when comparing open, closed and semi-closed castration, a higher incidence of post-operative complications was associated with semi-closed castration compared to open or closed castration (Kilcoyne, Watson und Kass 2013). This finding was believed to be a result of the increased tissue handling associated with the former procedure (Kilcoyne, Watson und Kass 2013) (Moll, Pelzer und Pleasant 1995).

Second, in comparison to surgical wounds closed by primary closure, surgical wounds left to heal by secondary intention have been reported to involve a significantly higher complication rate. However, healing by secondary intention is significantly cheaper, even taking the additional medical treatment of the complications into account (Mason, et al. 2005) (Kummer, et al. 2009)

Third, an increased complication rate has been reported in older horses (>10 years of age) in comparison to younger horses castrated by way of the inguinal approach. In this study, older horses were more likely to develop seroma which was probably due to the more solid tissue between the vaginal tunic and surrounding tissue resulting in an increased degree of soft tissue trauma (Kummer, et al. 2009). In contrast, when evaluating the

complication rate in old and young horses irrespective of surgical technique, Kilcoyne et al. (2013) found no connection between patient age and the risk of developing complications.

Last, prolonged anaesthesia time or re-administration of anaesthetic agents are known to be associated with an increased complication rate (Kilcoyne, Watson und Kass 2013).

All in all, the equine surgeon should be aware of these factors with the aim of reducing the complication rate to a minimum. In the sections below, reported complications will be discussed individually.

12.1 Postoperative swelling and oedema

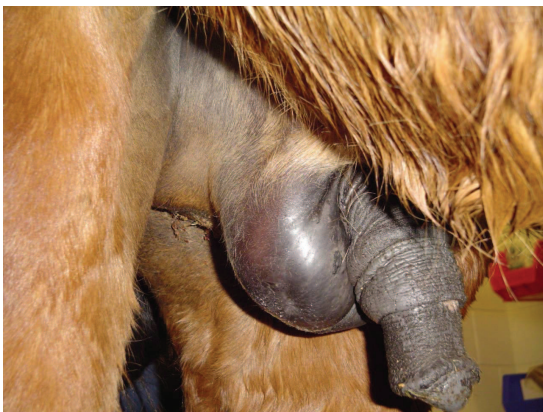


Figure 35: Postoperative swelling

Swelling and oedema are physiological tissue reactions after castration due to traumatic tissue handling. Postoperative swelling/oedema (Figure 35) reaches a highpoint approximately 3 to 6 days after surgery and should subside 9 days post-operatively (Hunt 1991). Excessive swelling has been reported as the most common post-operative complication of castration, and is mainly caused by inadequate wound drainage, inadequate post-operative exercise, poor lymphatic drainage, excessive surgical trauma and/or infection (Hunt 1991), (Schumacher 1996). Post-operative swelling can be prevented by making a large scrotal incision, avoiding excessive tissue trauma, removing of as much of the tunica vaginalis as possible, manual stretching of the incision, or removing the median raphe during surgery (Searle, et al. 1999).

This type of complication rarely poses a life-threatening crisis, but does lead to discomfort of the patient and extreme concerns of the owner. The swelling is painful and reduces the horse's willingness to exercise, which can exacerbate the swelling due to vascular stasis and which can lead to early wound closure.

If you have a large swelling in the days following castration, you should check the general status of the horse and examine the swelling by ultrasound (personal communication Gábor Bodó). It is advised to reopen the wound in case of an early closure to

permit adequate drainage and administer non-steroidal anti-inflammatory drugs to decrease the pain and inflammation (Hunt 1991). Severe swellings can have further consequences and lead to phimosis, paraphimosis, cellulitis, wound infection and dysuria (Nickels 1988).

12.2 Haemorrhages

The most common life-threatening complications associated with castrations are haemorrhages (Hunt 1991). They can occur during, immediately after or several days after surgery, and can originate from several locations. Small haemorrhages are frequently encountered post-operatively and usually originate from superficial subcutaneous vessels and generally stop bleeding within 10 to 15 minutes (Hunt 1991).

The most common source of severe postoperative haemorrhage (Figure 36) is the testicular artery of the spermatic cord (Hunt 1991). Bleeding of this artery is most likely caused by inadequate crushing of the cord, by defective emasculators or due to improper instrument handling. If the emasculators are too sharp, the cord may be cut before it is properly crushed (Schumacher 1996). A transfixation ligature placed around the spermatic cord or vasculature proximal to the emasculator can be applied to provide additional security against post-operative haemorrhages (Schumacher 2006). Though this is only advised in recumbent castrations.

Post-operative bleeding through the testicular artery can be stopped by grasping the cord and re-crushing it with the emasculator, or by applying a haemostat proximal to the bleeding vessel. As an alternative to the haemostat, a kidney clamp may be easier to apply and can be used alternatively and removed the following day. But the safest way in case of permanent bleeding is to put the horses in general anaesthesia, search for the bleeding vessels and ligate them with resorbing suture material (personal communication Gábor Bodó).

If the horse was castrated while anaesthetized in recumbent position, the cord and the scrotum are not de-sensitized and are highly sensitive to manipulation, which may make re-anaesthesia necessary. Packing the scrotum with gauze and temporarily closing it with

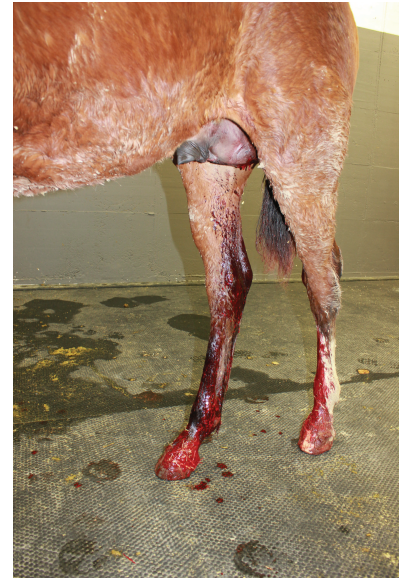

Figure 36: Haemorrhage from the scrotal vessels

sutures or towel clamps may also be an alternative, but may not put enough pressure on the stump to stop bleeding (Schumacher 1996).

If post-operative haemorrhage occurs from a superficial vein in the scrotal or inguinal area, ligation is the treatment of choice (Searle, et al. 1999). In case of significant blood loss, therapy is aimed at replacing the blood volume with two to three times the estimated volume of blood loss with a balanced crystalloid solution in addition to stopping the primary cause of bleeding (Hunt 1991). In case of extreme blood loss, blood transfusion may be necessary (Schumacher 1996).

12.3 Evisceration

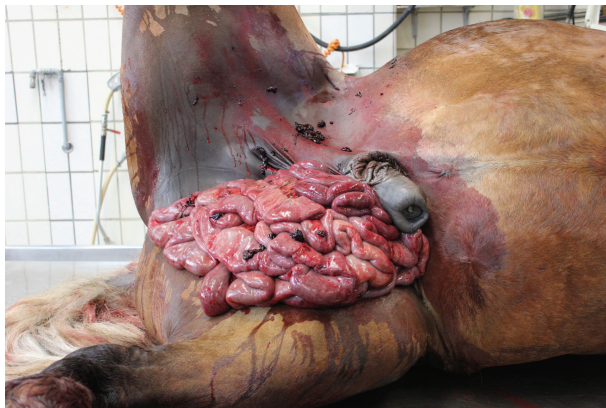

Figure 37: Evisceration after the castration

Evisceration, which is the protrusion of abdominal viscera through the vaginal ring and into the open scrotal incision (Figure 37), is an uncommon but potentially fatal complication of castration. It occurs in about 0.2% of all castrated horses, mainly due to a congenital hernia, which allow the intestines to protrude from the abdomen (Moll, Pelzer und Pleasant 1995). It

generally occurs within 4 hours after surgery (Hunt und Boles 1989). Standardbreds and Draft horses are at greater risk of evisceration, because they have a higher incidence of congenital inguinal herniation (Moll, Pelzer und Pleasant 1995), (Shoemaker, et al. 2004). Predisposing factors may include pre-existing inguinal herniation, enlarged inguinal rings, anaesthetic recovery, increased intra-abdominal pressure and rearing during the post-operative period (Searle, et al. 1999).

To decrease the risk of evisceration, the inguinal ring should be palpated before surgery and checked for an unapparent inguinal hernia and the owner should be asked whether the horse was suffering from a congenital inguinal hernia. Horses at higher risk for evisceration should be castrated in recumbent position using the closed technique and ligating the spermatic cord. Excluding the cremaster muscle from the ligation decreases the

risk of the ligature to loosen due to the absence of contraction of the remaining muscle (Shoemaker, et al. 2004).

Evisceration is considered a surgical emergency, and therefore treatment should be instated as quickly as possible. Treatment consists of anaesthetizing the horse as quickly as possible to prevent damage and contamination of the intestines. Dilation of the inguinal ring or a celiotomy is usually necessary to replace the intestines to avoid ischaemic damage to the eviscerated intestines (Schumacher 1996). More rapid surgical intervention accounts for a higher survival rate (Hunt und Boles 1989). Broad-spectrum antibiotics and analgesics should be given immediately and applied in all cases, as it is inevitable to contaminate the intestines during the evisceration (Hunt und Boles 1989). Intravenous fluid support is recommended.

With the horse in dorsal recumbency, visible debris should be removed and the prolapsed intestine should be lavaged copiously with a balanced electrolyte solution. Reduction of the prolapsed bowel into the abdominal cavity may require a laparotomy. Devitalized bowel necessitates resection and anastomosis. The external inguinal ring should be sutured after reduction of the prolapse (Hunt 1991).

12.4 Protrusion of omentum

It is possible that a part of the omentum protrudes through the incision (Figure 38). This complication is generally not life-threatening and can be treated by transecting the protruded omentum with an emasculator as far proximally as possible. Examination of the horse per rectum should be performed to control for intestines entering the inguinal canal (Schumacher 1996). To prevent further protrusion of omentum, the horse should be stalled for 48h. Additional measures, such as suturing of the inguinal ring or packing the inguinal canal with sterile surgical sponges, might not be necessary as the omentum

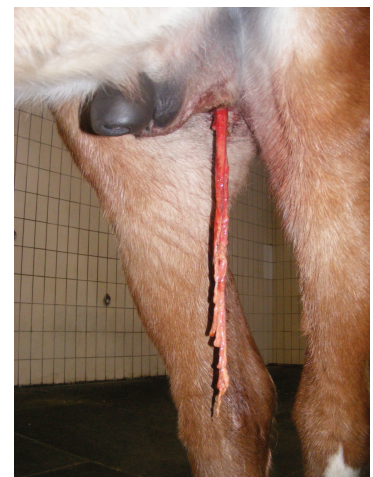

Figure 38: Protrusion of the omentum

occupies the canal, thereby preventing the intestines from entering (Schumacher 2006). Antibiotic administration is recommended to reduce the risk for ascending infection and peritonitis.

In case of severe or complicated omental prolapse, the animal is anesthetized and placed in dorsal recumbency. The prolapsed omentum and scrotal wound are cleaned. After proper surgical preparation, the inguinal area is approached surgically. The vaginal tunic is isolated and incised to reveal the prolapsed omentum and the stump of the spermatic cord. The omentum is ligated and transected within the vaginal tunic, then replaced into the abdomen. The spermatic cord is ligated and transected proximal to the previous site. The prolapsed omentum and distal spermatic cord can then be removed through the external scrotal wound, decreasing contamination of the inguinal surgical site and vaginal cavity (Schumacher 2006).

12.5 Septic funiculitis

Infection of the spermatic cord (funiculitis) can be caused by a spreading infection through the scrotal incision, especially if it closes prematurely and drainage is inhibited, or due to contaminated ligatures or emasculators (Schumacher 2006). Preputial and scrotal oedema, pain, pyrexia and sometimes lameness can be indicators for septic funiculitis. It may resolve with antimicrobial treatment and re-establishment of drainage, especially in early cases. Occasionally the removal of the infected stump is required (Schumacher 2006). Chronic infections with

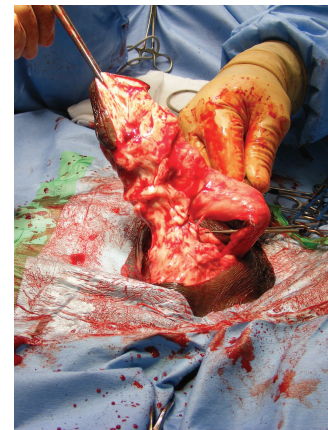

Figure 39: Scirrhus cord

pyogenic bacteria, such as *Staphylococcus* spp., are referred to as scirrhus cord (Figure 39) or botryomycosis (Hunt 1991). The stump becomes hard and enlarges with granulation tissue and abscesses. Scirrhus cord becomes clinically apparent from months to years after castration (Hunt 1991). It often interferes with locomotion and should be resected. In extreme cases, the infection may ascend into the abdomen and is palpable rectally (Schumacher 2006).

12.6 Clostridial infection of the castration wound

Depending on the *Clostridia* species involved, infection can be a severe complication due to the tissue necrosis and toxemia and consequent death within several days. *Clostridium tetani* causes paralysis and general spasms with protrusion of the third eyelid and “saw-

horse” stance. In contrast, *Clostridium botulinum* causes flaccid paralysis, which begins with decreased muscle tone of the tail and eyelids, weakened gait and dysphagia. Other Clostridia species such as *Clostridium septicum*, *Clostridium perfringens* or *Clostridium chauvoei* cause malignant oedema characterized by fever, toxæmia, accumulation of gas in the subcutis, and cellulitis. Clostridial infections have to be treated with high doses of penicillin, analgesics and non-steroidal anti-inflammatory drugs. In addition, a radical debridement of the necrotic tissue together with establishment of scrotal drainage is necessary (Schumacher 2006).

12.7 Septic peritonitis

Due to the communication of the peritoneal and vaginal cavity, peritonitis can develop due to ascending infections of the surgical site (Schumacher 1996). Peritoneal inflammation accompanied by bacterial infection is referred to as septic peritonitis and causes clinical signs including colic, pyrexia, weight loss, tachycardia, diarrhoea and reluctance to move (Dyson 1983). Nucleated cell numbers greater than 10'000 cells per μL in the peritoneal fluid indicate peritoneal inflammation. However, cell numbers as high as 100'000 per μL are not uncommon after uncomplicated castrations and indicate non-septic peritonitis (Schumacher, Schumacher und Spano 1988). Degenerated neutrophils or the presence of bacteria in the peritoneal fluid are more indicative of septic peritonitis, especially when accompanied by clinical signs like fever, depression, dehydration, diarrhoea or obstipation, abdominal pain and tachycardiasc (Schumacher 2006). Treatment includes antimicrobials, non-steroidal anti-inflammatory and analgesic drugs combined with supportive therapy, peritoneal drainage and lavage (Searle, et al. 1999). Proper drainage of the scrotal incision must be established (Schumacher 2006).

12.8 Penile damage

Inexperienced surgeons unfamiliar with the genital anatomy and orchidectomy are the main causes for penile damage (Figure 40). The shaft of the penis can be mistaken as an inguinal testicle (Schumacher 1996). Damage to the penile fascia can secondarily lead to excessive swelling, penile prolapse, priapism and penile paralysis (Searle, et al. 1999).

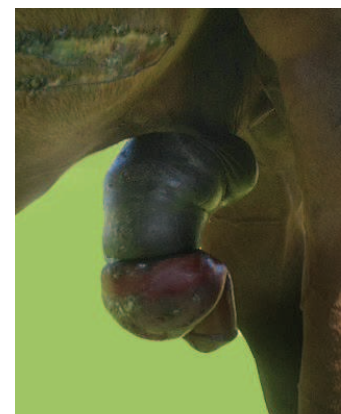


Figure 40: Penile damage

12.9 Hydrocele

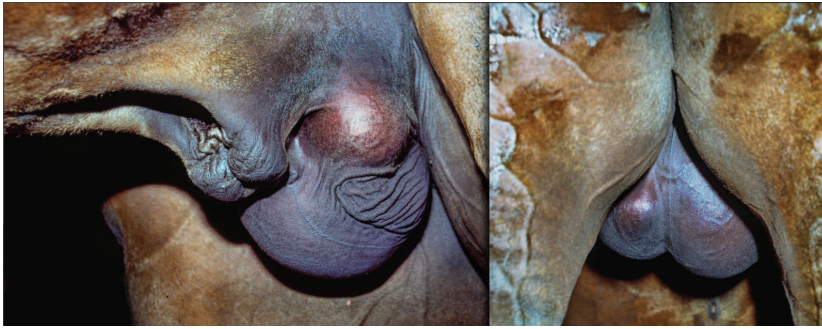


Figure 41, 42: Hydrocele

A hydrocele (Figure 41) is the result of an accumulation of sterile, amber-coloured fluid in the vaginal sac. It can appear months to years after castration and appears as a

nonpainful, fluctuant scrotal swelling (Searle, et al. 1999). It can often be reduced by squeezing the fluid back into the abdominal cavity or by drainage, but this only alleviates the situation temporarily. Treatment is only necessary if the hydrocele increases in size, aesthetically displeases the owner or becomes inconvenient for the horse. A hydrocele may give the impression that the stallion is entire (Figure 42), or that an inguinal hernia is present. If treatment is indicated, the horse is anaesthetized and placed in dorsal recumbency and the sac is transected as proximal as possible. The wound can be sutured or left open to heal by secondary intention (Schumacher 2006). The open method of castration predisposes horses to this condition, as the parietal tunic is not removed. Hydrocele occurs most likely in mules (Schumacher 1996).

12.10 Continued masculine behaviour

Incomplete removal of testicular tissue, presence of heterotopic testicular tissue, production of high concentrations of androgens from the adrenal gland, incomplete cryptorchid castration and psychological reasons can be the cause of continued masculine behaviour (Searle, et al. 1999). About 20-30% of geldings may still display sexual behaviour, especially during spring and



Figure 43: Continued masculine behaviour

summer, such as genital investigation, erection, mounting and even copulation (Searle, et al. 1999). Those geldings are referred to as “false rigs” (Schumacher 2006). Where continued masculine behaviour (Figure 43) is excessive of the castration history is unclear, hormonal

testing (see chapter “monorchidism”) can be used for the establishment of testicular tissue (Searle, et al. 1999).

12.11 Respiratory infection

Tracheal intubation, inhalation anaesthesia and stress associated with the changed environment in clinics can contribute to post-operative respiratory infections. An increased tendency for young horses to get respiratory infections is noticed, which may be due to the better immune system in older horses. (Kummer, et al. 2009). This complication is probably not only confined to castrations but definitely will not occur in standing castrations performed on the field but is a characteristic of surgical procedures performed under general anaesthesia.

12.12 Self-evaluating questions

36. What is true for postoperative swelling?
 - a. It is a pathological tissue reaction
 - b. It occurs right after surgery
 - c. It is mainly caused by inadequate wound drainage
 - d. It is life-threatening

37. What is the most common source of severe postoperative haemorrhage?
 - a. The testicular artery
 - b. The testicular vein
 - c. Superficial subcutaneous vessels
 - d. The femoral artery

38. What is the safest way to manage postoperative haemorrhage?
 - a. Re-crush the cord with an emasculator
 - b. Apply a haemostat proximal to the bleeding vessel
 - c. Pack the scrotum with sterile gauze and apply a pressure bandage
 - d. Put the horse in general anaesthesia, search for the bleeding vessel and ligate it

39. What is true for evisceration?
 - a. Mainly caused due to congenital hernia
 - b. Occurs within 4 hours after surgery
 - c. It is a surgical emergency
 - d. All of the above

40. What is true for protrusion of omentum?
- It is a surgical emergency
 - Can be treated by transecting the protruded omentum
 - It is absolutely necessary to suture the inguinal ring
 - All of the above
41. At what time does scirrhus cord becomes clinically apparent?
- Immediately after castration
 - A few days after castration
 - Months or years after castration
 - Pathological finding at necropsy
42. Postcastration septic peritonitis
- Is considered septic when nucleated cell counts of the abdominal fluid exceed 10,000 cells/ μ l
 - Is more likely to result from the open technique of castration
 - Is usually inflammatory and self-limiting, but sepsis should be suspected if degenerative neutrophils and phagocytized bacteria are evident on cytologic studies
 - Does not occur because the vaginal tunic does not communicate with the abdomen
43. Hydrocele is
- Common complication of the closed technique of castration
 - A result of infection of the spermatic cord
 - The accumulation of serous fluid within the vaginal cavity
 - More common following the open technique of castration
44. Persistent masculine behaviour after castration
- Results from failure to remove the epididymis during castration
 - Can result from failure to remove testicular tissue during castration of a cryptorchid animal
 - Does not occur
 - Can be due to psychological reasons

13. Conclusion

Castration in stallions is a common surgical procedure in equine veterinary practice. As with all surgical procedures, a profound knowledge of the surgical anatomy is imperative to a successful surgery. There is a high number of procedural variations at the surgeon's disposal. Therefore, a professional knowledge of the various surgical options and its associated advantages and disadvantages will allow the surgeon to apply the optimal surgical choice for each individual patient.

There is no perfect technique or approach available, which is suitable for every situation. The veterinary surgeon has to decide in every single case, which method suits the best for the particular patient and surrounding.

If the horse is castrated in a sterile environment in a hospital a closed technique with a scrotal or inguinal approach is suggested. The open technique should be avoided as it increases the chance of an intestinal prolapse. It is advised to use a transfixation ligature after applying the emasculator. To ensure security of the ligation, never put a ligature over the cremaster muscle. If a quicker and cheaper castration is intended, a standing castration with the open technique can be performed. However, it is not advised to perform a standing castration in donkeys, zebras and ponies.

In case of a cryptorchid stallion the parainguinal approach is suggested. The vaginal ring is left intact, the aponeurosis can be easily sutured and the parainguinal approach permits a good exploration of the abdomen in case of an abdominal retained testicle.

Although surgical castration of the stallion is a common surgical procedure, it is also associated with a significant degree of post-surgical complications. It is essential that the equine surgeon is aware of the potential complications, their severity, and treatment measures that can be performed to treat, but also prevent, these complications.

14. Acknowledgements

I am using this opportunity to express my gratitude to everyone who supported me throughout the course of this Doctoral Thesis. I am grateful for their aspiring guidance, invaluable constructive criticism and friendly advice during this work. I am sincerely grateful to them for sharing their truthful and illuminating views on a number of issues related to the project.

I express my warm thanks to Dr. Gábor Bodó, whose encouragement, guidance and support enabled me to develop an understanding of the subject.

15. References

15.1 Literature references

Bergin, WC, Gier, HT, Marion, GB, et al. "A developmental concept of equine cryptorchidism." *Biology of Reproduction* **3**: p. 82-92 (1970).

Cox, JE. "Cryptorchid castration." In *Equine reproduction*, by McKinnon, AO and Voss, JL, Philadelphia: Lea and Febiger: p. 915-920 (1993)

Cox, JE, Edwards, GB and Neal, PA. "An analysis of 500 cases of equine cryptorchidism." *Equine Vet J* **11**: p. 113-116 (1979)

Dowsett, KF, Thsewang, U, Knott, LM, Jackson, AE and Trigg, TE. "Immunocastration of colts and immunospaying of fillies." *Immunology and Cell Biology* **71**: p. 501-508 (1993)

Dyce, KM, Sack, WO and Wensing, CJG. *Textbook of Veterinary Anatomy*. Philadelphia: Saunders: p. 324 (2002)

Dyson, S. "Review of 30 cases of peritonitis in the horse." *Equine Vet J* **15**: p. 25 (1983)

Hayes, HM. "Epidemiological features of 5009 cases of equine cryptorchidism." *Equine Vet J* **18**: p. 467-471 (1986)

Hendrickson, D. "Laparoscopic Cryptorchidectomy and Ovariectomy in Horses." *Vet Clin Equine* **22**: p. 777-798 (2006)

Hunt, RJ. "Management of complications associated with equine castration." *Compend Contin Educ Pract Vet* **13**: p. 1835-1973 (1991)

Hunt, RJ, and Boles, CI. "Postcastration Eventration in horses: eight cases." *Can Vet J* **30**: p. 961-963 (1989)

Kilcoyne, I. "Equine castration: A review of techniques, complications and their management." *Equine Veterinary Education* **25**: p. 476-482 (2003)

Kilcoyne, I, Watson, JL and Kass, PH. "Incidence, management and outcome of complication of castrations in equids: 324 cases (1998-2008)." *JAVMA* **242**: p. 820-825 (2003)

Kummer, M, Gyax, D, Jackson, M, Bettschart-Wolfensberger, R and Fürst, A. "Results and complications of a novel technique for primary castration with an inguinal approach in horses." *Equine Vet J* **41**: p. 547-551 (2009)

Mair, T, Love, S, Schumacher, S, Smith, R and Frazer, G. *Equine Medicine, Surgery and Reproduction*. Saunders (2013)

Malmgren, L, Andresen, O and Dalin, AM. "Effect of GnRH immunisation on hormonal levels, sexual behaviour, semen quality and testicular morphology in mature stallions." *Equine Vet J* **33**, p. 75-83 (2001)

Mason, B, Newton, J, Payne, R and Pilsworth, R. "Costs and complications of equine castration: a UK practice-based study comparing "standing nonsutured" and "recumbent sutured" techniques." *Equine Vet J* **37**: p. 468-472 (2005)

Moll, HD, Pelzer, KD, et al Pleasant. "A survey of equine castration complications." *J Equine Vet Sci* **15**: p. 522-526 (1995)

Nickel, R, Schummer, A and Seiferle, E. *The viscera of the domestic mammals*. Berlin, Hamburg: Paul Parey (1979)

Nickels, FA. "Complications of castration and ovariectomy." *Vet Clin North Am (Large Anim Pract)* **4**, 1988: 515-523.

Palmer, SE. "Castration of the horse using primary closure technique." *Proc Am Assoc Equine Pract* **30**: p. 17-20 (1984)

Parks, AH, Scott, EA, Cox, JE and Stick, JA. "Monorchidism in the horse." *Equine Vet J* **21**: p. 265 (1989)

Price, J, Eager, RA, Welsh, EM and Waran, NK. "Current practice relating to equine castration in the UK." *Research in Veterinary Science* **78**: p. 277-280 (2005)

Rijkenhuizen, AB, and Grinwis, GC. "Castration of the stallion: Preferably in the standing horse by laparoscopic techniques?" *Pferdeheilkunde* **16**: p. 425-429 (1999)

Samper, JC, Pycock, JF and McKinnon, AO. "*Current therapy in equine reproduction*". Elsevier, (2007)

- Sanz, MG, Sellon, DC, Cary, JA, Hines, MT and Farnsworth, KD. "Analgesic effects of butorphanol tartrate and phenylbutazone administered alone and in combination in young horses undergoing routine castration." *Journal of the American Veterinary Medical Association* **235**: p. 1194-1203 (2009)
- Schanbacher, BD and Pratt, BR. "Response of a cryptorchid stallion to vaccination against luteinising hormone releasing hormone." *Vet Rec* **116**: p 74-75 (1985)
- Schumacher, J. "Complications of castration." *Equine Vet Educ* **8**: p. 254-259 (1996)
- Schumacher, J. "Surgical disorders of the testicle and associated structures." In *Equine Surgery* by JA Auer, JA, p. 674-703. Philadelphia: Saunders, (1992)
- Schumacher, J. "Testis." In *Equine Surgery*, by Auer, JA, Saunders, (2006)
- Schumacher, J, Schumacher, J and Spano, JS. "Effects of castration on peritoneal fluid constituents in the horse." *J Vet Intern Med* **2**: p. 22-25 (1988)
- Searle, D, Dart, AJ, Dart, DM and Hodgson, DR. "Equine castration: review of anatomy, approaches, techniques and complications in normal, cryptorchid and monorchid horses." *Aust Vet J* **77**: p. 428-434 (1999)
- Shoemaker, R, Bailey, J, Janzen, E et al. "Routine castration in 568 draught colts: Incidence of evisceration and omental herniation." *Equine Vet J* **36**: p. 336-340 (2004)
- Smith, JA. "The development and descend of the testis in the horse." *Vet An* **15**: p. 156-161 (1975)
- Stickle, RL, and Fessler, JF. "Retrospective study of 350 cases of equine cryptorchidism." *J Am Vet Med Assoc* **172**: p. 343-346 (1978)
- Swift, PN. "Castration of a stallion with bilateral abdominal cryptorchidism by flank laparotomy." *Aust Vet J* **48**: p. 472-473 (1972)
- Turkstra, JA et al. "Effects of GnRH immunization in sexually mature pony stallion." *Anim Reprod Sci* **86**: p. 247-259 (2005)

Turner, AS and McIlwraith, CW. "*Techniques in large animal surgery.*" Second edition. Wiley Blackwell (1983)

Turner, RMO. "Testicular Abnormalities." In *Current Therapy in Equine Reproduction* by Samper JC: p. 195-204. Saunders (2006)

Valdez, H, Taylor, TS, McLaughlin, SA and Martin, MT. "Abdominal cryptorchidectomy in the horse using inuinal extension of the gubernaculum testis." *J Am Vet Med Assoc* **6**: p. 1110-1112 (1979)

Voermans, M, Rijkenhuizen, ABM and Van der Velden, MA. "The complex blood supply to the equine testis as a cause of failure in laparoscopic castration." *Equine Vet J* **38**: p. 35-39 (2006)

Wilson, DG and Reinertson, EL. "A modified parainguinal approach for cryptorchidectomy in horses: An evaluation in 107 horses." *Vet Surg* **16**: p. 1-4 (1987)

Wilson, DG, Hendrickson, DA and Degrave-Madigan, AJ, Cooley, E. "Laparoscopic methods for castration of equids." *JAVMA* **209**: p. 112-114 (1996)

Wilson, JF, and Quist, JF. "Professional liability in equine surgery." In *Equine surgery* by Auer, JA, p. 13-35. Philadelphia: Saunders (1992)

Wissdorf, H, Bartmann, CP, Gerhards, H and Harps, O. "Männliche Geschlechtsorgane mit Hodenhüllen und Harnröhre." In *Praxisorientierte Anatomie und Propädeutik des Pferdes* by Wissdorf, H, Gerhards, H, Huskamp, B and Deegen, E, p. 705-744. Hannover: M. & H. Schaper Alfeld (2002)

15.2 Figure references

Figure 1: General physical examination (picture by Luzia Klauser)

Figure 2: Testicular descent into the scrotum of the horse foetus (http://images.slideplayer.de/1/633841/slides/slide_19.jpg, retrieved: November 23rd 2014)

Figure 3: Male sexual organs (retrieved from Cornell University)

Figure 4: Tunics (Nickel, Schummer, Seiferle; "*Lehrbuch der Anatomie*", Parey, 9. Auflage, 2004, p. 348)

Figure 5: Testis and cremaster muscle (retrieved from Cornell University)

Figure 6: Lateral view of the right testis of a stallion (Dyce; "Textbook of Veterinary Anatomy", Saunders, 3rd edition, 2002, p. 185)

Figure 7: Genital organs (Auer&Stick; "Equine Surgery", Elsevier, 4th edition, 2012, p. 805)

Figure 8: Schematic drawing of the testicular descent; High dorsal position of the testicle (Smith, JA; „The development and descend of the testis in the horse.“ Veterinary Annual, 1975: p. 156-161)

Figure 9: Schematic drawing of the testicular descent; Descent of epididymis and gubernaculum (Smith, JA; „The development and descend of the testis in the horse.“ Veterinary Annual, 1975: p. 156-161)

Figure 10: Schematic drawing of the testicular descent; Testicle takes place in scrotum (Smith, JA; „The development and descend of the testis in the horse.“ Veterinary Annual, 1975: p. 156-161)

Figure 11: Sand's castration clamp (Nuss, K; "Veterinärmedizinische Instrumentenkunde", Schattauer, 1998, p.167)

Figure 12: Bertschy's emasculator (Nuss, K; "Veterinärmedizinische Instrumentenkunde", Schattauer, 1998, p.168)

Figure 13: Reimer emasculator (Nuss, K; "Veterinärmedizinische Instrumentenkunde", Schattauer, 1998, p.168)

Figure 14: Improved White's emsculator (<http://www.medplusmedicalsupply.com/white-improved-emasculator-12-305-cm-miltex-6000-SS>, retrieved: August 2nd 2014)

Figure 15: Verboczy emasculator ([http://www.enasco.com/product/C13669\(X\)N.jpg](http://www.enasco.com/product/C13669(X)N.jpg), retrieved: December 2nd 2014)

Figure 16: Henderson's castration tool (<http://www.stonemfg.net/our-brands/stone-brand-products/castrating-instruments.html>, retrieved: November 3rd 2014)

Figure 17: Henderson's castration tool (Kilcoyne, I; "Equine castration: A review of techniques, complications and their management", Equine veterinary education, 2013)

Figure 18: Surgeon's position in standing castration (picture by Dane Tatarniuk)

Figure 19: Castration in field with rope restraint (picture by Luzia Klauser)

Figure 20: Castration in clinic in dorsal recumbency (picture by Luzia Klauser)

Figure 21: Removal of the testis using an emasculator (Turner and McIlwraith's; "Techniques in Large Animal Surgery", Wiley Blackwell, 4th edition, 2013, p. 143)

Figure 22: Primary wound closure (picture by Gábor Bodó)

Figure 23: Stretching of the incision (picture by Dane Tatarniuk)

Figure 24: Scrotal approach (Turner and McIlwraith's; "Techniques in Large Animal Surgery", Wiley Blackwell, 4th edition, 2013, p. 141)

Figure 25: Pushing the testicle cranial over the region of the external inguinal ring (picture by Luzia Klauser)

Figure 26: Bleeding vessels are cauterized (picture by Luzia Klauser)

Figure 27: Closure with simple continuous pattern (picture by Gàbor Bodó)

Figure 28: Laparoscopy in a standing horse (<http://cdn.thehorse.com/images/cms/2014/05/laparoscopic-castration-use-only-with-33950.jpg?preset=feature.jpg>, retrieved: November 15th 2014)

Figure 29: Ligated ductus deferens (Saifzadeh et al.; "Evaluation of "section-Ligation-Release (SLR)' Technique devised for castration in the stallion", *Reproduction of Domestic Animals*, 2008)

Figure 30: Cryptorchid Miniature Horse with the left testicle retained in the inguinal canal (picture by Luzia Klauser)

Figure 31: Inguinal approach (Auer&Stick; "Equine Surgery", Elsevier, 4th edition, 2012, p. 824)

Figure 32: Parainguinal approach (Auer&Stick; "Equine Surgery", Elsevier, 4th edition, 2012, p. 827)

Figure 33: Flank approach (Turner and McIlwraith's; "Techniques in Large Animal Surgery", Wiley Blackwell, 4th edition, 2013, p. 203)

Figure 34: Laparoscopic removal of an abdominal cryptorchid testicle in standing position (picture by Gàbor Bodó)

Figure 35: Postoperative swelling (picture by Gàbor Bodó)

Figure 36: Haemorrhage from the scrotal vessels (picture by Gàbor Bodó)

Figure 37: Evisceration after the castration (picture by Gàbor Bodó)

Figure 38: Protrusion of omentum (picture by Gàbor Bodó)

Figure 39: Scirrhus cord (picture by Gàbor Bodó)

Figure 40: Penile damage (<http://loriequinesection.blogspot.ch/2013/11/penile-injury-keywords-penis-injury.jpg>, retrieved: November 14th 2014)

Figure 41: Hydrocele (<http://loriequinesection.blogspot.ch/search?q=hydrocele.jpg>, retrieved: November 13th 2014)

Figure 42: Hydrocele (<http://loriequinesection.blogspot.ch/search?q=hydrocele.jpg>, retrieved: November 13th 2014)

Figure 43: Continued masculine behaviour (<http://images.fineartamerica.com/images-medium-large/lusitano-stallion-carol-walker.jpg>, retrieved: November 15th 2014)