

Faculty of Veterinary Science, Szent István University

Department of Anatomy and Histology

Diploma-thesis

**The importance of the relationship between the farrier and veterinarian with
particular insight into club foot, navicular syndrome and laminitis**

written by

Edward Busuttil

tutor

Dr. Balázs Geric

Dept. of Anatomy & Histology

Budapest, 2014

Contents

Introduction and Aim	1
Breakover	2
Hoof length.....	4
Hoof angle	4
The centre of rotation.....	6
Kinematics of the hoof	7
Kinematics of Breakover	9
Kinematics of Landing.....	111
Kinematics of Standing.....	11
The effect of shoeing interval on kinematics	11
The importance of proper shoeing.....	13
Trimming	14
Fitting the shoe.....	15
Applying the shoe	15
Nails	16
Number.....	16
Height of exit of the nails	16
Nail size.....	17
Shoes.....	18
Weight	18
Thickness	18
Length.....	19
Width of the web	19
Calks	19
Toe grabs	20
Shoe application	20
Club foot.....	21
Grading the club foot.....	22
Club foot in foals.....	23
Congenital.....	23
Acquired	23
Clinical signs.....	23

Treatment.....	23
Mature horses	25
Treatment.....	26
Therapeutic Farriery	26
Surgical treatment.....	29
Mismatched feet	30
Navicular syndrome	31
Medical therapy.....	33
Surgical treatment	34
Therapeutic farriery	35
Laminitis	37
Radiology of laminitis.....	37
Venography of laminitis	40
Treatment	42
Medical treatment.....	43
Cryotherapy	43
Avoiding pasture associated laminitis.....	44
Endotoxaemia therapy	45
Vasodilator therapy.....	45
Free radical scavengers	45
Farriery treatment of laminitis	45
The trim	45
Foam sole support.....	46
The Steward clog.....	47
Hoof wall resection	48
The heart bar shoe	49
Heel elevation	511
The Equine Digit Support System (EDSS).....	522
The surgical option - Deep flexor tenotomy	533
Preventing laminitis in the contralateral limb.....	533
Discussion.....	544
Conclusion and Summary.....	64
Acknowledgements	666

Bibliography.....	677
List of Figures.....	77

Introduction and Aim

The horse must support its body weight and dynamic loads on its coffin bones, a load which is then transmitted to the ground via the hoof capsule. A small part of the forces applied during weight-bearing are directed from the fetlock to push the coffin bone down and forward whereas a larger force is directed vertically downward from the coffin bone and is transmitted by the deep digital flexor tendon to cause the tip of the bone to be pulled down (Hood, 1987). The hoof capsule is deformed during the stance phase of the stride, resulting in a horizontal separation of the heels (Thomason et al., 1992), a bowing-in of the dorsal hoof wall (Newlyn et al., 1998) and a vertical compression of the hoof wall (Davies, 1997). Any changes to the conformation of the hoof capsule result in a change in this interaction with the ground.

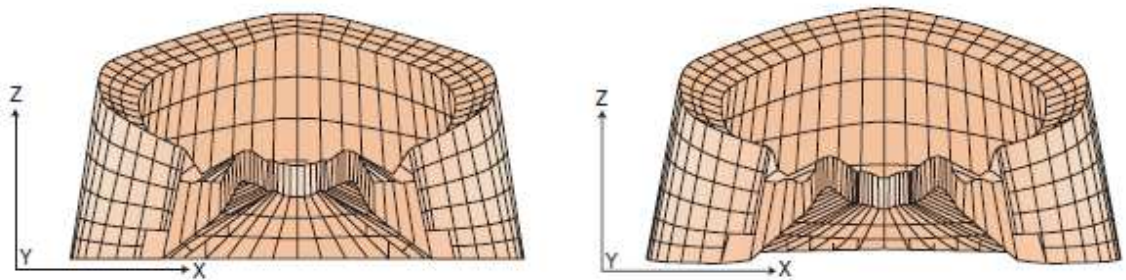


Fig 1: This rear view of a finite element model of the hoof capsule shows the structure in an unloaded (left) and loaded (right) state, showing that the force is spread over the area of contact of the laminar junction. (Thomason, 2007).

Balancing and shoeing the hoof affects the mechanics of the hoof and farriers can hence help to distribute the load properly (Balch et al., 1995). The ability of farriers has a predominant influence on the geometric balance of the hoof (Kummer et al., 2009). This balance is the shape of the hoof that improves performance without affecting the long term athletic stability of the horse (Balch et al., 1997). Small changes in basic measures of hoof shape including concavity, toe length, proximal hoof circumference and sole length can alter the hoof's center of mass (Arabian et al., 2001) whereas changes in hoof angle can affect the moments around the coffin joint (Moleman et al., 2006). Hoof shape is also significantly affected by the farrier's work

(Malone & Davies, 2011). It is hence essential for the veterinarian and farrier to work in tandem to construct a hoof which functions in a natural way to promote proper and painless movement of the horse.

Over the course of this literature review I will look into the kinematics of the stride to understand how the horse would like to roll its foot, what the farrier aims to achieve whilst trimming and shoeing a horse. Further I will mention three common disorders of the hoof (club feet, navicular syndrome and laminitis) and indicate the importance of collaboration between veterinarian and farrier to amend the problems faced.

However, first, I believe that it is essential to understand some of the quintessential properties of the foot.

Breakover

This is the part of the stride from when the horse lifts its heel off the ground to when its toe is almost in the air, acting as a pivot in the process due to the stretching of the deep digital flexor tendon. Just prior to breakover, the impar and suspensory ligaments of the distal sesamoid (navicular) bone are under maximal stress (Clayton, 1990).

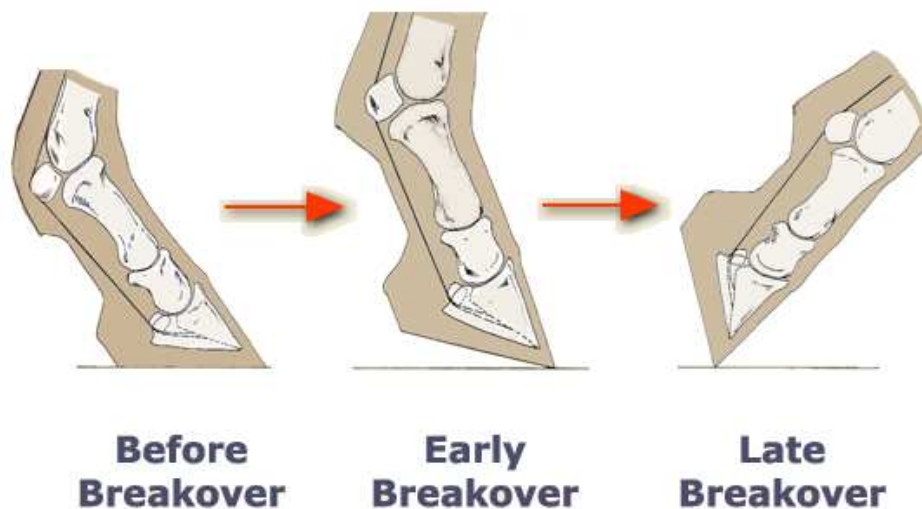


Fig 2: The phases of breakover and effect on the deep digital flexor tendon (Atlanta Equine Clinic, n.d.)

It could also be described as the 'most dorsal location of the solar aspect of the hoof capsule that contacts the ground' and is 'the last part of the hoof capsule to leave the ground during the caudal phase of the stride' (Page & Hagen, 2002).

Page and Hagen also speak about a breakover distance which influences the moment of inertia. They say that this distance is from the centre of the articulation of the coffin joint to the actual point of breakover.

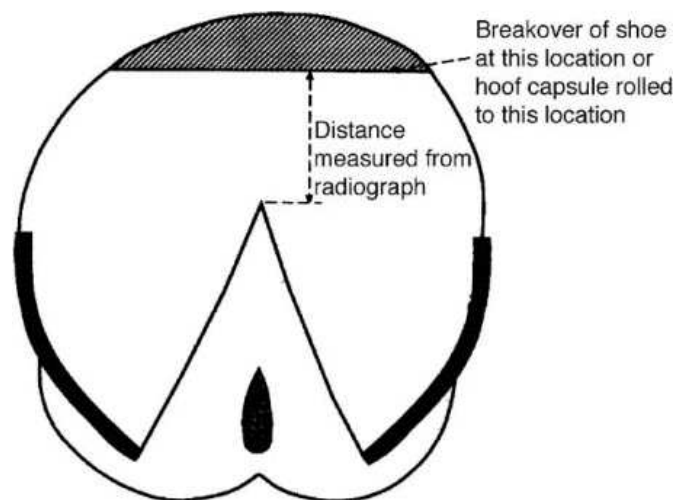


Fig 3: Diagram of breakover location on sole measured from a radiograph (Page & Hagen, 2002).

Their studies showed that breakover was made easier when the navicular bone is moved into a more proximal position hence decreasing the weight bearing capacity of this bone and the distance between the insertion and origin of the navicular ligaments as well as improving the blood supply to the navicular bone (Ratzlaff & White, 1989).

Changes in breakover occur due to the alterations of sole of the hoof which influence the hoof length, angulation, hoof-pastern axis and centre of rotation. These could be altered during shoe fitting, choosing the ideal shoe or trimming of the unshod hoof.

Hoof length

The distance at the toe between the dorsal-most part of the hoof reaching the ground to the horny wall of the coronary band is known as the hoof length (O’Grady & Poupard, 2003). The guidelines of this are on a basis of the weight of the horse (Turner, 1992):

Horse size	Horse weight (kg)	Toe length (cm)
Small	360-400	7.60
Medium	425-475	8.25
Large	525-575	8.90

Excessive toe length could result in lamina tearing – especially near to the coronary band - due to the stronger tension exerted by the deep digital flexor tendon as well as increased breakover time as the long toe acts as a long lever, needing more time and this raised tension (O’Grady & Poupard, 2003).

Hoof angle

This is the angle in between the foot’s ground surface and its dorsal wall and this angulation should ideally be parallel to the heel wall and a line drawn through all 3 phalanges (O’Grady & Poupard, 2003). This is individual for a specific horse and it is known as the hoof pastern axis. The normal axis includes a straight alignment between the dorsal hoof wall and dorsal pastern region. Trimming of the foot is hence essential as it cannot be achieved if the toe is too long or short or if the hoof is too high or low at the heels (O’Grady & Poupard, 2003). This will in turn improve the alignment between the second and third phalanges to keep the hoof pastern axis straight (Gibson & Stashek, 1990).

The angles of the shoulder and hoof capsule and coffin bone should be parallel to each other to aid the horse in distributing its weight evenly. Ideally, the hoof angle should be 54° for the forelimbs and 58° for the hindlimbs (Woodford, 2009).

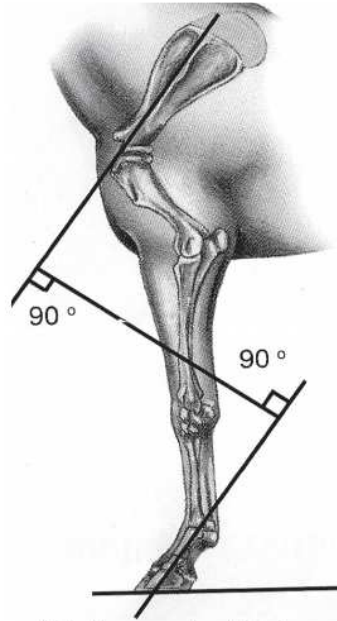


Fig 4: Relation of shoulder and hoof capsule angle (Woodford, 2009).

A high hoof angle results in a 'broken-forward' hoof-pastern axis. This leads to coffin joint flexion, heel-first landing and increased heel pressure which may result in coffin joint inflammation, sole bruising and increased straining of the navicular bone's suspensory ligaments (O'Grady & Poupard, 2003). This condition is known as club foot.

A low hoof angle as a result of long toe or under run heel would lead to the pastern moving forward (O'Grady, 2003) which would in turn cause extension of the coffin joint and lead to toe-first landing due to the increased strain on the deep digital flexor tendon (O'Grady, 2003). This is termed as a 'broken-back' hoof pastern axis. It will result in navicular syndrome as the deep digital flexor tendon increases its pressure on the navicular bone (Pool et al., 1989), heel bruising due to chronic pain, coffin joint inflammation, quarter and heel cracks (O'Grady & Poupard, 2003) and arthritis of the coffin joint (Ostblom et al., 1982). This pain is also linked with a delay in breakover speed. Studies have also shown that this type of navicular disease could decrease the blood flow to the heel (Colles, 1983). Broken-back hoof pastern axis has an incidence of 72.8% in forelimbs of lame horses (Wright & Douglas, 1993).

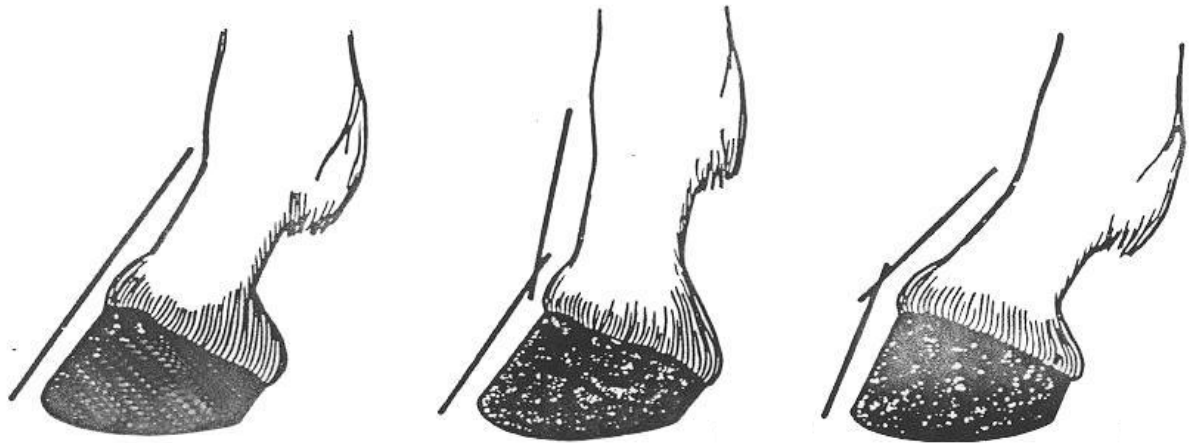

Fig 5: Straight (left), broken-back (centre) and broken-forward (right) hoof-pastern angle (O'Grady, 2003).

The centre of rotation

In a healthy foot, following trimming, a line drawn vertically from the centre of the middle phalanx's lateral condyle to the ground should divide the foot's bearing surface into two equal parts (Colles, 1983). The line would signify the distal interphalangeal joint's centre of rotation and coincide with another line drawn through the middle third of the frog across the solar surface which would also signify the foot's widest part (O'Grady & Poupard, 2003).

Kinematics of the hoof

The effects caused by prolonged mediolateral imbalance are visible to the eye in the form of cracks and sheared heels. However, the human eye, with a temporal resolution of approximately 24 Hz cannot detect slight changes in the distribution of pressure during gait. Other techniques have been introduced to eliminate this human error, like those listed below.

1. High frequency cinematography was used to understand differences in hoof wall angulations on stride kinematics (Clayton, 1990).
2. Force plates and in-shoe force techniques allowed for studies of the effect of imbalance upon the ground reaction force and point of zero moment (Barrey, 1990; Wilson et al., 1998; Wilson et al., 2001; Eliashar et al., 2002)
3. Dynamically calibrated force plate data has also been used to get detailed information about the centre of pressure whilst moving (van Heel et al., 2004).
4. Radiography gave information regarding the effects of imbalance on hard structures within the hoof, particularly the phalangeal alignment and changes to joint spaces (Caudron et al., 1998a; Caudron et al., 1998b)

In order to understand the kinetics of breakover, it is essential to understand basic principles of biophysics.

- Ground reaction force (GRF) is the force exerted by the ground against a body in contact with it based on Newton's 3rd law of Motion, that there is an equal and opposite reaction, in this case to the weight of the horse. It can be measured with a force plate.
- The point of zero moment (PZM) is the center of pressure which is the point of application of the GRF.
- Moment is the perpendicular distance from an axis to the line of action of a force. The moment arm hence determines the quality of the torque and it changes with the angle of application of the force (angle of insertion). By adjusting the angle of application and moment arm, you can change the force vector components and increase the amount of

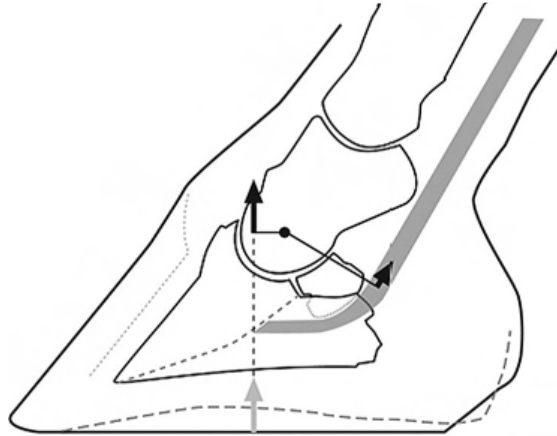


Fig 6: Whilst resting, the GRF (grey arrow) is dorsal to the centre of rotation of the distal interphalangeal joint to create an extensor moment which is opposed by the equal and opposite flexor moment created by the deep digital flexor tendon to keep the foot stationary. (Parks, 2012)

compressive force to maximize stability. The torque itself is what creates biomechanical movement as it is the driving force for movement. Being able to manipulate the torque will allow for a more specific intervention.

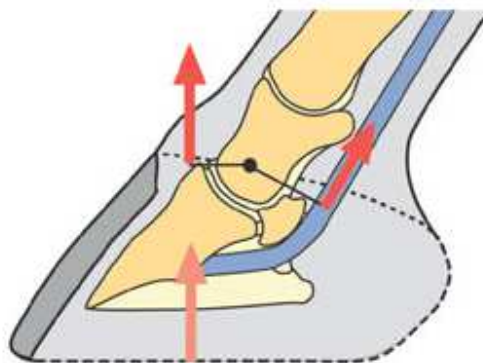


Fig 7: The moment created on either side of center of articulation (moment = force x length) (O'Grady, 2009).

Kinematics of Breakover

Studies show that feral horses load most of their weight on 4 concentrated points of their hoof wall (Ovniczek et al., 1995). The two dorsal points create the breakover line approximately 2.5-4.0 cm cranial to the frog's apex. This led to the development of the 4 point trim which supposedly advances breakover and decreases the forces in the deep digital flexor tendon (Redden, 1998). Heel wedges also reduce the maximum deep digital flexor tendon force as well as the distal interphalangeal joint moment (Willemen et al., 1999). As the point of zero moment (PZM) is moving forward, the heels are slowly unloading. When it reaches the toe, the extending moment will fall off in line with the Ground reaction force (GRF) as the distal interphalangeal (DIP) joint moment arm cannot increase further so as the heels leave the ground, the flexing moment exceeds its extending counterpart, resulting in flexion of the DIP joint (Eliashar et al., 2002). The study of Eliashar et al. (2002) showed that pulling the toe back reduced the moment arm on the DIP joint but did not reduce the DIP joint moment.

The deep digital flexor tendon (DDFT) exerts a force which is proportional to its length to act as a linearly elastic spring as it is loaded by means of the accessory ligament and muscle's parallel elastic component (Jansen et al., 1993).

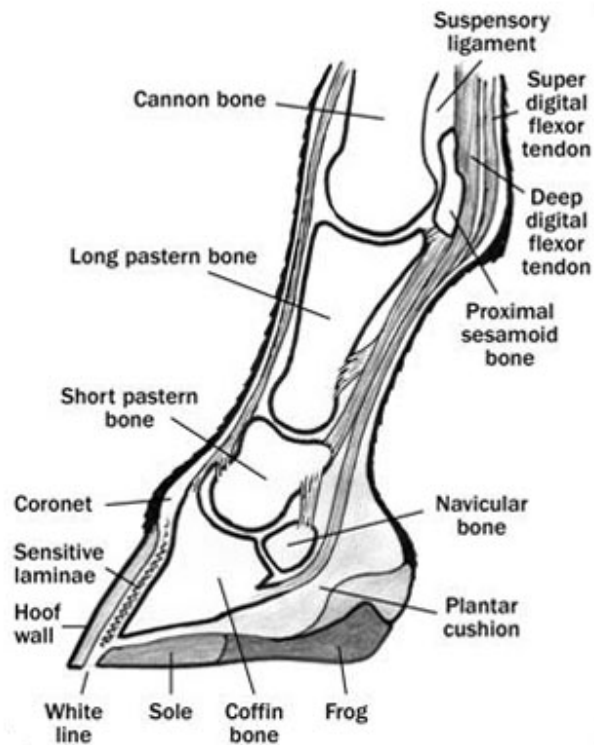

Fig 8: Side view of the foot (Sendel & Thomason, 2012).

This balances the extensor moment created by the GRF on the DIP joint as the DDFT runs over the navicular bone to form a moment arm which in turn flexes the DIP joint (Bartel et al., 1978) with the compressive forces on the navicular bone peaking at about 85% of stance (Willemen et al., 1999; Wilson et al., 2001). This DDFT force peaks after midstance but before the heels leave the ground at about 60-65% of stance (Willemen et al., 1999; Wilson et al., 2001) as it extends the metacarpophalangeal and DIP joints through stance as it is being stretched. After midstance, the vertical GRF and therefore the MCP joint angle decrease, however the DIP joint continues to increase until the heels leave the ground. The DDFT force peak occurs before the peak compressive force on the navicular bone because the compressive force is also proportional to the angle of deviation of the DDFT around the bone which increases through late stance as the DIP joint is being extended (Willemen et al., 1999). Reducing the DDFT strain and force as the DDFT shortens will decrease the angle of deviation around the navicular bone to further unload it. From this, it is possible to deduce that pulling the toe back

would reduce the force on the navicular bone as the heels would leave the ground at a lower angle of DDFT deviation (Eliashar et al., 2002), however the extent of this could not be proved with kinematic studies (Clayton et al., 1991; Eliashar et al., 2002).

Kinematics of Landing

In the Van Heel et al. (2004) study, the researchers used a high resolution pressure measurement system with 2.6 sensors per cm² which were equally distributed all over the plate with a temporal resolution of 240 Hz, ten times that of the naked eye. They showed that lateral asymmetrical landing was preferred in both the front and especially hind limbs both before and shortly (40-60 minutes) after trimming aimed at complete symmetry. Before trimming, 63.3% of all measured landings were located laterally and this reduced to 57.8% afterwards. In the hindfeet, the value reduced from 97.8% to 96.7%.

From this, it is possible to see that trimming distributes load more equally in an individual which is theoretically an advantage especially in distributing the high frequency vibrations which occur during landing (Balch et al., 1988; Benoit et al., 1993).

Kinematics of Standing

A study by Colahan et al. (1993) of recently trimmed, unshod hooves of the front limbs was carried out to determine the centre of pressure whilst standing using a pressure sensitive film in a specially built cassette. In 76% of the cases, the center of pressure was located in or on the borders of the medial heel (Colahan et al., 1993).

The effect of shoeing interval on kinematics

The growth of the hoof in between shoeing sessions will lead to a change in hoof conformation as the dorsal wall lengthens and the hoof angle decreases. Shod horses cannot compensate for these changes as the shoe does not change much unless excessive wear occurs. The position of the centre of pressure could be calculated using the hoof morphometric parameters of the new and old (at the start and end of the shoeing interval) dorsal hoof wall

length and hoof angle, as well as the GRF. This mathematical calculation (assuming that the P3 remains equidistant from the dorsal hoof wall), would result in expectations of a decrease in hoof wall angle and a shift of the centre of pressure (and navicular bone) towards the palmar/ plantar direction (van Heel et al., 2005).

In their experiment, van Heel et al. (2005) located the centre of pressure at midstance in Warmblood horses (the same horses used in the van Heel et al. (2004) study) 2 days after and 8 weeks after the horses were trimmed towards a straight hoof-pastern axis and shod with flat iron shoes (front feet shod with 1 toe clip and hind feet with 2 side clips). The newly shod horses' centre of pressure was generally found in the mediodorsal quadrant in the front feet but in the laterodorsal quadrant in the hind feet. After 8 weeks, the centre of pressure shifted in the palmar/ plantar direction and in the hind feet, the preference for the laterodorsal quadrant became more popular at midstance.

In the front feet, the displacement measured was only 60% of the calculated displacement and 0.5 cm was left unaccounted for. According to the researchers, this could be explained by the fact that the shoe's became rounded as a consequence of wear, resulting in the breakover point shifting towards the palmar/ plantar direction as opposed to being a fixed point like in the calculation. Alternatively, the difference could have been due to the alteration in strain of the deep digital flexor tendon or change in limb placement (Jansen et al., 1995; Crevier-Denoix et al., 2001).

In the hind feet, the discrepancies were of 80%, with 1.1 cm left unaccounted for. Although the same compensatory mechanisms can be accounted for in the hind limbs, they have not as yet been accounted for. On the other hand, there could also be another compensatory mechanism due to the increase of lateral shift in toe off after the 8 week period. Due to the strong rounding off of the dorsal hoof wall in the hind feet, the lever arm at toe off is shortened, resulting in better compensation and hence decreased loading at the initiation of breakover leading to less frequency of navicular disease in the hind feet (van Heel et al., 2005).

The importance of proper shoeing (Moyer & Anderson, 1975)

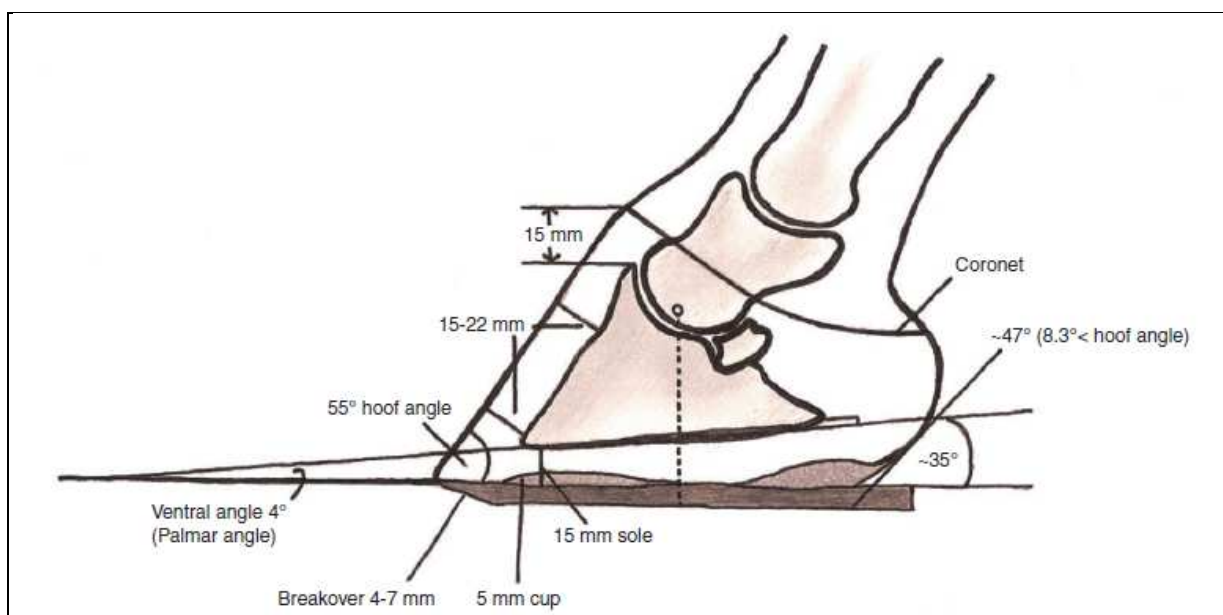


Fig 9: Lateromedial schematic view of 'normal' front foot of a healthy horse, with variations depending on the size of the horse (Mansmann & Vom Orde, 2007).

The importance of good farriery is obvious for the well-being of horses and their athletic performance and a large proportion of lameness can be prevented or treated through good farriery. By making small changes in toe length, proximal hoof circumference and sole length, it is possible to change the center of mass of the hoof (Arabian et al., 2001) and changes in the hoof angle can change moments around the coffin joint (Moleman et al., 2006). Both hoof trimming and farrier significantly affect the variables of hoof shape (Malone & Davies, 2011). The aim of trimming and shoeing the foot is threefold (O'Grady, 2003).

1. To ease breakover by moving the point of it in a palmar/ plantar direction to shorten the lever arm which the toe creates. This changes the tensile force in the deep digital flexor tendon, slightly moves the navicular bone in a more proximal direction and changes the hoof-pastern axis.

2. To protect the sole and wall which in turn protects and supports the structures lying under it and bears some weight at the hoof wall. The sole should be concave as this increases its weight bearing capacity.

3. To ease the impact of landing and stance on the palmar/ plantar part of the foot by supporting the heels. Low, forward heels allow the majority of the foot mass to be dorsal to the center of rotation of the distal interphalangeal joint, putting more stress on the palmar/ plantar soft-tissue structures of the foot, particularly the distal aspect of the deep digital flexor tendon and then navicular bone's suspensory apparatus (Moyer & Anderson, 1975; Reimersma et al., 1996).

Another important aspect to keep in mind is medial/ lateral balance. Proper balance will help to ensure that there are no excess abnormal forces on soft tissues and joint surfaces that could lead to injury during training or competition. By evenly distributing the weight through the joints of the leg in conformation with the leg, abnormal tension on the soft tissue support structures, particularly the collateral ligaments of the joints and branches of ligaments and tendons which insert onto the bone at a parasagittal angle can be avoided (Denoix, 1999).

Trimming and horseshoes are hence essentially influencing how the limb responds to the initial impact of landing. If the horse's feet are not well prepared, the musculoskeletal system will struggle and eventually fail.

Although each case must be considered individually, three essential components predetermine the success of the farrier; trimming, shoes and their application (O'Grady, 2003).

Trimming

This is the most important part as the farrier must create the base, depending on a visual examination of the foot, especially the conformation, the hoof pastern axis and the widest part of the foot located under the centre of rotation. Loose and exfoliating material is removed from the frog, sole and bars, with the base of the frog, beside both sulci, also trimmed to ease cleaning. The sole is also stripped at the white line to judge how much of the hoof wall needs to be removed using the hoof nippers, starting from just in front of the heels. The heels should not be shorter than the frog's ground surface and the frog should ideally be level with the heel wall.

Finally, removing a thin layer of the sole at the sole-wall-junction ensure that sole pressure does not build up.

Studies by Kummer et al. (2009) showed that there are significant differences between different farriers and between their own consecutive trims, resulting in large discrepancies between the external parameters which make up the shape of the foot (Kummer et al., 2009).

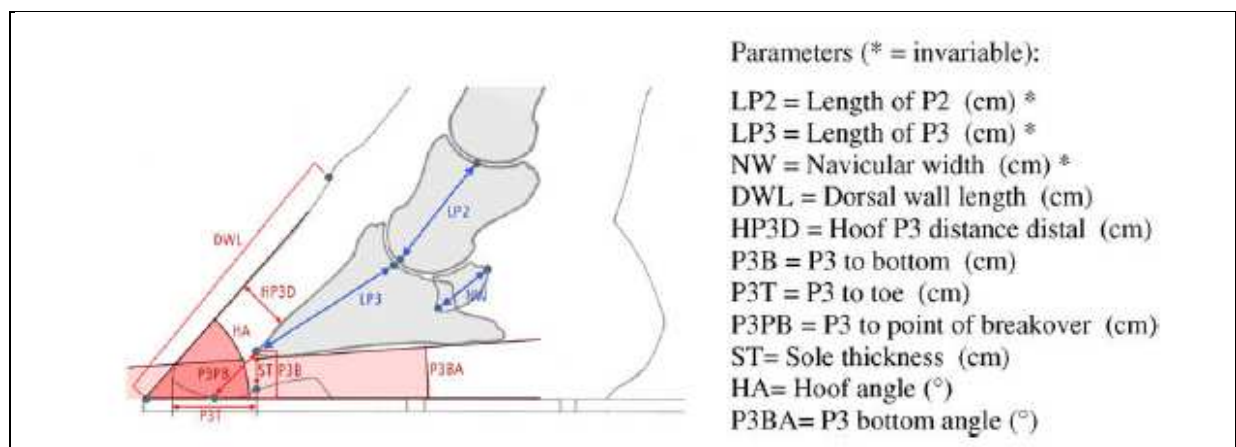


Fig 10: This schematic lateromedial view indicates which parameters (red) can be influenced by the farrier during a trimming session (Kummer et al., 2009).

Fitting the shoe

The lightest and simplest shoe which gives the hoof adequate traction, support and protection should be used. Since the shoe is a kind of extension of the foot, it needs to be properly fitted onto the trimmed outline of the foot. The shoe should be long enough to cover the buttress of the heel (angle between the wall and bar) and support the leg. If the foot is trimmed properly and the centre of rotation is at the widest part of the hoof, this area should be equidistant between the toes and heels of the shoe. If this is not equal in the unshod foot, a lengthened shoe can be used.

Applying the shoe

Nails are still the most common method of applying shoes and it is important to use the smallest and fewest number of nails possible. They should be inserted in such a way as not to

interfere with foot movement, hence forward of the widest part of the foot. If the foot is still very sensitive, glue on shoes may be applied.

Nails

- **Number**

The presence of the right number of nails (usually six) is essential. Have too little and the shoe is not properly attached to the foot but too many and although the shoe is more secure, the natural hoof expansion is diminished, resulting in the shoe's position not following the growth of the hoof. Having any nails at all decrease the ability of the hoof to expand and in fact, there is an increased outward expansion immediately following the removal of shoes as there is more pressure on the frog and solar structures (Newlyn et al., 1998). This is essential in the foot's mechanism of maintaining soundness by reducing the concussive forces on the bare hoof.

The overuse of nails is usually due to the factory-made shoe needing too many nails (eight). This results in the nails being too close together and the heel nails sometimes being too far back. This issue can be fixed by filling the already present nail holes and repunching new ones to suit the horse's requirements, handmaking a shoe with three adequately placed nail holes on each branch of the shoe, using just three out of the four available holes or by using clips at the toe or on the side to secure the shoe and stop it from shifting position.

- **Height of exit of the nails**

Nails which exit too low from the hoof could result in splitting or torn hoof walls or loose shoes. This could be a significant problem when reusing the shoe and using the same holes that were previously used, further weakening the wall. If the horses must be reshod with the same shoe, the farrier should repunch the nail holes and redirect smaller nails.

In scenarios where nails exit too high, there is an increased risk that they could be at the inset very close to sensitive tissue, resulting in intermittent or constant lameness and/ or pain, due to the presence of a 'hot' nail. Removing the nail which is causing discomfort usually alleviates the problem though an abscess may develop.

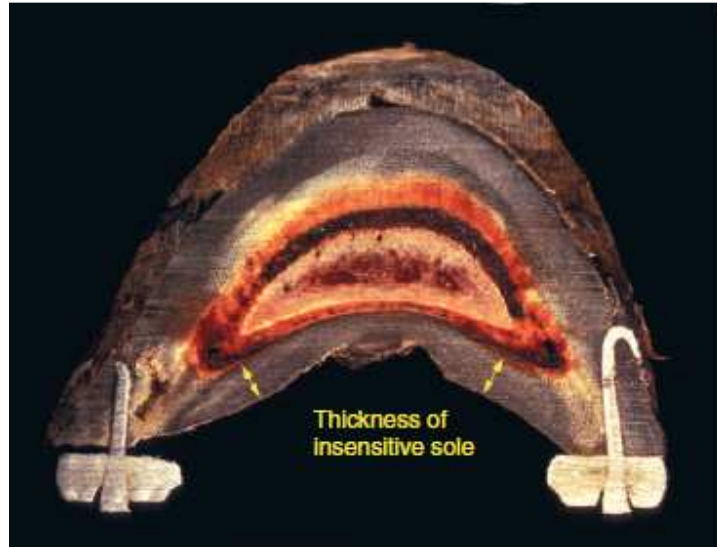


Fig 11: A frontal section through the frog's apex shows the thickness of the insensitive sole (Balch, 2007).

- Nail size

There is less chance of splitting the hoof wall or being close to sensitive tissue with a smaller and thinner nail. Unfortunately, shoes manufactured in factories generally require larger nails, especially in the case of smaller shoes, resulting in the dimension and direction of the hole being the same for all sizes. Since the holes direct the nail in a way which is perpendicular to the web of the shoe, there is a greater risk of damage to the sensitive part of the hoof, especially with regards to the heel nail. This last nail can cause quarter and heel cracks, contracted heels and pricking. This is especially true for the inside heel nail due to the generally thinner and straighter wall of the medial quarter heel region. The manufactured shoe may also be problematic in the way that the heel nail goes beyond the bend of the quarter and the shoes should be repunched as it would otherwise slow down proper heel and foot expansion.

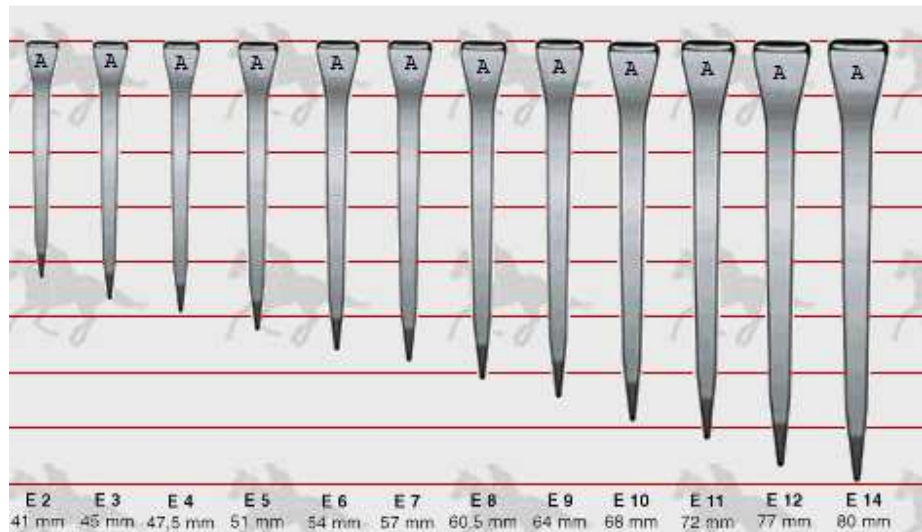


Fig 12: European Standard nails available for purchase (Arry International, 1999).

Shoes

The shoes act as extensions of the hoof capsule to prevent the solar surface of the epidermal structures from wearing out and the solar corium from bruising. Deciding which shoe to apply should depend on the function of the horse. Increasing traction with calks in jumping horses or decreasing it with sliding plates for reining horses is an important consideration. They can also be used to increase the weight-bearing surface to redistribute the ground forces acting on the limb in cases of abnormal conformation.

- **Weight**

Heavier shoes can increase fatigue, decrease agility and exaggerate gait, especially if it is abnormal. The lightest possible shoes for should be utilized.

- **Thickness**

The thickness (height of the web) is important as the shoe or shoe pad should not decrease the total available ground surface of the foot. This would concentrate the impact of energy to a smaller area, increase dorsiflexion in the fetlock and ventraflexion in the coffin joint, hence increasing the work load and total joint rotation. The hoof mechanism to absorb pressure at the frog will obviously be missing if there is no ground-contact of the frog due to a shoe which is too thick.

- Length

The shoes length can be measured from the toe's tip to end of the branches. The shoes are often too short on the forelimb and hence do not extend far back enough to support the heels. This is a common problem in race horses as trainers and owners are often afraid that the horse will “grab” a shoe with a hindfoot.

- Width of the web

Ideally, the web should make contact with the hoof wall, white line and some of the adjacent sole. Most manufactured shoes are not wide enough to properly protect the bottom of the foot.

- Calks

Calks improve a horse's balance and grip over uneven or slippery terrain, allowing the animal to move better and jump more confidently in poor footing.

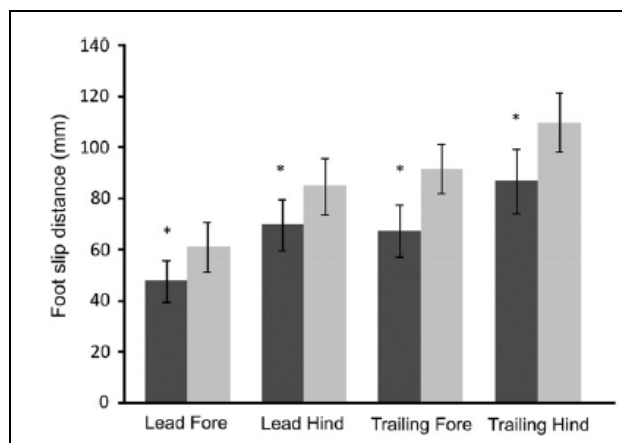


Fig 13: The graph shows the mean slip distance for each limb with (dark) and without (light) a lateral stud on each shoe, with all four limbs showing a significant decrease in mean slip distance in six horses cantering under their normal rider in a straight line on a grass surface (Harvey et al., 2012).

Problems associated with calks are more common when they have been forged onto the shoe, as opposed to when they are screw ins. Low in-line heel calks result in great traction without as many disadvantages as high calks.

- Toe grabs

Toe grabs are similar to calks in the way how they shorten ground contact. They also affect normal breakover if not positioned properly, resulting in abnormal wear of the grab and stumbling which can result in the horse scalping itself. Also, due to their position, the grabs can change the position of the foot in relation to the ground, hence altering the positions of the coffin and fetlock joints. If toe grabs really are necessary, the farrier should use a full rimmed/fullered shoe, decrease the height of the grab to a minimum and balance the entire foot to ensure that the grab is centered over the position of foot breakover.

Shoe application

Shoe application should result in evenly distributed impact of energy throughout the foot and limb. The most common problem is when the shoe rotates away from the ideal position which may result in sheared heels, corns, hoof cracks, P3 fractures, pedal osteitis and side bones amongst others. This happens due to improper balancing of the foot before the shoe is applied, misguiding the first nail, improper forging or when the inside branch is tucked to prevent grabbing. When a shoe is positioned in the ideal centre, a line which bisects the tips of the shoe's two branches should not be slanted. Otherwise, the heel on the shorter end would become the leading edge and contact the ground first during landing, as well as the side on which the horse breaks over, resulting in it taking up a bigger bulk of the ground reaction force.

Club foot (Floyd, 2007)

This is the flexor contracture of the coffin joint, resulting in prevention of normal joint extension and angle whilst standing due to a shortening of the deep digital flexor musculotendon (O'Grady, 2011), resulting in abnormal alignment of the distal phalanx in relation to the middle phalanx, resulting in variable mechanical changes in the foot. It is not possible to manually extend the coffin joint, even when the foot is elevated and relaxed. As the heels are raised off the ground, the horse bears its weight further forward, toward the toe, resulting in erosion of the distal-most part of the dorsal hoof wall.



Fig 14: The dished appearance of the hoof wall, typical for club foot (Schmotzer, 2011).

The deep digital flexor tendon bellies can be found on the palmar side of the radius, underneath the muscle bellies of the superficial digital flexor tendon and carpal flexors. The tendons of both of the digital flexors pass through the carpal canal and whereas the superficial digital flexor tendon inserts onto the 2nd phalanx, the deep digital flexor tendon continues distally to insert on the coffin bone. The accessory ligament is a strong tendinous band which comes from the deep palmar carpal ligament, fuses with the deep digital flexor at the midway level of the metacarpus. When this unit (the deep digital flexor and its accessory ligament) are shortened, the distal interphalangeal joint flexes. Although the hoof capsule is pulled with the coffin bone, the constant flexed position that horses with club foot are in, together with the weight being put on the affected limb, causes a quick distortion to the hoof capsule, characteristic to club foot.

Grading the club foot (Redden, 2003)

The most common system used to grade the club foot is based on the physical and radiographic appearance of the foot:

Grade 1: Hoof angle is 3-5° greater than that of the opposing foot. There is a characteristic fullness at the coronary band due to the partial luxation of the interphalangeal joint. Growth rings may be present, however these are equidistant apart at the heels and toe.

Grade 2: Hoof angle is 5-8° greater than that of the healthy foot. The heels do not touch the ground when trimmed to a normal length. Growth rings are wider at the heels than at the toe.

Grade 3: The dorsal hoof wall becomes dished and the growth rings may be twice as wide at the heel as they are at the toe. Radiographically, there is evidence of demineralization and microfractures along the apex of P3 due to the constriction of the circumflex and dorsal circulation of the abnormally orientated coffin bone.

Grade 4: The hoof angle is greater than 80 degrees, the coronary band is almost higher at the heel than at the toe and the dorsal hoof wall is highly dished. The radiographic image is similar to, but much more severe than, Grade 3 club foot. In extreme cases, the horse may be walking on the dorsal surface of the hoof wall.

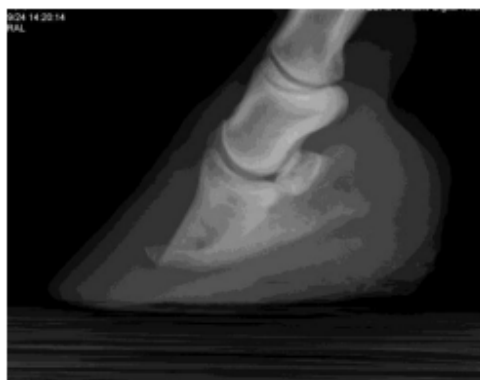


Fig 15: The shortening of the deep digital flexor tendon causes flexion at the distal interphalangeal joint.

Club foot in foals

Flexural deformities in foals can be split into congenital or acquired abnormalities (O'Grady, 2012; Adkins, 2008; Hunt, 2011; Kidd & Barr, 2002). Congenital deformities are present from birth whereas acquired ones usually occur during the first 6-8 months of life during development. It is more common in the forelimbs.

- Congenital

In congenital cases, the most often affected limb is the right fore. It is essential to differentiate between the natural steeper hoof wall angle in newborns and club foot.

- Acquired

The most common period for observing acquired coffin joint contracture in young foals is between 3 to 6 months of age; however, it can also begin within a few days of birth. A study which looked at how foals grazed showed that foals with short necks and long legs generally grazed with the same limb protracted (van Heel et al., 2006).

- Clinical signs of club hoof

As the upright foot is usually self limiting, lameness is not so severe and there is generally no abscessation. A toe cap can form from a composite if lameness is present and once the foot grows sufficiently, it will usually cease the problem. Appropriate farriery for foals with this toe cap involves trimming the hoof capsule and frog in such a way which keeps them on the same plane (O'Grady & Dryden, 2012).

- Treatment of club hoof

After proper evaluation of the foot in rest and motion, the angle and degree of hoof capsule distortion should be analyzed. Radiographs can confirm diagnosis and assess changes in the joint and the actual cause of the acquired club foot by carrying out a thorough history should be discovered.

In milder cases, conservative treatment by limiting the predisposing factors and administration of non-steroidal anti-inflammatories to reduce pain and oxytetracycline to help the muscles to relax, together with careful hoof trimming is a good start. Trimming should result in the lowering the heels until the hoof wall at the heels and frog are on the same plane. To promote spreading, the bars should be thinned or removed and the heels adjacent to the sulci should be angled at 45°. To improve breakover and move its point in a palmar direction, a mild bevel starting slightly dorsal to the frog's apex and extending to the perimeter of the dorsal aspect of the dorsal hoof wall should be rasped. This should be repeated every two weeks if improvements are noted, however, if the toe becomes bruised or starts to abscess, a hoof composite should be applied to the dorsal aspect of the hoof wall and sole (O'Grady & Dryden, 2012).

If it is severe, either as an acute onset or as a progression of a mild flexural deformity, the heels should be elevated. A wedged, glue-on cuff and extension shoes should be applied to foals younger than 8 months after the heels have been lowered to an angle of 50-55 degrees as this helps to reduce the tension in the deep digital flexor tendon. The duration of application and evaluation protocol are outlined in the discussion and, although uncommon, surgery may be required, especially in cases in which the club feet have become chronic or uncontrollable (Floyd, 2007). However, once the distal interphalangeal joint is markedly deformed (based on radiographic examination) and the hoof capsule is distorted, transaction of the accessory ligament of the deep digital flexor is recommended (White, 1995; Caldwell & Waguespack, 2011). Better results can be observed if the procedure is done before the horse is 1 year old (Caldwell & Waguespack, 2011). Afterwards, the heels should be lowered and if the dorsal aspect of the hoof wall is concave, it should be removed with a rasp. A composite mixed with fiberglass strands should be applied to the sole, initiating at the frog's apex and forming a thin lip at the perimeter of the hoof wall (O'Grady & Dryden, 2012). This composite should be molded into a 'reverse wedge' meaning that it should start at 0° at the apex and extend to 2-3° at the toe (Stone & Merritt, 2009). This protects the toe region and helps to redistribute the load to the palmar aspect of the foot, increasing stress on the deep digital flexor tendon and restoring the sole's concave nature.

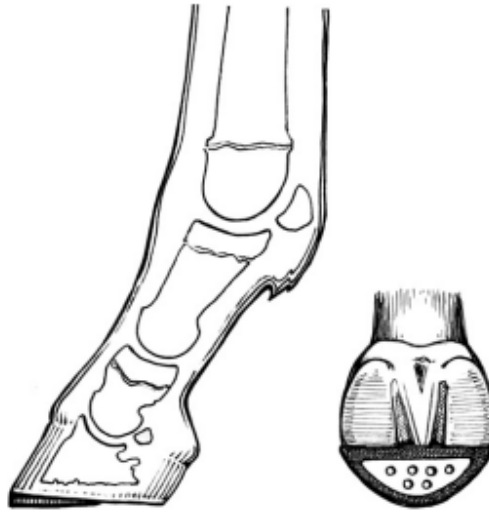


Fig 16: This drawing shows the lateral and ground surface view of the foot following trimming an application of reverse wedge made out of composite and aluminum (O’Grady & Dryden, 2012).

Mature horses

In mature horses, a foot with an upright conformation associated with a flexural deformity of the distal interphalangeal joint is called a club foot (O’Grady, 2011; O’Grady, 2012; O’Grady, 2008). These horses usually have a flexural deformity whilst they are still immature which is mistreated. Exacerbation of the deformity during training or inadequate farrier care can result in club foot conformation, secondary to another underlying disease. This results in decreased athletic ability and chronic, low-grade lameness (Turner & Stork, 1988; Balch et al., 1995). This results in more weight being loaded onto the dorsal section of the hoof and a decrease in sole growth rate, resulting in sole bruising, shorter strides on the affected limbs and poor performance.

The shortening of the deep digital flexor tendon resulting in elevated heels causes more growth at the heel than at the toe as a mode of compensation, causing the frog to recede. This results in the energy of impact bypassing the soft tissue structures and instead going directly to the hoof wall. This way, the load is directly transferred onto the phalanges via the laminae. Altogether, this results in the flexion of the coffin joint and the abnormal alignment of the coffin

bone, encouraging toe-first landing. Commonly seen hoof abnormalities in horses with a club-foot conformation are thin flat soles, poor hoof-wall consistency, toe cracks, hoof wall separation, white-line disease and chronic laminitis (O'Grady & Poupard, 2003). The high hoof angle could result in inflammation of the distal interphalangeal joint, sole bruising and increased strain on the navicular bone's suspensory ligament (Turner, 1992).

- Treatment of club hoof

The aim of treatment is to correct the alignment between the phalanges, and the therapeutic principles remain the same regardless of the grade of club foot (O'Grady & Poupard, 2003; O'Grady, 2009). Achieving normal alignment between all three phalanges will create normal orientation and loading of the coffin bone relative to the ground. Hence trimming and shoeing will help reduce the load which the toe must bear. Since the severity of the deformity is proportional to the shortening of the deep digital flexor tendon, lowering the heels would increase the tension in the unit which may lead to even more deformation of the hoof capsule, decrease sole depth, pedal osteitis, irreparable tearing of the dorsal lamellae and widening of the shoe wall junction (in a way similar to what happens in chronic laminitis) (Floyd, 2007).

- **Therapeutic Farriery of club hoof**_(O'Grady & Dryden, 2012)

Horses with club feet should be trimmed on a four-week schedule.

Horses with a high hoof angle (but not misaligned phalangeal bones) should have their foot trimmed mildly in a tapered way from the apex to the heels to increase the foot's ground surface, encouraging more of the foot to bear weight. Using a shoe with a rolling or rockering toe moves breakover backwards to compensate for the increased strain in the deep digital flexor tendon due to the lower heels created.

If a flexural deformity is also present, the farrier has 3 roles; to load the heels, improve the hoof-pastern axis and compensate for the shortened deep digital flexor tendon. In mild cases, the foot's toe should be placed on the thick side of a 2-3° pad and the horse allowed to stand on it. If there horse doesn't mind the tension placed on the deep digital flexor tendon, the

farrier can trim the hoof wall safely in a tapered way from the toe or widest part of the foot, using the thickness of the pad as a guide.

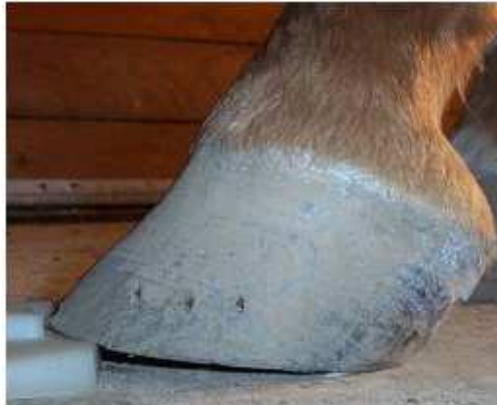

Fig 17: A wedge pad placed under the foot's toe can be used to estimate the amount of heel which can be trimmed away without too much stress on the deep digital flexor tendon (O'Grady & Dryden, 2012).

The toe can then be shortened by rasping the outer surface of the dorsal hoof wall.

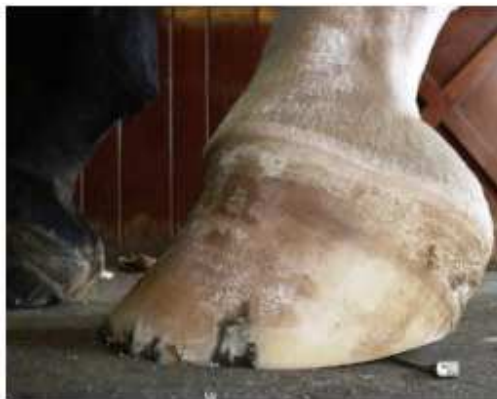

Fig 18: Placing the trimmed foot palmar to the contralateral limb gives a good indication of how much the muscle tendon unit has shortened, visible at the gap between the ground and heels (O'Grady & Dryden, 2012).

This trimmed hoof must then be shod into a handmade shoe which promotes breakover just dorsal to the frog's apex and tapers towards the toe to help decrease the tension on the deep digital flexor tendon. Radiographic studies are necessary especially when there is hoof-

capsule distortion, to ascertain how deep the sole is and how much of the toe can be removed to have this rocker in the shoe.




Fig 19: To compensate for the shortening of the deep digital flexor tendon described in Fig 18, a wedge shoe, degree pad or bar wedge should be placed between the heels of the foot and the shoe (O'Grady & Dryden, 2012).

Since the normal ground reaction forces and the load bearing structures are changed when the heels are elevated by a shoe, a pour-in pad or impression material should be applied to the sole to further share the load. If this is not done, the heels can become overloaded, possibly resulting in quarter cracks, contracted heels and subsolar bruising near the heel.

As most club feet have contracted heels, it might be useful to let the club foot expand in the shoe. However, this is risky as if the shoe is fully fit in the heels, the horse can pull it out. Since the hoof-wall may be so damaged due to club foot, the shoes may need to be directly glued on. When using glue, aluminum shoes are recommended due to their porous nature. Unfortunately, since glue on shoes are directly applied to the sole and weight bearing surface of the hoof wall, they due to not allow the natural re-expansion of the heels. Polyurethane shoes have been recently introduced as although they allow the heels to expand, they are also attached only with an adhesive.

- Surgical treatment of club hoof

A distal check ligament desmotomy can benefit horses which have not benefited from appropriate farriery (O'Grady, 2011; O'Grady, 2012; Turner & Stork, 1988; Floyd, 2007), particularly if they fall into the Grade 3 or 4 category. This would allow the coffin bone to realign with the rest of the digit and the distorted hoof capsule will be markedly improved (O'Grady & Dryden, 2012). It is also recommended to perform the surgery as early as possible, to prevent any radiographic changes in the coffin joint or on the coffin bone's margin and hoof capsule distortion which would later affect the athletic performance of the horse.

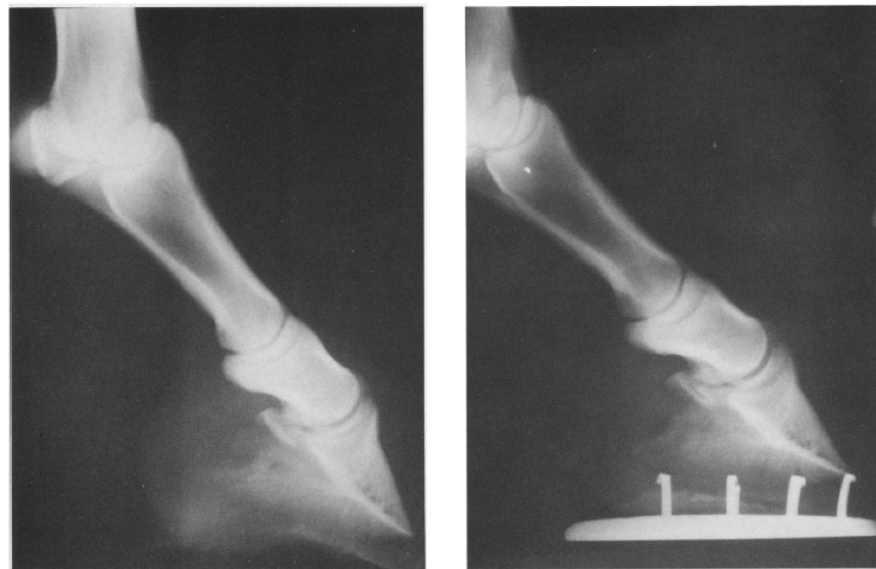


Fig 20: Pre- and post-surgical radiographs following transaction of the check carpal ligament in a horse with flexural deformity of the coffin joint (Tarr et al., 1993).

In mature horses general anesthesia or standing sedation with local analgesia can be used (Yiannikouris et al., 2011; Walmsley et al., 2001). If a standing procedure is used, elevating the heel with a 12° wedge will decrease the tension within the inferior check ligament and deep digital flexor tendon complex, to allow for easier recognition of the check ligament (O'Grady & Dryden, 2012). Due to the changes which the soft tissues endure because of the hoof capsule distortion, the hoof should be trimmed in moderation, depending on the radiographs. Two or

three 2° wedge pads need to be applied with a shoe or cuff and a pad needs to be removed every 7-10 days, depending on the horse's comfort level (O'Grady & Dryden, 2012). The horse should be walked daily following surgery, turned out into a small paddock three weeks later for a further three weeks and then turned out in a larger area for 3-6 months before normal exercise can be started (O'Grady & Dryden, 2012). Toe extensions are often contraindicated as they can cause increased mechanical force on the laminae.

Mismatched feet (O'Grady & Dryden, 2012)

Mismatched feet in cases in which one foot has a very high hoof angle or club foot often results in a shortened stride on that limb and the appearance of lameness. Sometimes, as the stride shortens, the contralateral limb may present to be lame due to overloading of the heel as it is forced to bear more weight and this may in turn result in chronic unilateral lameness.

Navicular syndrome

Caudal hoof lameness is the leading cause of chronic lameness in the horse (Colles, 1982) accounting for more than a third of all chronic cases (Turner & Fessler, 1982). This form of lameness can be improved by palmar digital analgesia and could hence originate from the entire sole, the navicular apparatus and soft tissues of the heel, the entire distal interphalangeal joint, the distal portion of the deep digital flexor tendon, the distal sesamoidean ligament and in some horses, to some extent, also the pastern joint (Moyer et al., 2007). These disorders can be split into conditions of the podotrochlear region, conditions of P3 and conditions of the hoof wall and horn-producing tissues (Turner, 2003).

Changes due to navicular syndrome have been recorded in athletic horses as young as 3 years of age and is commonly found in horses which are 8 years of age and older.

The most commonly found pathologic lesions in navicular syndrome are the erosions and thinning of the flexor fibrocartilage of the deep digital flexor tendon, however this is also often seen in symptomless horses (Colles, 1982; Drommer, 1993). The invaginations of synovial tissue into the navicular bone known as synovial fossae create a means of communication between the medullary cavity of the navicular bone and coffin joint.

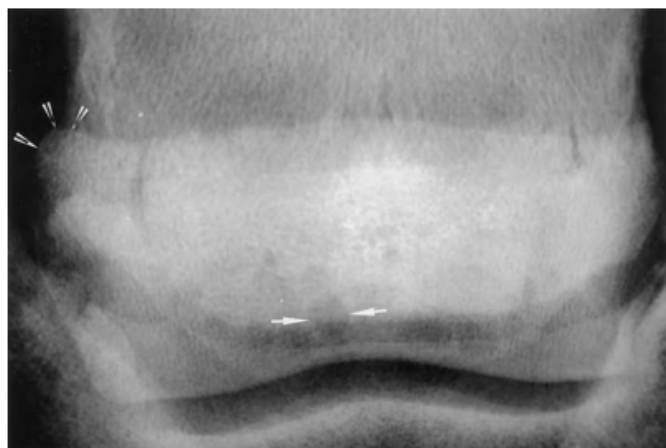


Fig 21: A dorsopalmar view of the navicular bone of a horse with navicular syndrome shows the lollypop-shaped synovial fossae on the distal border (arrows) and loss of the normal shape of the navicular bone due to enthesopathy of the extremity (arrowheads).

Tears along the insertion of the proximal navicular suspensory ligament and impar ligament into the navicular bone are represented by enthesiophyte formation (Pool et al., 1989; Wright et al., 1998). In other studies, it was noted that the flexor fibrocartilage and deep flexor tendon fray more noticeably in horses with navicular disease and the amount of flexor fibrocartilage wear is directly correlated with the amount of tendon damage (Drommer, 1993).

Although there is still no conclusive pathogenesis, a number of theories exist and a combination of these is possibly resultant in navicular syndrome. They can be separated into 3 categories: A) ischemia, B) biochemical stress or C) degenerative cartilage disease (Rooney, 1969; Colles, 1979; Stashak, 1987; Pool et al., 1989; Meier, 1993).

A) Ischaemia is a controversial theory as in one study, the distal nutrient arteries were occluded and no lameness or radiographic changes were recorded (Rijkenhuizen et al., 1989). This theory will be discussed further in the discussion.

B) The biomechanical theory has a further four ideas.

1. Adams put forward a concussion theory based on the repetitive pressure which the navicular bone exerts against the deep digital flexor during navicular bursitis (Stashak, 1987). The hyperemia caused by the bursitis leads to the decalcification of the navicular bone.
2. Rooney proposed that the flexor fibrocartilage is damaged and the deep digital flexor tendon degenerates due to the vibrations between the deep digital flexor and navicular bone during movement (Rooney, 1969). This is predisposed by hoof injury and bad hoof conformation. He goes on to suggest that out-of-phase rotations of the fetlock and coffin joints (resulting in toe-first hoof impact due to a broken back hoof-pastern axis with the ground) lead to a rise in the compressive force put onto the deep digital flexor tendon and navicular bone which consequentially increase friction between the two structures. Other studies have, however, indicated that only 25% of cases have broken back hoof-pastern axis (Turner & Stork, 1988).
3. Meier believed that sclerosis of the trabeculae of the navicular bone due to the active bone remodeling become worse with time, leading to a progressively worsening

lameness (Meier, 1993). Since the sclerotic bone is thickened and adynamic, it cannot accept stress. Meier admitted that he did not know why this happened.

4. Hertsch proved that horses with navicular disease have higher pressure in their distal interphalangeal (DIP) joint than normal horses (Hertsch, 1993). This was considered irrelevant until Turner recently showed that the DIP joint and navicular medullar cavity communicate (Turner, Unpublished Data, 1982-2005). The increased pressure in the joint leads to increased pressure within the bone and although the pressure in the joint could return to normal quickly, that in the bone took longer, causing trabecular remodeling.
- C) The third theory of degenerative joint disease claims that degeneration is caused by excessive and maintained compressive forces on the distal half of the navicular bone due to faulty conformation (Pool et al., 1989). The biomechanical stress causes remodeling of the bone especially when the stresses are larger than the physiological levels. This leads to the degeneration of the flexor surface of the fibrocartilage which changes the underlying bone, leads to edema and subsequent venous hypertension.

Medical therapy of navicular syndrome

Initial medical therapy of navicular syndrome consisted of a combination of hyaluronic acid (10-20mg) and triamcinolone (8mg) injected intraarticularly into the distal interphalangeal joint followed by another dose of hyaluronic acid in a fortnight in horses which respond to coffin joint anaesthesia (Turner, 1989; Trotter, 1991; Turner, 1996). If cartilage damage is also suspected, an intramuscular injection of polysulfated glycosaminoglycans (500mg) every four days for a month is also encouraged as it can inhibit synovial inflammation, raise the viscosity of the synovial fluid, increase the synthesis of cartilage components and decrease pain (Collier et al., 1993).

Vasoactive drugs are used for vascular forms of the disease. Although warfarin is not as popular as it once was as it could possibly cause hemorrhages, it improves the circulation to the podotrochlea as it raises the prothrombin time by 20-50%. It should be administered orally at 0.2mg/kg daily, Vitamin K1 should be constantly available to the horse and the drug should be

discontinued if no improvements are seen within eight weeks (Colles, 1982; Colles, 1979; Colles & Hickman, 1977; Colles, 1983).

The most common drug used to increase circulation to the podotrochlea is Isoxsuprine (Rose et al., 1983), though its oral availability is controversial (Matthews et al., 1986). It should be administered orally at a dosage of 1.2 mg/kg twice a day for two weeks, 1.2 mg/kg once a day during the third week and 0.6 mg/kg once a day for another week (Turner, 1989). If the horse becomes lame again after the fourth week, it should be administered at 1.2mg/kg once a day for the first week and eventually reduced to the minimum effective dose. Other drugs such as metrenperone (Turner, 1989) and pentoxifylline (Kirker-Head, 1993) also increase circulation; however they are not as efficient as isoxuprine.

Since 2003, the bisphosphonate drug group has been introduced to treat navicular syndrome as this drug group acts to inhibit osteoclast action and promote bone formation (Ramey, 2014). Tildren, which contains Tiludronate, is administered intravenously and it was the first bisphosphonate used for navicular syndrome. 0.1 mg/kg bodyweight should be administered slowly as an intravenous infusion in 1 L of 0.9% saline over 90 minutes for ten consecutive days to reduce the risk of adverse effects (Ceva, 2014). A new product released in 2014 is called Osphos which contains Clodronate and this is administered intramuscularly. 1.8 mg/kg up to 900 mg per horse should be administered into three different intramuscular sites and can be administered at three to six month intervals if clinical improvement is not maintained for more than six months (Dechra, 2014).

Surgical treatment of navicular syndrome

Surgery in vascular cases can come either in the form of a palmar digital neurectomy or fasciotomy of the palmar digital nerve. A palmar digital neurectomy is preferred as it causes a longer lasting vasodilation (Turner, 1989) whereas the fasciotomy may cause damage to the nerve whilst not lasting as long (Fricker et al., 1986). Although a neurectomy relieves pain by desensitizing the heel region, painful neuromas can develop, the deep digital flexor tendon can rupture due to necrosis and adhesions, infections could result in the loss of the hoof wall and

there could be painful sensation from aberrant branches of the nerve missed during surgery. There is also a possibility of the regeneration of the nerve (Asquith & Kivipelto, 1994).

If desmitis of the navicular suspensory ligament is thought to be the cause of pain, surgery is aimed at reducing strain on the ligament by either raising the horse's heels, performing a collateral sesamoidean desmotomy (Turner, 1989; Wright & Douglas, 1993) or inferior check ligament desmotomy (Turner, 1993) (Turner, 1993).

If navicular bursitis is the suspected cause, a podotrochlear bursa lavage to flush out any inflammatory debris is suggested (Turner, 1989).

Therapeutic farriery of navicular syndrome

Corrective balancing and shoeing is considered to be the starting point for care in patients with navicular syndrome. Decreasing the strain on the deep digital flexor tendon by increasing the dorsal hoof wall angle and shortening the toe length to decrease the forces acting on breakover is paramount (Lochner et al., 1980; Balch et al., 1991; Reimersma et al., 1996). Balancing the hoof in this way significantly increases carpal flexion (11°), vertical height of the hoof during the swing phase of the stride (5.6 cm), and fetlock range of motion (14°) but did not significantly change the duration of stance phase (Keegan et al., 1998). Shoeing must be done on a case to case basis to make the horse more comfortable and help it roll its toe with more ease. This can be done by raising the heels 2-4° and rolling the toe of the shoe to facilitate breakover and ease the tension on the deep digital flexor (Asquith & Kivipelto, 1994).

In other circumstances, a full bar shoe or pad could be used to decrease external pressure which might cause trauma to the frog and in one study, this resulted in 84% of the horses remaining sound for up to 54 months (Turner, 1989). Horses with underrun heels should be put onto egg-bar shoes and in one study, this resulted in 57% of treated horses remaining sound for 12-40 months (Ostblom et al., 1984).



Fig 22: This type of shoe provides protection and stability and reduces stress on the navicular bone (Dryden, n.d.).

Laminitis

Laminitis is still a relatively misunderstood disease as many predisposing factors can result in the development of this problem. Understanding these factors could help prevent it in horses at risk. These include horses suffering from equine metabolic syndrome, Cushing's disease, infection due to abscessation and distal limb edema, as well as horses living on a rich water soluble carbohydrate diet (Agne, 2010). Whilst the acute phase is the period of injury, the chronic phase is the period of recovery when the distal phalanx has been displaced within the hoof capsule due to the mechanical collapse of the lamellae (O'Grady, 2010).

Before treatment can start, the clinician must grade the laminitis based on foot pain, gait, the external pathologic hoof changes and radiographic findings:

- Grade 1: Mild foot pain but walks willingly, showing discomfort on tight turns. Circumferential rings may appear on the hoof wall as the wall grows down.
- Grade 2: Moderate pain and walks slowly, refusing to make tight turns. There may be circumferential rings on the hoof wall as it grows down. The sole may be bruised after a few trims.
- Grade 3: Severe pain resulting in the horse spending most of its time recumbent and walking with great reluctance, refusing to turn. There are initially no external changes.
- Grade 4: Extreme pain resulting in great difficulty standing and walking. There is a rotation of P3 resulting in rupture of the coronary band and sole penetration. Fatal sinker sole may also occur.(Floyd, 2007)

Radiology of laminitis (Pollitt, 2008)

The dorsal hoof wall should be parallel to the dorsal cortex of the distal phalanx. The major change of acute laminitis is the increased distance between the hoof wall and distal phalanx.

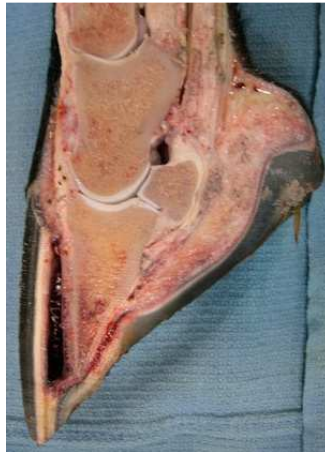


Fig 23: Picture showing the separation of the coffin bone from the dorsal hoof wall (Habecker, 2009).

Through radiology, it is possible to measure the hoof-distal phalangeal distance (HDPD) which is the distance between the outer hoof wall and upper surface of the distal phalanx. Since the HDPD never changes in normal horses, it is important to know that it is usually 16-18mm in horses weighing 400-450kg or 25% of the length of the palmar cortex of the distal phalanx (from the tip of the distal phalanx to the joint between the distal phalanx and navicular bone).

After cleaning the foot, it should be placed on a wooden box 10-15cm above the ground so that the x-ray beam can be successfully centered on the foot whilst it is kept parallel to the ground. A radiopaque marker should be stuck to the dorsal hoof wall and to the top of the wooden box.

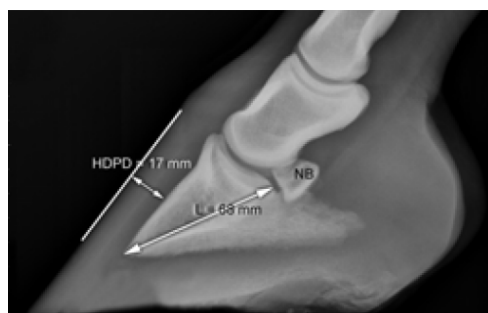


Fig 24: A lateromedial radiograph of a normal foot with a radiopaque mark to show the dorsal hoof wall to allow for more accurate measurements (Pollitt, 2008).

An HDPD increase of only 2-3mm is very important in early chronic laminitis as during the first few days, although the hoof wall and distal phalanx will remain parallel, they will draw apart. If the distal phalanx has started to rotate, it is indicative that approximately six weeks have passed since the onset of laminitis. Early recognition is hence essential for the eventual shoeing and care.

Apart from the lateromedial radiographs, a dorsoproximal-palmarodistal view in upright pedal position can be used to show the tip of the distal phalanx and indicate demineralization and progressive osteomyelitis. With a dorsoproximal-palmarodistal view in standing position, the veterinarian can look for radiolucent lines under the medial and lateral hoof walls which, if present, indicate extensive separation and contraindicate dorsal hoof wall resection.

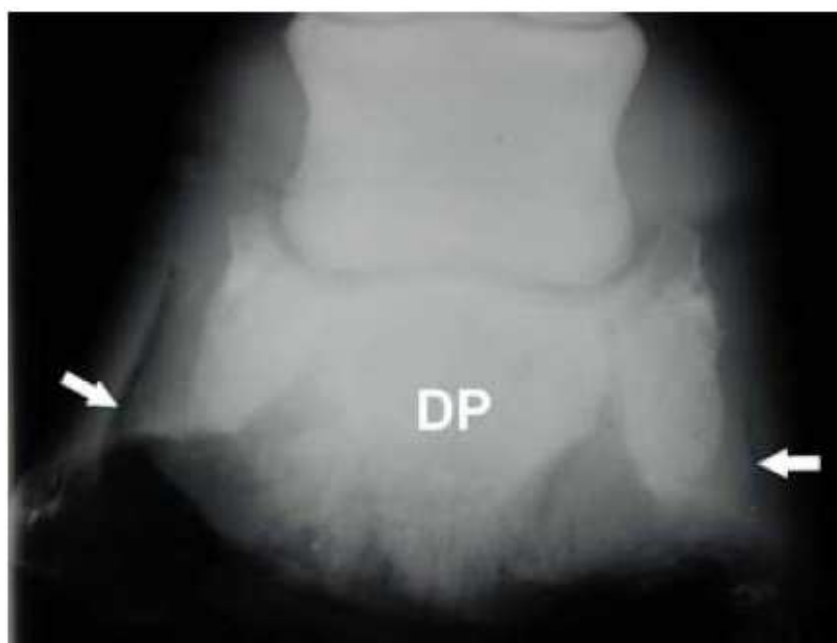

Fig 25: The arrowed radiolucent lines show that the coffin bone separated from the lamellae of the medial and lateral hoof wall in the dorsoproximal-palmarodistal 'standing' view (Pollitt, 2008).

As the condition becomes chronic and the distal phalanx sinks, separating further away from the hoof wall, its tip begins to compress the sole's corium, resulting in osteolysis of the tip

of the bone and necrosis of the sole, though these changes typically take five to six weeks to develop.

A dorsopalmar radiograph can be used to determine if asymmetric distal displacement of the coffin bone has occurred on the lateral or medial side. Ensuring that the ground is parallel to an imaginary line drawn through the foramens of the semi lunar canal can help to alleviate this concern (O'Grady, 2010).

Although radiographs are helpful, most veterinarians still believe that the Obel system of grading laminitis due to lameness grade is a better tool in predicting the final result. This is further supported by the good correlation between the extent of histological and lamellar damage and grade of lameness (Pollitt, 1996).

Venography of laminitis (Pollitt, 2008)

Since radiographs showed that all the veins below the mid-pastern region did not have any valves, complete retrograde filling with 20-25 ml of contrast media is possible. In chronic laminitis, ischaemic necrosis due to the damage of the integrity and structure of the coronary, sublamellar and solar circulation is possible.

Since the contrast material diffuses within minutes of application, good technique is essential in making good contrast x-rays. After sedating the horse, a radiopaque marker should be applied to the dorsal hoof wall and the medial and lateral sides of the pastern should be clipped and scrubbed as for surgery. A tourniquet in the form of an Esmarch rubber bandage should be applied around the fetlock to distend the digital veins. An indwelling 22G, 25mm catheter with a pre-attached un-capped extension tube should be inserted after the skin is cut down with a scalpel over the vein and this should then be taped down.



Fig 26: This image shows the venogram technique with the extension tube placed in the arrowed digital vein (Pollitt, 2008).

It is recommended to use two smaller syringes as opposed to a large one to insert the contrast media to be able to assert greater hydraulic pressure. As soon as the foot is positioned on a box and the contrast media is injected, the rest of the team must be ready to shout two high and low contrast laterals before quickly altering the equipments positioning to shoot horizontal dorsopalmar shots.

Venography has been used to detect changes in hoof anatomy within 5-7 days of the onset of laminitis (Baldwin and Pollitt, 2000). The severity and rate of changes correlated with the degree of lameness. Baldwin and Pollitt showed changes in three distances: the mean distance between the outer hoof wall and distal phalanx (A), the width of the sub-lamellar venous plexus (B) and the distance between the tip of the distal phalanx and the dorsal circumflex vessel (C).

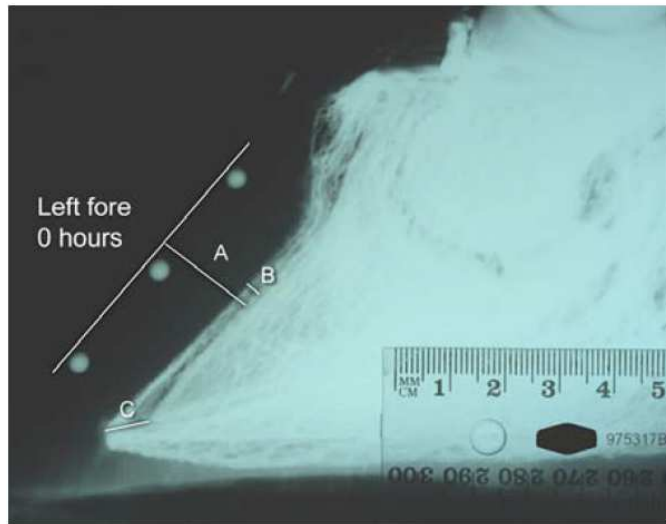


Fig 27: Venograph with all three points of measurement (Pollitt, 2008).

Experiments in nine pairs of front foot of horses with induced laminitis showed the following mean changes over a period of 42 days:

	A	B	C
Day 0	18.2 mm	3.0 mm	8.0 mm
Day 5 to 6	19.9 mm	4.5 mm	9.0 mm
Up to day 42	22.5 mm	5.4 mm	11.3 mm

After 7 days, there were already indications that the coronary plexus was damaged as it was not being filled as much as in the beginning of the experiment. The tip of the distal phalanx moved further away from the dorsal circumflex vessels as it was sinking away from the dorsal hoof wall and hence had a decreased blood supply which would eventually lead to ischaemic necrosis. Horses with severe laminitis developed progressively greater venographic changes.

Treatment of Laminitis

Since the lamellae cannot be directly reattached, mechanical function gradually returns in approximately nine months when an appropriate environment, rest (balanced against exercise required to regain normal hoof capsule function) and hoof care (Parks & O'Grady,

2008). In case of chronic laminitis, therapy is hence aimed towards stabilizing the coffin bone, decreasing pain and insuring that the new hoof is growing well in relation to the distal phalanx (O'Grady & Parks, 2008).

- Medical treatment of Laminitis (Pollitt, 2008)
 - Cryotherapy

Cryotherapy is a therapy in which the temperature of the foot is decreased to cause vasoconstriction and a hypometabolic effect. As the temperature is reduced, there is a decreased requirement for metabolites and oxygen from the healthy cells, enhancing their chances of survival during the ischaemia.

The protective effect of vasoconstriction during the developmental stage was first shown in 1998 (Pollitt & Davies, 1998). Further experimentation in 2004 proved this concept (van Eps & Pollitt, 2004). These researchers induced laminitis in six horses with an oligofructose overdose and immersed one forelimb into ice water for a 48 hour period within which the mean internal hoof temperature was maintained between 0.9-3.5 °C and although the untreated limbs developed signs of laminitis, the cooled limbs had reduced up-regulation of lamellar MMP mRNA and only minor histological changes. The second part of their study involved placing all four feet in an ice tub measuring 200cm by 80cm by 50 cm filled to a level just below the carpus. All horses were treated with polyionic fluids, plasma, antibiotics, NSAIDs, activated charcoal and paraffin oil as well as providing water and Lucerne hay ad libidum. They were kept in the ice bath for approximately 72 hours and although none of the horses were lame after this time, they had an elevated digital pulse for the following 24 hours. An equine diaper was used to prevent faeces and urine from contaminating and heating up the water.



Fig 28: Ice bath in stocks for elongated icing of the feet (van Eps & Pollitt, 2004)

- Avoiding pasture associated laminitis

Laminitis can be triggered by large amounts of fructan in the hindgut (Longland & Byrde, 2006). Reducing the concentration of water soluble carbohydrates (WSC) and preventing its consumption can greatly decrease the incidence of laminitis. Since the WSC of certain grass species can reach 56% of the dry matter of which up to 44% can be fructan, these species should be avoided. Production and accumulation of WSC is boosted by photosynthesis which peaks most in conditions of high light intensity and low ground temperatures, particularly during the afternoon and early evening in spring and autumn. Therefore, maintaining soil moisture and mowing or grazing to keep it short encourages leaf growth and WSC consumption (Watts & Chatterton, 2004). Shaded pasture and grazing during the early morning hence helps limit exposure to WSC.

Since most of the WSC are stored in the lower, pale green stems, grazing muzzles with holes that limit consumption to leafy tops are ideal. Ideally, horses should be fed hay made from a mature pasture made in summer. If this is difficult, soaking the hay in fresh water for sixty minutes and draining it before feeding it could remove about 31% of the soluble sugars (Watts & Chatterton, 2004).

- Endotoxaemia therapy

Horses with toxemia are at a high risk for laminitis and should be treated immediately. Including anti-endotoxin hyperimmune plasma in intravenous fluid therapy and reducing foot pain with NSAID administration are essential. Administering flunixin meglumine intravenously at a rate of 0.25 mg/kg TID or 1.1 mg/kg BID has shown to reduce prostaglandin production by inhibiting cyclooxygenase activity. 4.4 mg/kg BID oral or intravenous administration of phenylbutazone is generally preferred due to its low cost and long duration of therapy (approximately two weeks). Although the horses are more comfortable, NSAIDs will not stop the progression of laminitis.

- Vasodilator therapy

Although contraindicated in the developmental stage of laminitis, applying a patch to the pastern of glyceryl trinitrate during the healing phase may be beneficial.

- Free radical scavengers

A 90% solution of dimethylsulfoxide (DMSO) mixed with polyionic solutions and 5% dextrose administered slowly intravenously at a rate of 8 litres per hour is also said to be beneficial, however research into its effectiveness is not yet available. It is essential to maintain a DMSO concentration below 20% to decrease the risk of intravascular haemolysis.

- Farriery treatment of laminitis (Pollitt, 2008)

The descent and palmar rotation of the distal phalanx, solar prolapsed, osteomyelitis and pain all stem from the inability of the distal phalanx to remain attached to the inner hoof wall. Quick treatment can help to save lamellae and provide time for them to heal. Time is of the essence and the quicker therapeutic shoeing is carried out, the lower is the risk of irreversible damage.

- The trim

Realigning the ground surface of the hoof capsule with the distal phalanx's solar surface helps to restore the best possible anatomic relationship between the two structures. In healthy

horses, the angle between the hoof's ground surface and solar margin of the coffin bone is about 2-5° and the distance between the two properties is 15-20mm (O'Grady, 2010). Obviously, if the thickness of the dorsal sole is less than it is supposed to be, the hoof's ground surface cannot be realigned to the coffin bone's solar margin without further decreasing the sole's thickness. It is therefore only possible to trim the walls and sole palmar to the point where the distance is still greater than 15-20mm. Unfortunately, this often results in the formation of two different planes of orientation on the solar surface and an increase in tension in the deep digital flexor tendon as the heels are lowered. This must be taken into consideration during shoeing (O'Grady, 2010).

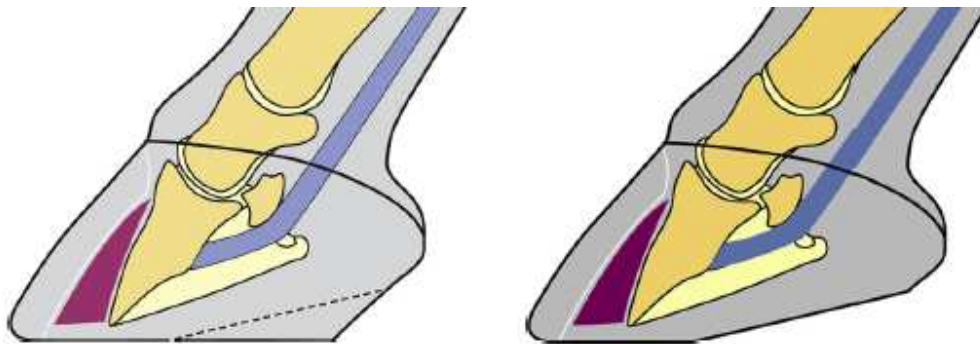


Fig 29: Two different planes are formed following farriery on the dorsal and palmar aspects of the ground surface (O'Grady, 2010).

- Foam sole support

Providing a foal sole allows the foundered horse to bear weight on its palmar two thirds of the foot and hence alleviate pain. Using a foam sole for the initial few weeks will allow the horse to stabilize before more extensive treatment can be carried out. Two foam blocks, approximately 50-60 mm thick are required to create a foam sole. The first block is taped to the sole tightly and the horse compresses it over the next 24-48 hours to create a cast as it bears weight on it. This cast of the sole (15-20 mm thick) is trimmed so that the foam which was beneath the rotated, descended solar margin of the distal phalanx is removed. The position of the solar margin is determined by the judicious use of hoof testers. This foam trimming (A) is taped onto the second foam block (B) and re-fitted onto the horse and taped in place. The pads

can be changed based on the horse's response. The horse should be kept in stables covered with deep shavings or sand.

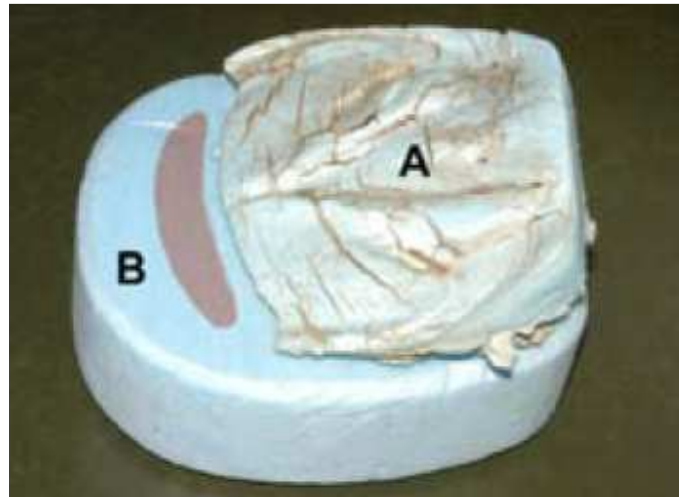


Fig 30: This foam sandwich is composed out of the compressed first foam block (A) which is trimmed and taped onto a second block (B). The shaded area should not be loaded (Pollitt, 2008).

- The Steward clog

Invented in 2003 by an American vet, this rolled-toe, rolled-heel, wooden shoe provides a good relief to many foundered horses. After the foot is cleaned, silicon impression putty is inserted into the sole, bars and frog, the wooden clog is taped in place and the foot is placed on the ground to compress the putty evenly, set and create a cast which can support the palmar or plantar half of the foot. The clog is removed so that the rubber cast can be trimmed so that any material which may create pressure on the sole beneath the solar margin is removed. The foot is placed on a piece of plywood for the perimeter to be drawn out with a marker pen to ensure that the plywood is cut to the right shape. Further measurements are taken to assure the proper placement of the clog and if the distal phalanx has already sunk and rotated, causing the sole to drop, a cavity should be sanded out to accommodate it. The hoof can then be screwed down to the wooden clog with 8G x 30-40 mm Chipboard screws whilst the feet are on the ground and fiberglass casting material can be wrapped around the perimeter for increased protection of the shoe.

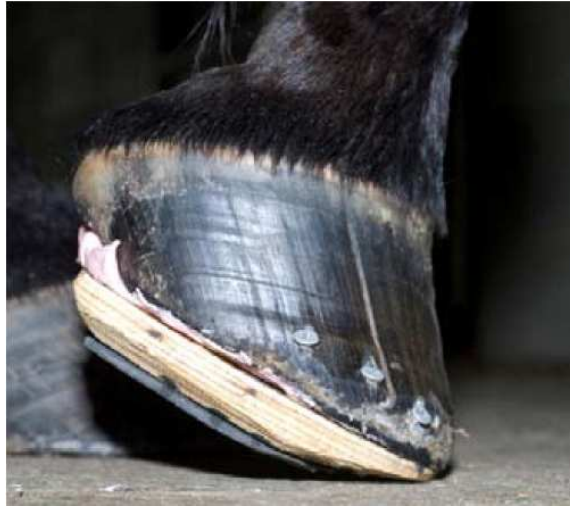

Fig 31: The Steward clog provides easy breakover whilst protecting the sole (Pollitt, 2008).

- Hoof wall resection

Resecting the hoof early in the zones equivalent to the in-growing coronet and toe of chronic laminitis cases can release the pressure on the underlying tissue and help to re-establish normal hoof growth.

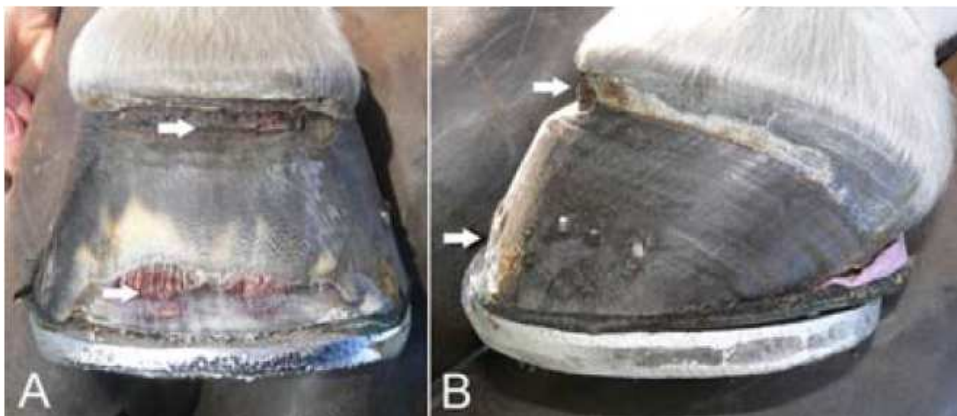

Fig 32: Dorsal (A) and lateral (B) views show a 2cm wide groove below the under the coronet and resection of the distal toe (Pollitt, 2008).

- The heart bar shoe

Although not normally involved in weight bearing, the frog could withstand a large portion of the weight without being damaged. In 1898 (Dollar JAW and Wheatley A, 1898), the heart bar shoe was first described as it could load the palmar structures of the foot to shift the weight away from the dorsal structures, limiting the lamellar separation and tearing through a counterforce. Combined with dorsal hoof wall resection, the recovery rate and regeneration was improved as the coronary band is released from the pressure by the dislocated distal phalanx and a drainage system is formed. The lamellar wedge which forms from epidermal lamellae prevents the hoof wall from forming strong attachments with the distal phalanx. Hence dorsal hoof wall resection also helps to improve the alignment of the hoof wall and the phalanx. Re-setting of the shoe, resection and a new frog-support pad are required every month

To construct the heart bar shoe, the frog support plate must be arranged in such a way that the shoe distributes pressure evenly over the whole frog, which sometimes needs to be trimmed and shaped. The tip of the frog plate should be parallel to and 2-3 mm above the level of the branches of the shoe. The breakover point of the shoe should be rolled and just beneath the distal tip of the distal phalanx to shorten the lever arm. Since the heart bar shoe is fitted to the distal phalanx and not the hoof, radiographic imaging is required to determine the correct positioning. The tip of the frog plate should be positioned directly under the insertion of the deep flexor tendon.



Fig 33: The heart bar shoe must be arranged in such a way that the frog plate (F) is above the level of the shoe's branches to apply even pressure over the entire frog. A rolled toe eases breakover (Pollitt, 2008).

This position can be determined with a lateral to medial radiograph to determine the distance between the tip of the distal phalanx and palmar processes from which two methods of determination are possible. The first (A) is to measure 37% of the distance palmar from the distal phalanx's tip and the second (B) is to drop a line from the base of the extensor process, at a 90 degree angle to the solar margin.

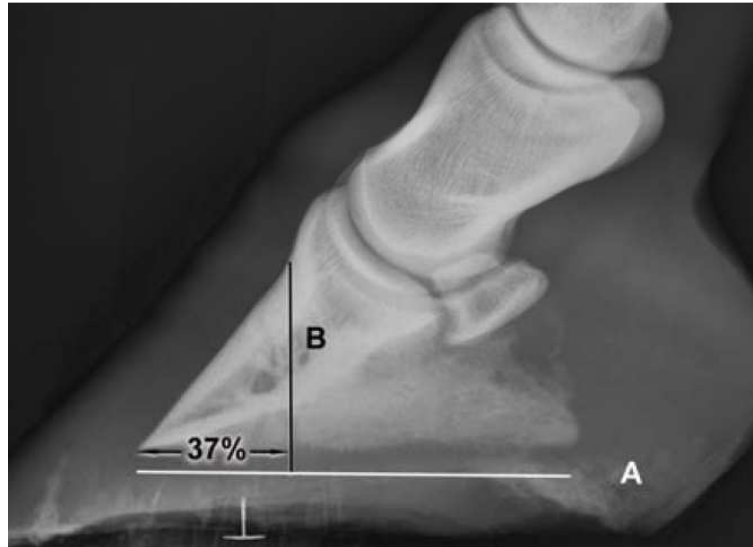

Fig 34: Radiography to fit the heart bar shoe with correct positioning (Pollitt, 2008).

- Heel elevation

Whilst the weight of the horse is considered to be the most important factor in causing separation of damaged lamellae, the rotary force created by the contraction of the deep flexor tendon also plays a role. Raising the heels in cases of acute laminitis by 12-18 degrees can decrease the biomechanical tension in the tendon by half. However, if rotation is present, the hoof should first be trimmed to normalize the position of the distal phalanx.



Fig 35: This is a glue on 'Outlaw shoe' which redistributes the weight evenly over the dorsal two-thirds of the foot when standing. By using a 5° wedge, it provides temporary relief to the flexor tendons, especially in the acute stage (The Outlaw Shoe, 2006).

In case of chronic laminitis, the heel should be elevated 2-6° to help the horse land perfectly heel first (O'Grady, 2010). The wedge should be removed approximately two weeks after the clinical signs have disappeared.

- The Equine Digit Support System (EDSS)

This kit comprises of a Natural balance shoe with predrilled and tapped holes, a plastic pad with a built in frog plate, additional frog inserts and wedge rails, allowing the farrier and veterinarian to work together to build the best combination possible for the horse in question. The interchangeable parts allow for quick changes in heel height without removing the shoe.




Fig 36: Components of the equine digital support system: the Natural Balance shoe (A), plastic pad with built in frog plate (B), additional frog inserts (C) and wedge rails (D) (Pollitt, 2008).

After the foot is cleaned and a cast of the bottom of the foot is made with silicone based impression material, it is covered with a hard pad for the horse to bear its weight on, for the cast to set. This is then trimmed so that only the back of the foot bears weight. The heels are trimmed so that the bearing surface is adjacent to the widest part of the frog. The foot is shod with the help of radiographs to ensure that the rolled toe is aligned beneath the tip of the distal phalanx. If nailing is too painful, glue on aluminum tabs can be used instead. Based on the comfort of the horse, the additional parts of the kit can be applied as suited. The wedge rails provided can be used to adjust the elevation of the heel.

- **The surgical option - Deep flexor tenotomy**

If the distal phalanx rotates and descends into the hoof capsule, a deep flexor tenotomy to remove the disto-palmar force put upon the distal phalanx should be considered. The prognosis is poor if osteolysis and abscessation has already occurred.

Preventing laminitis in the contralateral limb

Horses which cannot bear weight on one of their fore- or hindlimbs due to fractures, sepsis and other injuries often develop laminitis on their contralateral limb (Hunt, 1993; Peloso et al., 1996). In vitro studies have shown that raising the hoof angle by 23° with heel wedges decreased tension in the deep digital flexor by at least 60% (Thompson et al., 1993). In vivo studies on 86 representative high-risk cases which were immediately fitted with special shoes which raised the heels and moved breakover backwards helping the horse to stand with a distal phalanx palmar angle of 20° whilst supporting the hoof wall were also carried out (Redden, 2004). Only one of these cases had resultant laminitis in the contralateral limb as the shoe successfully prevented overloading of the supporting foot and maximized laminar perfusion.

Discussion

Moving breakover backwards has been shown to decrease the strain forces of the deep digital flexor tendon (decreasing inflammation and disease in the digit) (Page & Hagen, 2002) and perhaps most importantly, improved the alignment of the hoof-pastern axis. This breakover distance might increase due to the excessive growth and insufficient erosion of the epidermal hoof wall (Page & Hagen, 2002).

The ground reaction force (GRF) extends the distal interphalangeal joint during stance at the point of zero moment (PZM) (Nigg & Herzog, 1994; Wilson et al., 1998; Wilson et al., 2001) which lies 10-20% of foot ground contact length cranial to the distal interphalangeal joint (DIP) during most of the stance. However, it moves forward as horse starts to take its step, from 75-85% of the stance (Wilson et al., 1998; Wilson et al., 2001). At the same time, the craniocaudal part of the GRF is high, increasing the moment arm on the DIP joint which peaks at 90-95% of stance. The actual DIP joint moment peaks at 60-65% of the stance, before the moment arm, as the resultant GRF decreases from midstance onwards (Wilson et al., 1998; Wilson et al., 2001) as the horse is reducing the weight it is loading on the ground. There is a second smaller peak in the DIP joint's moment as the PZM moves towards the toe at the end of stance hence pulling the toe back would result in the PZM reaching the toe earlier and the heels leaving the ground at a higher GRF, earlier in the stance. This would lower the peak joint moment arm but keep the actual peak joint moment unchanged (Eliashar et al., 2002).

The study conducted by Van Heel et al. (2004), mentioned in the section titled 'Kinematics of landing' showed that lateral landing should be considered standard in warmblood horses but might differ in other horses, however the study conducted by Eliashar et al. (2002) using a force plate also measured lateral landings in Irish draught horses, even though they were shod in 3 different ways. These results are significantly different from other studies performed (Barrey, 1990; Clayton, 1990; Wilson et al., 1998) though the techniques used in the Van Heel and Eliashar studies are more reliable. Eliashar et al. (2004) also showed that the mean maximum lateral displacement of the centre of pressure did not change significantly after trimming, though it was larger in the front feet (20.2 mm) than in the hind feet (11.4 mm).

The Eliashar et al. (2004) study also showed that landing duration also decreased significantly after trimming due to the quicker complete foot support during impact with a reduction of about 2.2 msec in both the front and hind limbs (though the front feet had a mean duration of 6.7 msec, the hind feet had a mean of 16.7 msec, hence the degree of decrease is much larger in the front feet). This decreased time in landing could be attributed to the centre of pressure moving faster towards the centre of the foot which should result in better load distribution over the structures in the foot. The differences seen between the front and hind feet could be attributed to a number of explanations:

1. It could be easier for farriers to change landing and hence loading conditions in the hind feet (van Heel et al., 2004).
2. The hoof ground angle at impact is larger in the hind feet than in the front (Merkens & Schamhardt, 1994; Back et al., 1995a).
3. The higher vertical acceleration during impact in the front feet (as opposed to the higher horizontal acceleration during impact in the hind feet) (Back et al., 1995b).

Unfortunately, in the study carried out by Colahan et al. (1993) mentioned in the section titled 'Kinematics of Standing' the horses shod were sedated and this hence provides a limitation to this study.

Due to compensation mechanisms carried out by the horse hooves between shoeing intervals, the mathematical calculation of the centre of pressure is different to the actual centre of pressure that would be expected (van Heel et al., 2005).

The farrier hence has a huge roll in altering the kinematics of the horse:

1. By trimming or applying a rolled, rockered or square toe shoe, breakover can be eased. Having a bevel will also reduce the tension on the deep digital flexor tendon and the collateral ligaments of the distal interphalangeal joint (Parks, A, 2003) and abnormal loading tension on the distal sesamoid bone's suspensory ligament especially on turns (Willemen et al., 1999).
2. Trimming back the toe at the dorsal hoof wall and not removing too much live sole helps protect the sole depth. This would help prevent chronic subsolar bruising

leading to damage to the underlying dermis, circulation and the third phalanx. If this was not adequately addressed and the underlying sensitive tissue got inflamed, medication and physical therapy in the form of cryotherapy, poultices and padding would be necessary. After the inflammation has been controlled, using turpentine, iodine or a commercial sole toughener to desiccate and harden the sole material. A wide web shoe with, if further protection is needed, a pad beneath it should then be applied to protect a larger portion of the sole (Peters, 2010).

Flat footed horses should be treated with a wider web shoe with a concave shoe surface as they are usually sensitive to hoof testers after the shoes have been removed. They are usually in a worse state of lameness once they have been reshod. This type of shoe could be handmade in a forge using a rounding hammer from a manufactured shoe or reshaping a steel training plate.

3. By supporting the heels, they will start to roll under and decrease the angle of the bars and narrow the caudal aspect of the foot, the mechanical forces on the hoof wall may shift towards the quarters and if further medial / lateral foot imbalance is also present, it could lead to flexing and weakening of the hoof wall, resulting in quarter cracks (Thomson et al., 1992; Kasapi & Gosline, 1996). If the caudal soft tissues can contact the ground properly, they will absorb the energy of the impact maximally, optimizing hemodynamic perfusion of the foot tissues and providing the foot with the required proprioceptive awareness (Bowker et al., 1995; Bowker et al., 1998). Lowering the heel to extend the ground surface of the foot and using a longer branch shoe can help decrease the occurrence of quarter and heel cracks, sheared and contracted heels, corns and navicular disease. Egg bar shoes also help to increase ground surface and to give the heel the opportunity to expand naturally for the next reshoeing.

A low heel angle can be raised with wedge heel inserts or swelled heel shoes. Although wedge pads do mechanically lift the heel, the correction does not last long and causes an increased pressure on the hoof wall at the heels, encouraging more wear and eventually leading to collapse of the hoof.

The farrier and the vet must also make decision on the **application of devices** which alter the traction of the foot (heel calks, raised nails, borium studs and raised rims) as they can put additional stress on the foot, bones, ligaments, and tendons (Parks, A, 2003).

Heel calks reduce the total ground surface hence concentrating the total ground contact to a small area (especially when the horse is working on hard ground) and elevate the posterior aspect of the foot hence changing the foot axis and over-rotating the coffin and fetlock joints. This is a big problem when the horse is suffering from diseases of the suspensory apparatus. They could also be dangerous when horses make sudden turns as they could stick in the surface whilst the limb rotates, possibly resulting in tearing of ligaments and tendons or even fractures of the first or second phalanx as well as the third metacarpal/ metatarsal.

Toe grabs have been banned from many race tracks as 90.5% of horses which had catastrophic injuries wore toe grabs (Kane et al., 1996). This is because toe grabs result in a broken-back hoof pastern axis and increases the hyperextension of the fetlock joint leading to an increased force being required for breakover which results in increased force loads distributed to the distal foot and fatal musculoskeletal injury (Gillette & Peterson, n.d.).

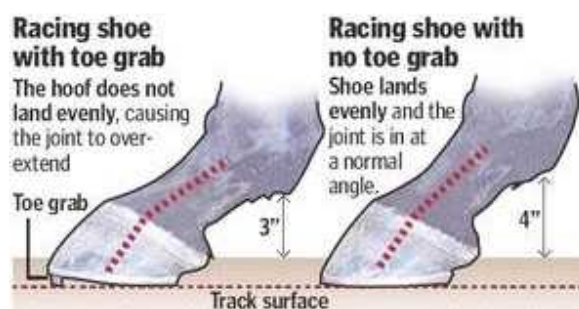

Fig 37: Illustration demonstrating the negative effects of the toe grab (Wolfson & Reed, 2008).

Applying the shoe is a somewhat delicate matter as if not put on correctly, the distortion could be visualized during physical examination of the lame horse. In these cases the heel (when viewed from behind) and coronary band on the affected side would be displaced upwards, there would be deep fissuring of the central sulcus, the opposite toe and quarter would be flared and there would be abnormal wear of the shoe. Pulling the shoes, balancing the foot and turning out

the horse is most often the preferred treatment in such cases of malposition, allowing the foot to expand properly and improve its overall condition. The farrier should also consider applying a bar shoe to help the normal foot re-establish as it would offer more protection due to its more even weight distribution and increased total ground surface and rigidity, allowing the vet to perform other corrections if they are required.

When shoeing for **club foot**, the case in question must be differentiated from an upright foot with a high heel. This means that it would have a toe angle greater than 55°, the slope of the horn tubules in the hoof wall will be similar to those in the toe and the palmar foot's soft structures will be well developed (O'Grady & Dryden, 2012).

In foals with congenital club foot, the naturally steep hoof wall angle is based on the hoof-pastern axis, as if the dorsal hoof wall and pastern are aligned, the foal is probably healthy. Although this case can usually be managed with a controlled exercise regiment and provision of good footing, if no improvement is observed within 2 weeks of birth, therapeutic action should be taken and the foal should be put onto glue-on elevated heels called Dalric B1 cuffs. The duration of application depends on the age of the foal:

- Birth to 2 weeks of age—remove after 4 days and re-evaluate in 7 days
- 2 to 4 weeks of age—remove after 10 days and re-evaluate in 7 to 10 days
- 4 to 8 weeks of age—remove after 10 to 14 days and re-evaluate in 7 to 10 days
- 8 to 12 weeks of age—remove after 14 days and re-evaluate in 7 to 10 days
- 3 to 8 months of age—remove after 21 days and re-evaluate in 7 to 10 days

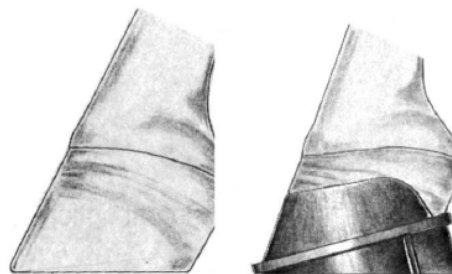


Fig 38: The use of the Dalric B1 cuff to treat a young foal's coffin joint contracture (Floyd, 2007).

Initial evaluation is done by removing the wedge and cuff, appropriately trimming the hoof and monitoring how comfortably the foal loads the balanced hoof as if the foal is still not comfortable, the wedge should be reapplied for the amount of time indicated by the guidelines above, depending on the current age of the animal. If wedge application is unresponsive, a surgical release procedure could be carried out with a desmotomy of the inferior check ligament. In severe cases, a tenotomy of the deep flexor tendon could be also needed.

In cases of acquired club foot in foals, half of the foals observed in the van Heel et al., 2006 study developed uneven feet with a high heel on the protracted limb, resulting in researchers believing that this genetic configuration was linked with acquired flexural deformity. However, unfortunately the real etiology remains unknown. Speculation towards improper nutrition (carbohydrate overload), excessive exercise and discomfort due to pain caused by physal dysplasia, trauma from exercising on hard ground or following aggressive trimming also exist (O'Grady & Dryden, 2012). This discomfort could cause the foal to bear less weight on the painful limb, resulting in contracture of the flexor muscles causing the distal interphalangeal joint's angulation to change. The weight bearing will hence shift to the foot's dorsal half, leading to a decrease in sole depth and horn growth on the dorsal hoof wall and excessive hoof wall growth at the heel.

An interesting point of discussion in serious cases of club foot seen *in mature horses* is that although the heels need to be lowered to unload the toe, heel elevation will also be needed to compensate for the shortened musculotendinous unit. This confusing concept of lowering then elevating the heels by wedging the hoof must happen because whilst the heels are trimmed to the widest point of the frog to increase the load bearing surface area, breakover must be decreased to help the deep digital flexor tendon with a wedge which is often the same size as the amount of heel removed. The amount of heel elevation required can be calculated by placing the trimmed foot on the ground, 15-20 cm palmar to the healthy limb. The space that appears between the heels and ground indicates the size of pad or bar wedge and shoe required to compensate for the shortened tendon. So although the limb can be weight bearing, the stress

on the deep digital flexor is reduced. Breakover can be eased in the same way that it would be in a less severe case.

Mismatched feet could be the result of a horse is suffering from shoulder osteochondritis dissecans which could lead to the development of acquired club foot on the same limb as the musculotendinous unit bears less weight to be less painful, resulting in the contralateral limb bearing the larger share of weight and becoming a low angle foot. Raising this low angle foot with a wedge to match the other foot to align the hoof-pastern axis will put more stress on the heel structures but could cause prolapse of the frog beneath the foot's ground surface. The shoeing of this low angle foot should be aimed at moving the centre of pressure away from the heels by rockering the toe, using impression material, a pour-in pad and a frog-support pad or heel plate. Both feet should be treated individually and the initial cause of lameness must be found and addressed (O'Grady & Dryden, 2012).

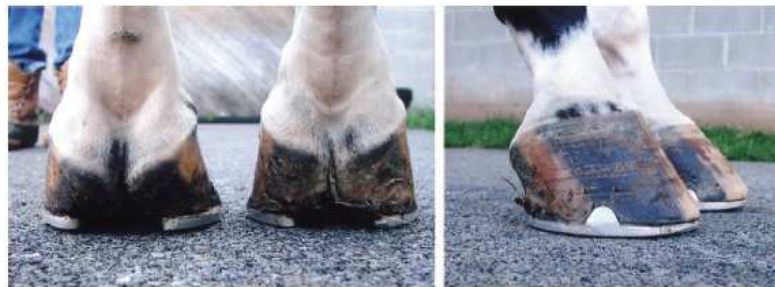

Fig 39: This horse evidently has mismatched feet, not club foot (Floyd, 2007).

Interestingly, the idea behind the theory of ischaemia being the cause of **navicular syndrome** is that through thrombosis of the distal navicular artery, ischemia occurs in the adjacent bone to cause pain and lead to lameness. This results in an increase in arteriolar anastomoses (Colles, 1979; Colles & Hickman, 1977; Colles, 1983) which cause osteoporosis at the tip of the foramina to cause the typical change in shape. The subsequent revascularization if this area should result in the remission of the lameness unless the revascularization itself cannot keep up with the number of thrombi causing occlusions. The subchondral necrosis resulting

from the ischemia could progress through the flexor fibrocartilage and cause adhesions between the deep digital flexor and the navicular bone (Turner, 2007).

Treatment with bisphosphonates which is used to treat osteoporosis is quickly becoming a mainstay in therapy of navicular syndrome. The bisphosphonate has a high affinity for calcium to which it binds resulting in accumulation in the bones where the main calcium store is present. This results in a slow release of bisphosphonates and long duration of action. Although initially only available through Europe, the drug group recently became approved in the United States, resulting in increased use in many clinics where I have seen practice. Adverse reactions in horses treated with Tildren generally occurred during the 90 minute intravenous infusion or within four hours of the infusion with 30-45 % of horses showing signs of colic. In the following 16 hours, field studies indicated that other side effects included increased urination, decreased appetite, a stiff neck, fever and uncomplicated colic. With Osphos, adverse reactions generally initiated within 2 hours of treatment in the form of discomfort and signs of colic. Hand walking is also recommended. In both cases, non-steroidal anti-inflammatory drug treatment is highly contraindicated as this could increase the risk of renal toxicity and acute renal failure (FDA, 2014). Due to the route of administration, Osphos is appearing to have fewer side effects than Tildren, however more studies are required (Ramey, 2014).

In cases of **laminitis**, once the tissue begins to heal following the lamellar collapse, the empty space created by the separation of the dorsal hoof wall and distal phalanx is filled with hyperplastic and hyperkeratinized epidermis. This leads to decreased strength of attachment between the epidermal and dermal lamellae as the lamellae undergo dysplasia and malformation. This leads to the displacement which comes in three presentations that may be simultaneous: dorsal capsular rotation (A), mediolateral rotation (B) and sinking (C) (O'Grady, 2010).

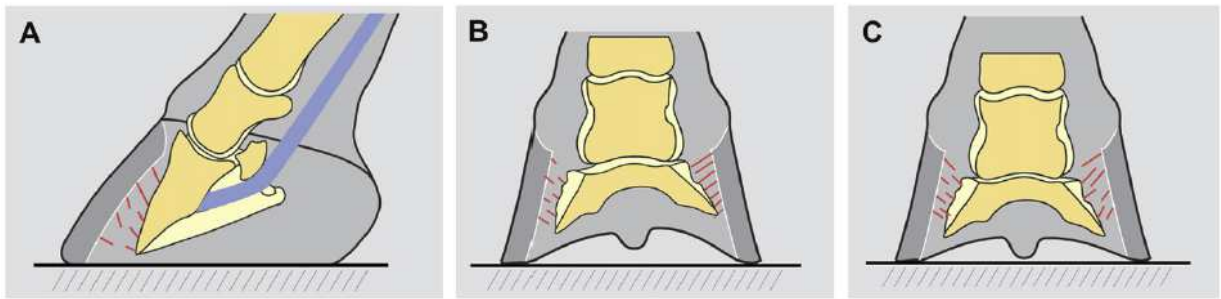


Fig 40: The three forms of displacement of the distal phalanx: dorsal capsular rotation (A), mediolateral rotation (B) and sinking (C) (O'Grady, 2010).

The rate of hoof-distal phalangeal distance (HDPD) increase correlates with the severity of the lesion. This is because when the majority of the lamellar attachment fails simultaneously, there is a circumferential separation of the hoof from the distal phalanx, allowing the latter to sink vertically. This severity is further shown by the radiolucent line that is created underneath the inner hoof wall as air or gas gets into the space previously filled by the lamellae. Although this phenomenon is still a mystery, one theory is that it occurs due to a gradient of negative pressure resulting in air being pulled out of the blood vessels.

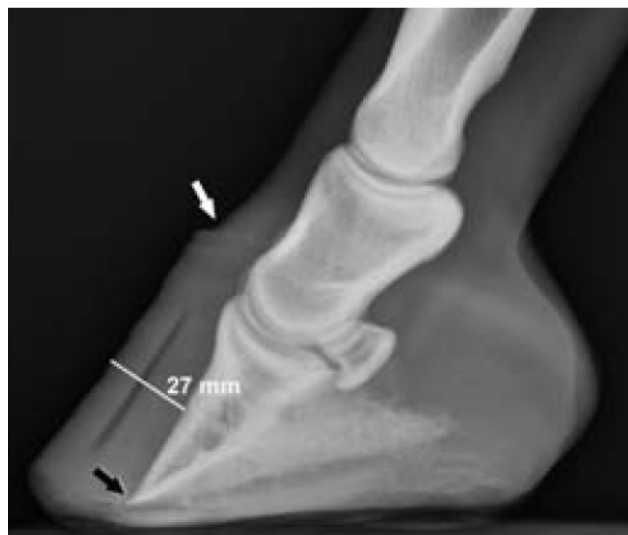

Fig 41: This radiograph of a foot with chronic and severe laminitis shows the effect of the coffin bone sinking (deficit at the dorsal coronet near the white arrow), the radiopaque line and the distal phalanx approaching the solar surface (black arrow) (Pollitt, 2008).

During medical therapy, profound vasoconstriction resulting from cryotherapy decreases the delivery of 'laminitis trigger factors' to the digit and the hypometabolic state induced decreases:

- The production and activation of lamellar matrix metalloproteinases (MMPs).
- The enzymatic degradation by the MMPs.
- Pro-inflammatory cytokines' (Interleukins and Tumor Necrosis Factors) production and activity.
- Infiltration by polymorphonuclear leukocytes which cause secondary inflammatory damage.
- Requirement for energy substrates.

(Pollitt, 2008)

Conclusion and Summary

Through this literature review, I hope that I have been able to show the importance of a good farrier-veterinarian relationship. An equine veterinarian must first understand the foot's configuration and kinematics before he or she can recommend a treatment option to a farrier which is in the best interest for the horse in question. Although club foot, navicular syndrome and laminitis are just three of an abundant and never-ending number of possible hoof disorders, the essence of farriery will always remain the same: to ease breakover, protect the sole and protect the hoof.

When horses are suffering from **club feet**, a four-week trimming schedule should be recommended. The farrier must load the heels, improve the hoof-pastern axis and provide compensation for the shortened deep digital flexor tendon causing the flexural deformity. In young horses, glue-on Dalric B1 cuffs are most often used and their duration of use and re-evaluation is outlined in the discussion, depending on the age of the foal. Following recovery, the application of a 'reverse wedge' to protect the toe and aid in the redistribution of the load towards the foot's palmar aspect should be carried out. In adult horses, the foot should be trimmed in such a way which does not cause discomfort or pain. A handmade shoe should then be applied which promotes breakover slightly dorsal to the apex of the frog whilst the insertion of a wedge shoe or pad at the heel should be inserted to compensate for the shortened tendon.

In cases of **navicular syndrome**, a combination of bisphosphonate administration and corrective farriery is beginning to look like the way forward. Increasing the dorsal hoof wall angle and shortening toe length to protect the deep digital flexor tendon can be done by raising the heels and rolling the toe to ease breakover. Applying a full bar shoe or pad will help to protect the frog from further damage.

If **laminitis** is involved, providing adequate mechanical support early in the disease to the frog and sole can result in a better outcome even if this is only a temporary measure until

digital support shoes can be applied. Heart-bar shoes stabilize the coffin bone and support the damaged lamellae by bringing the load away from the toe. By raising the heels with wedges, the forces exerted by the deep digital flexor tendon on the distal phalanx can also be reduced to decrease pain and further progression of lamellar separation. Both the Steward clog and Equine Digit Support System provide an interchangeable mechanism which can easily alter where the load is placed and protect the back part of the foot. Hoof wall resection is essential in cases of chronic laminitis to improve hoof growth with proper lamellar structure.

As the famous English proverb goes, 'No hoof, no horse', maintaining a sound horse through proper care of the hoof is essential throughout all stages of life, independent to what the horse is used for. Communication between the farrier and veterinarian is key to ensure the wellbeing and comfort of the horse.

Acknowledgements

First and foremost, I would like to thank Dr. Geric for his invaluable correspondence, support and guidance, without his help I would surely not have been able to complete this thesis.

Secondly, I would like to acknowledge my family, without their support and belief in me, I would not have been able to study veterinary medicine and get through circumstances when not even I believed in myself.

I would also like to acknowledge my friends who have pushed me to do better, get out of tough situations and provided some relief when it was sorely needed.

Finally I would also like to thank all the other professionals who have made this all possible, especially the farriers in Malta who dedicated their time to show me how they work, to the veterinarians who explained difficult concepts and shared valuable reading material with me.

Bibliography

- Adkins, A., 2008. Flexural limb deformity. In *Proc Brit Equine Vet Assoc Congress*. Birmingham (UK), 2008.
- Agne, B., 2010. Laminitis: Recognition of At-Risk Individuals, and Methods of Prevention. *J Equine Vet Sci*, 30(9), pp.471-74.
- Arabian, A., Lanovaz, J. & Clayton, H., 2001. Determination of hoof mass and centre of mass from morphological measurements. *Equine Vet J*, (33), pp.46-49.
- Arry International, 1999. *Arry International*. [Online] Available at: <http://www.arryinternational.com/> [Accessed 15 October 2014].
- Asquith, R.L. & Kivipelto, J., 1994. The Navicular Syndrome. *J Equine Vet Sci*, 14(8), pp.408-10.
- Atlanta Equine Clinic, T., n.d. *Tripping in the Forelimbs*. [Online] Available at: http://www.atlantaequine.com/pages/client_lib_tripping.html [Accessed 30 August 2014].
- Back, W., Schamhardt, H.C., Hartmann, W. & Barnevald, A., 1995a. Kinematic differences between the distal portions of the forelimb and hindlimbs of horses at trot. *Am J Vet Res*, (56), pp.1522-28.
- Back, W., Schamhardt, H.C., Hartmann, W. & Barnevald, A., 1995b. Repetitive loading and oscillations in the distal fore and hind limb as predisposing factors for equine lameness. *Am J Vet Res*, (56), pp.1522-28.
- Balch, O., 2007. Discipline-Specific hoof preparation and shoeing. In A. Floyd & R. Mansmann, eds. *Equine Podiatry*. 1st ed. Saunders. pp.393-413.
- Balch, O., Butler, D. & Collier, M., 1997. Balancing the normal foot: hoof preparation, shoe fit and shoe modification in the performance horse. *Equine Vet Educ*, (9), pp.143-54.
- Balch, O. et al., 1988. Correlation of equine forelimb hoof impact patterns to changes in the medio-lateral balance of the hoof. *Anat Histol Embryol*, (17), pp.361-62.
- Balch, O., White, K. & Butler, D., 1991. Factors involved in the balancing of equine hooves. *J Am Vet Med Assoc*, (11), pp.1980-89.
- Balch, O., White, K., Butler, D. & Metcalf, S., 1995. Hoof balance and lameness: foot bruising and limb contact. *Comp on Cont Educ for the Practicing Veterinarian*, (17), pp.1503-09.
- Balch, O., White, K., Butler, D. & Metcalf, S., 1995. Hoof balance and lameness: foot bruising and limb contact. *Compend Contin Educ Pract Vet*, 17(2), pp.1503-05.
- Barrey, E., 1990. Investigation of the vertical force distribution in the equine forelimb with an instrumented horseboot. *Equine vet J Suppl*, (9), pp.35-38.
- Bartel, D., Schryver, H., Lowe, J. & Parker, R., 1978. Locomotion in the horse: a procedure for computing the internal forces in the digit. *Am J vet Res*, (39), pp.1721-27.

- Benoit, P., Barrey, E., Regnault, J. & Brochet, L., 1993. Comparison of the dampening effect of different shoeing by the measurement of hoof acceleration. *Acta Anat*, (146), pp.109-13.
- Bowker, R., Linder, K., Sonea, I. & Guida, L., 1995. Sensory nerve fibers and receptors in equine distal forelimbs and the potential roles in locomotion. *Equine Vet J*, 27(18), pp.141-46.
- Bowker, R., Van Wulfen, K., Springer, S. & Linder, K., 1998. Functional anatomy of the cartilage of the distal phalanx and digital cushion in the equine foot and a hemodynamic flow hypothesis of energy dissipation. *Am J Vet Res*, (59), pp.961-68.
- Caldwell, F. & Waguespack, R., 2011. Evaluation of a tenoscopic approach for desmotomy of the accessory ligament of the deep digital flexor tendon in horses. *Vet Surg*, (40), pp.266-71.
- Caudron, I. et al., 1998a. Radiographic assessment of equine interphalangeal joints asymmetry: articular impact of asymmetrical bearings (part 2). *Zentralbl Veterinarmed A*, (45), pp.327-35.
- Caudron, I. et al., 1998b. In shoe foot force sensor to assess hoof balance determined by radiographic method in ponies trotting on a treadmill. *Vet Quart*, (20), pp.131-35.
- Ceva, 2014. *TILDREN® Injection*. [Online] Available at: <http://www.ceva-asiapacific.com/Products/Product-List/TILDREN-R-Injection> [Accessed 16 November 2014].
- Clayton, H., 1990. The effect of an acute hoof angulation on the stride kinematics of trotting horses. *Equine Vet J (suppl)*, (9), pp.86-90.
- Clayton, H., 1990. The effects of acute hoof angulation on stride kinematics of trotting horses. *Equine vet J Suppl.*, (9), pp.86-91.
- Clayton, H., Sigafoos, R. & Curle, R., 1991. Effect of three shoe types on the duration of breakover in sound trotting horses. *J equine vet Sci*, (11), pp.129-32.
- Colahan, P., Lindsey, E. & C, N., 1993. Determination of the center of pressure of the hoofs of the forelimbs of horses standing on a flat level surface. *Acta Anat (Basel)*, (146), pp.175-8.
- Colles, C., 1979. Ischemic necrosis of the navicular bone and its treatment. *Vet Rec*, (104), pp.133-37.
- Colles, C., 1982. Navicular disease and its treatment. *In Practice*, 4, pp.29-36.
- Colles, C., 1983. Concepts of blood flow in the etiology and treatment of navicular disease. In *Proc 29th Annul Cony Am Assoc Equine Practnr.*, 1983.
- Colles, C., 1983. Interpreting radiographs 1: The foot. *Equine Vet J*, 15, pp.297-303.
- Colles, C. & Hickman, J., 1977. The arterial supply of the navicular bone and its variations in navicular disease. *Equine Vet J*, 9(3), pp.150-54.

Collier, M., Haugland, L. & DeBault, L., 1993. 3H-PSGAG concentrations in the synovial fluid of the equine carpal, fore fetlock, hock and coffin joints following a 500mg intramuscular injection. In *Proc 39th Conv Amer Assoc Equine Practnr.*, 1993.

Crevier-Denoix, N.R.C. et al., 2001. Effects of heel and toe elevation upon the digital joint angles in the standing horse. *Equine vet J Suppl*, (33), pp.74-78.

Davies, H., 1997. Noninvasive photoelastic method to show distribution of strain in the hoof wall of a living horse. *Equine Vet J*, (23), pp.13-15.

Dechra, 2014. *Osphos*. [Online] Available at: http://www.dechra-us.com/files//dechraUSA/downloads/Client%20Literature/59936_Osphos.pdf [Accessed 16 November 2014].

Denoix, J., 1999. Functional anatomy of the equine interphalangeal joint. In *45th Annul Am Assoc Equine Practnrs Conv*. Albuquerque, New Mexico, 1999.

Drommer, W., 1993. Transmission and grid electron microscopy results on the facies flexoria of the navicular bone and the deep flexor tendon in a horse under special consideration of the podotrochlose syndrome. In *International Symposium on Podotrochlosis*. Dortmund, Germany, 1993.

Dryden, V., n.d. *Navicular syndrome*. [Online] Available at: <http://www.roodandriddle.com/news/navicular-syndrome.html> [Accessed 21 October 2014].

Eliashar, E., McGuigan, M.P., Rogers, K.A. & Wilson, A.M., 2002. A comparison of three horseshoeing styles on the kinetics of breakover in sound horses. *Equine vet J*, (34), pp.184-90.

FDA, 2014. *FDA Provides Equine Veterinarians with Important Information about TILDREN and OSPHOS for Navicular Syndrome in Horses*. [Online] Available at: http://www.fda.gov/AnimalVeterinary/ResourcesforYou/ucm406581.htm?source=govdelivery&utm_medium=email&utm_source=govdelivery#TILDREN [Accessed 20 November 2014].

Floyd, A., 2007. Deformities of the limb and their relevance to the foot. In Floyd, A.E. & Mansmann, R. *Equine Podiatry*. Missouri: Saunders. pp.205-23.

Floyd, A., 2007. Deformities of the limb and their relevance to the limb. In A. Floyd & R. Mansmann, eds. *Equine podiatry*. St. Louis (MO): Saunders. pp.218-23.

Floyd, A., 2007. Grading the Laminitic Horse. In *Equine Podiatry*. 1st ed. Missouri: Saunders. pp.324-27.

Fricke, C., Hugelshofer, J. & Attinger, P., 1986. Fasziotomie Neurolyse als Therapie der Strahlbeinmüdigkeit (Podotrochlose) des Pferdes. *Schweizer Archiv für Tierheilkunde*, (128), pp.87-90.

Gibson, K. & Stashek, T., 1990. Treatment strategies for navicular syndrome. *Vet Med*, (2), pp.178-86.

- Gillette, R. & Peterson, M., n.d. *Abnormal Forces Associated Abnormal Forces Associated*. [Online] Available at: http://www.grayson-jockeyclub.org/newsimages/wss_toegrab.pdf [Accessed 15 October 2014].
- Habecker, P., 2009. *My Favorite Common Large Animal Lesions*. [Online] Available at: <http://research.vet.upenn.edu/SystemicPathology/Exam4/CommonLargeAnimalLesions/tabid/3648/galleryType/SlideShow/ItemID/406/AlbumID/39/Default.aspx> [Accessed 22 October 2014].
- Harvey, A., Williams, S. & Singer, E., 2012. The effect of lateral heel studs on the kinematics of the equine digit while cantering on grass. *The Vet J*, (192), pp.217-21.
- Hertsch, B., 1993. The diagnostic value of the direct intraarticular pressure measurement in the coffin joint for differentiation of the navicular syndrome in equine lameness examination. In *International Symposium on Podotrochlosis*. Dortmund, Germany, 1993.
- Hood, D., 1987. Equine Digital Biomechanics. *Equine Vet J*, 7(4), pp.236-37.
- Hunt, R., 1993. A retrospective evaluation of laminitis in horses. *Equine Vet J*, (25), pp.61-64.
- Hunt, R., 2011. Flexural limb deformities in foals. In M.W. Ross & S.J. Dyson, eds. *Diagnosis and management of lameness in the horse*. 2nd ed. St. Louis (MO): Elsevier Saunders. pp.635-49.
- Jansen, M., Schamhardt, H., Hartman, W. & Barneveld, A., 1995. In Vivo Tendon Forces in the Equine Forelimb Related to Failure Forces and the Influence of a Heel Wedge at trot. Tendon Strain, Force and Function in Equine Locomotion. In *PhD Thesis*. University of Utrecht. pp.77-94.
- Jansen, M., van den Bogert, A., Riemersma, D. & Schamhardt, H., 1993. In vivo tendon forces in the forelimb of ponies at walk, validated by ground reaction force measurements. *Acta Anat*, (146), pp.162-67.
- Kane, A. et al., 1996. Postmortem evaluation of homotypic variation in shoe characteristics of 201 thoroughbred racehorses. *Am J Vet Res*, 57(8), pp.1141-46.
- Kasapi, M. & Gosline, G., 1996. Strain-rate-dependent mechanical properties of the equine hoof wall. *J Exp Biol*, 199, pp.1133-46.
- Keegan, K. et al., 1998. Effects of balancing and shoeing of the forelimb feet on kinematic gait analysis in five horses with navicular disease. *J Equine Vet Sci*, 18(8), pp.522-27.
- Kidd, J. & Barr, A., 2002. Flexural deformities in foals. *Equine Vet Educ*, (14), pp.311-21.
- Kirker-Head, C., 1993. Use of propentophylline for the treatment of equine navicular disease. In *International Symposium on Podotrochlearis*. Dortmund, Germany, 1993.
- Kummer, M., Gygax, D., Lischer, C. & Auer, J., 2009. Comparison of the trimming procedure of six different farriers by quantitative evaluation of hoof radiographs. *Vet J*, (179), pp.401-06.

- Lochner, F., Milne, D. & Mills, E., 1980. In vivo and in vitro measurement of tendon strain in the horse. *Am J Vet Res*, (41), pp.1929-36.
- Longland, A. & Byrde, B., 2006. Pasture nonstructural carbohydrates and equine laminitis. *J Nutr*, (136), pp.2099-102.
- Malone, S. & Davies, H., 2011. The effects of hoof trimming and farrier on hoof shape. *J Equine Vet Sci*, (31), pp.294-95.
- Mansmann, R. & Vom Orde, K., 2007. Preventive Foot Care Programs. In A. Floyd & R. Mansmann, eds. *Equine Podiatry*. 1st ed. Saunders. pp.414-31.
- Matthews, N., Gleed, R., Short, C. & Burrows, K., 1986. Cardiovascular and pharmacokinetic effects of isoxsuprine in the horse. *Am J Vet Res*, 47(10), pp.2130-33.
- Meier, H., 1993. A review of investigations of the etiology of navicular disease. In *International Symposium on Podotrochlearis*. Dortmund, Germany, 1993.
- Merkens, H. & Schamhardt, H., 1994. Relationship between ground reaction force patterns and kinematics in the walking and trotting horse. *Equine vet J, Suppl*, (17), pp.67-70.
- Moleman, M., van Heel, M., van Weeren, P. & Back, W., 2006. Hoof growth between two shoeing sessions leads to a substantial increase of the moment about the distal, but not proximal, interphalangeal joint. *Equine Vet J*, (38), pp.170-74.
- Moyer, W. & Anderson, P., 1975. Lameness caused by Improper Shoeing. *J Am Vet Med Assoc*, 166(1), pp.47-52.
- Moyer, W., Schumacher, J. & Schumacher, J., 2007. Palmar Digital nerve. In *A guide to Equine Joint Injection and Regional Anesthesia*. Pennsylvania: Veterinary Learning Systems. pp.80-81.
- Newlyn, H. et al., 1998. Finite element analysis of static loading in the donkey hoof wall. *Equine Vet J*, (26), pp.103-10.
- Nigg, B. & Herzog, W., 1994. *Biomechanics of the musculoskeletal system*. Chichester: John Wiley and Sons Ltd.
- O'Grady, S., 2003. *Hoof Angle*. [Online] Available at: <http://www.equipodiatry.com/hoofangl.htm> [Accessed 24 April 2014].
- O'Grady, S., 2003. Trimming and Shoeing the Horse's Foot. *J Equine Vet Sci*, 23(4), pp.169-70.
- O'Grady, S., 2008. Basic farriery for the performance horse. *Vet Clin North Am Equine Pract*, 24(1), pp.203-18.
- O'Grady, S., 2009. Guidelines for trimming the equine foot: a review. In *Proc Am Assoc Equine Practnr.*, 2009.

- O'Grady, S., 2011. Farriery for common hoof problems. In Baxter, G.M. *Adams and Stashak's Lameness in Horses*. 6th ed. Wiley-Blackwell. pp.1199-210.
- O'Grady, S., 2012. Flexural deformities of the distal interphalangeal joint (clubfeet) - a review. *Equine Vet Educ*, 24(5), pp.260-68.
- O'Grady, S. & Dryden, V., 2012. Farriery for the hoof with a high heel or club foot. *Vet Clin North Am Equine Pract.*, 28(2), pp.365-79.
- O'Grady, S. & Poupard, D., 2003. Physiologic Horseshoeing. *J Equine Vet Sci*, 23, pp.123-24.
- O'Grady, S., 2010. Farriery for Chronic Laminitis. *Vet Clin Equine*, (26), pp.407-23.
- O'Grady, S. & Parks, A., 2008. Farriery options for acute and chronic laminitis. In *Am Assoc of Equine Pract.*, 2008.
- Ostblom, L., Lund, C. & Malsen, F., 1984. Navicular bone disease: results of treatment using egg-bbar shoeing technique. *Equine Vet J*, 16, p.203.
- Ostblom, L., Lund, C. & Melsen, F., 1982. Histologic study of navicular disease. *Equine Vet J*, (14), pp.199-202.
- Ovnicsek, G., Erfe, B. & Peters, D., 1995. Wild horse patterns offer a formula for preventing and treating lameness. *Proc Am Ass equine Practnrs*, (41), pp.258-60.
- Page, B. & Hagen, T., 2002. Breakover of the hoof and its effect on structures and forces within the foot. *J Equine Vet Sci*, 22(6), pp.258-64.
- Parks, A., 2003. Horseshoes and shoeing. In Ross, M. & Dyson, S. *Diagnosis and Management of Lameness in the Horse*. Missouri: Elsevier Science. p.262.
- Parks, A., 2012. *Aspects of Functional Anatomy of the Distal limb*. [Online] Available at: <http://www.equipodiatry.com/AspectsofFunctionalAnatomyoftheDistalLimb.html> [Accessed 30 August 2014].
- Parks, A. & O'Grady, S., 2008. Chronic laminitis. In N. Robinson & K. Sprayberry, eds. *Current therapy in equine medicine*. 6th ed. St. Louis (MO): WB Saunders. pp.550-60.
- Peloso, J. et al., 1996. Case-control study of risk factors for the development of laminitis in the contralateral limb in Equidae with unilateral lameness. *J Am Vet Med Assoc*, (290), pp.1746-49.
- Peters, D., 2010. Farriery for the Sport Horse—Principles and Techniques. In *Proc Annu Conv Am Assoc Equine Practnr*. Baltimore, 2010.
- Pollitt, C., 1996. Basement membrane pathology: a feature of equine laminitis. *Equine vet J*, 28(1), pp.38-46.

- Pollitt, C., 2008. Laminitis Medical Therapy. In *Equine Laminitis - Current Concepts*. RIRDC. pp.69-77.
- Pollitt, C., 2008. Radiology of laminitis. In *Equine Laminitis - Current Concepts*. RIRDC. pp.55-60.
- Pollitt, C., 2008. Therapeutic Shoeing. In *Equine Laminitis - Current Concepts*. RIRDC. pp.78-90.
- Pollitt, C., 2008. Venography of laminitis. In *Equine Laminitis - Current Concepts*. RIRDC. pp.61-68.
- Pollitt, C. & Davies, C., 1998. Equine laminitis: its development coincides with increased sublamellar blood flow. *Equine vet J Supp*, (26), pp.125-32.
- Pool, R., Meagher, D. & Stover, S., 1989. Pathophysiology of navicular syndrome. *Vet Clin North Am Equine Pract*, (5), pp.109-29.
- Pool, R., Meagher, D. & Stover, S., 1989. Pathophysiology of navicular syndrome. *Vet Clin North Am Equine Pract*, 5, pp.109-29.
- Ramey, D., 2014. *The Tildren® Follies*. [Online] Available at: <http://www.doctorramey.com/tildren/> [Accessed 16 November 2014].
- Ratzlaff, M. & White, K., 1989. Some biomechanical considerations of navicular disease. *Equine J Vet Sci*, (9), pp.149-53.
- Redden, R., 1998. In *Understanding laminitis: Your Guide to Horse Health, Care and Management*. Lexington, Kentucky: The Blood-horse inc. p.55.
- Redden, R., 2003. Hoof capsule distortion: understanding the mechanisms as a basis for rational management. *Vet Clin North Am Equine Prac*, (19), pp.443-63.
- Redden, R., 2004. Preventing Laminitis in the Contralateral Limb of Horses with Nonweight-Bearing Lameness. *Clin Tech in Equine P*, 3(1), pp.57-63.
- Reimersma, D., Bogert, v.d. & MO, J., 1996. Influence of shoeing on ground reaction forces and tendon strains in the forelimbs of ponies. *Equine Vet J*, (28), pp.126-32.
- Rijkenhuizen, A., Németh, F., Dik, K. & Goedegebuure, S., 1989. The arterial supply of the navicular bone in adult horses with navicular disease. *Equine Vet J*, 21(6), pp.418-24.
- Rooney, J., 1969. *Biomechanics of lameness in horses*. Baltimore: Williams & Wilkins.
- Rose, R., Allen, J., Hodgson, D. & Kohnke, J., 1983. Studies on isoxsuprine hydrochloride for the treatment of navicular disease. *Equine Vet J*, 15(3), pp.238-43.
- Schmotzer, W., 2011. *The Club Foot*. [Online] Available at: <http://www.bendequine.com/documents/TheClubFoot.pdf> [Accessed 21 October 2014].
- Sendel, T. & Thomason, J., 2012. *Horse Foot Health*. [Online] Available at: <http://www.omafra.gov.on.ca/english/livestock/horses/facts/12-019.htm> [Accessed 30 August 2014].

- Stashak, T., 1987. *Adams' lameness in horses*. Philadelphia: Lea & Febiger.
- Stone, W. & Merritt, K., 2009. A review of the etiology, treatment and a new approach to club feet. In *Proc Am Assoc Equine Practnr Focus on the Equine Foot*. Columbus (OH), 2009.
- Tarr, S., Butler, D. & Shideler, R., 1993. Successful treatment of a horse with chronic, severe flexural deformity of the distal interphalangeal joint: A case report. *J Equine Vet*, 13(12), pp.711-14.
- The Outlaw Shoe, 2006. *The Outlaw Shoe (Glue On) Product*. [Online] Available at: <http://outlawshoe.com/outlawshoe-glueon-version-for-horses.php> [Accessed 22 October 2014].
- Thomason, J., 2007. The hoof as a smart structure: Is it smarter than us? In A. Floyd & R. Mansmann, eds. *Equine Podiatry*. 1st ed. Saunders. pp.46-53.
- Thomason, J., Biewener, A. & Bertram, J., 1992. Surface strain on the equine hoof wall in vivo: implications for the material design and functional morphology of the wall. *J Exp Biol*, (166), pp.145-68.
- Thompson, K., Cheung, T. & Silverman, M., 1993. The effect of toe angle on tendon, ligament and hoof wall strains in vitro. *J Equine Vet Sci*, (13), pp.651-54.
- Thomson, J., Biewener, A. & Bertram, J., 1992. Surface strain on the equine wall in vivo: implications for the aterial designs and functional morphology of the wall. *J Exp Biol*, (166), pp.145-68.
- Trotter, G., 1991. Therapy for navicular disease. *Compend Contin Edu*, (13), pp.1462-65.
- Turner, T., 1989. Diagnosis and treatment of the navicular syndrome in horses. *Vet Clin North Am [Equine Practice]*, 5(1), pp.131-44.
- Turner, T., 1992. The use of hoof measurements for the objective assessment of hoof balance. *Annu Cony Am Assoc Equine Pract*, pp.389-95.
- Turner, T., 1992. The use of hoof measurements for the objective assessment of hoof balance. In *Proceedings of the 38th Annual Convention of the American Association of Equine Practitioners.*, 1992.
- Turner, T., 1993. Inferior check desmotomy as a treatment for navicular disease. In *International Symposium on Podotrochlosis*. Dortmund, Germany, 1993.
- Turner, T., 1993. Role of hoof balance on navicular disease. In *International Symposium on Podotrochlosis*. Dortmund, Germany, 1993.
- Turner, T., 1996. Treatment strategies for palmar heel pain. *Ippologia*, (7), pp.39-42.
- Turner, T., 2003. Examination of the equine foot. *Vet Clin Borth Am Equine Practice*, 19, pp.309-32.
- Turner, T., 2007. Caudal Hoof Lameness. In A. Floyd & R. Mansmann, eds. *Equine Podiatry*. 1st ed. Saunders. pp.294-312.

- Turner, T. & Fessler, J., 1982. The anatomic, pathological and radiographic aspects of navicular disease. *Comp Contin Edu*, 4, pp.350-53.
- Turner, T. & Stork, C., 1988. Hoof abnormalities and their relation to lameness. In *Proc 34th Annu Conv Am Assoc Equine Practnr.*, 1988.
- van Eps, A. & Pollitt, C., 2004. Equine laminitis: cryotherapy reduces the severity of the acute lesion. *Equine Vet J*, (36), pp.255-60.
- van Heel, M., Barneveld, A., van Weeren, P. & Back, W., 2004. Dynamic pressure measurements for the detailed study of hoof balance: the effect of trimming. *Equine vet J*, (36), pp.778-82.
- van Heel, M. et al., 2006. Uneven feet in a foal may develop as a consequence of lateral grazing behavior induced by conformational traits. *Equine Vet J*, (38), pp.646-51.
- van Heel, M. et al., 2005. Changes in location of centre of pressure and hoof-unrollment pattern in relation to an 8-week shoeing interval in the horse. *Equine vet J*, (37), pp.536-40.
- Walmsley, E., Anderson, G. & Adkins, A., 2001. Retrospective study of outcome following desmotomy of the accessory ligament of the deep digital flexor tendon for type 1 flexural deformity in Thoroughbreds. *Aust Vet J*, 89(9), pp.265-68.
- Watts, K. & Chatterton, N., 2004. A review of factors affecting carbohydrate levels in forage. *J Equine Vet Sci*, (24), pp.84-86.
- White, N., 1995. Ultrasound-guided transection of the accessory ligament of the deep digital flexor muscle (distal check ligament desmotomy) in horses. *Vet Surg*, (24), pp.373-78.
- Willemen, M., Savelberg, H. & Barneveld, A., 1999. The effect of orthopaedic shoeing on the force exerted by the deep digital flexor tendon on the navicular bone in horses. *Equine vet J*, (31), pp.25-30.
- Wilson, A., McGuignan, M., Fouracre, L. & MacMahon, L., 2001. The force and contact stress on the navicular bone during trot locomotion in sound horses and horses with navicular disease. *Equine vet J*, (32), pp.159-65.
- Wilson, A., Seelig, T., Shield, R. & Silverman, B., 1998. The effect of hoof imbalance on point of force application in the horse. *Equine vet J*, (30), pp.540-45.
- Wolfson, A. & Reed, S., 2008. *Ban on 'toe grab' spreads*. [Online] Available at: <http://archive.courier-journal.com/article/20080818/EXTRAS03/808180456/Ban-toe-grab-spreads> [Accessed 15 October 2014].
- Woodford, C., 2009. *"No Hoof; No Horse" - The Importance of Hoof Balance*. [Online] Available at: <http://www.vipsvet.net/articles/no-hoof.pdf> [Accessed 23 August 2014].
- Wright, I. & Douglas, J., 1993. Biomechanical considerations in the treatment of navicular disease. *Vet Rec*, (133), pp.109-14.

Wright, I., Kidd, L. & Thorp, B., 1998. Gross, histological and histomorphometric features of the navicular bone and related structures. *Equine Vet J*, 30, p.220.

Yiannikouris, S., Schneider, R., Sampson, S. & Roberts, G., 2011. Desmotomy of the accessory ligament of the deep digital flexor tendon in the forelimb of 24 horses 2 years and older. *Vet Surg*, (40), pp.272-76.

List of Figures

number	Figure	page
1	This rear view of a finite element model of the hoof capsule shows the structure in an unloaded (left) and loaded (right) state, showing that the force is spread over the area of contact of the laminar junction.	1
2	The phases of breakover and effect on the deep digital flexor tendon	2
3	Diagram of breakover location on sole measured from a radiograph	3
4	Relation of shoulder and hoof capsule angle	5
5	Straight (left), broken-back (centre) and broken-forward (right) hoof-pastern angle	6
6	Whilst resting, the GRF (grey arrow) is dorsal to the centre of rotation of the distal interphalangeal joint to create an extensor moment which is opposed by the equal and opposite flexor moment created by the deep digital flexor tendon to keep the foot stationary	8
7	The moment created on either side of centre of articulation	8
8	Side view of the foot	10
9	Lateromedial schematic view of 'normal' front foot of a healthy horse, with variations depending on the size of the horse	13
10	This schematic lateromedial view indicates which parameters (red) can be influenced by the farrier during a trimming session	15
11	A frontal section through the frog's apex shows the thickness of the insensitive sole	17
12	European Standard nails available for purchase	18
13	The graph shows the mean slip distance for each limb with (dark) and without (light) a lateral stud on each shoe, with all four limbs showing a significant decrease in mean slip distance in six horses cantering under their normal rider in a straight line on a grass surface	19
14	The dished appearance of the hoof wall, typical for club foot	21
15	The shortening of the deep digital flexor tendon causes flexion at the distal interphalangeal joint	22
16	This drawing shows the lateral and ground surface view of the foot following trimming an application of reverse wedge made out of composite and aluminium	25
17	A wedge pad placed under the foot's toe can be used to estimate the amount of heel which can be trimmed away without too much stress on the deep digital flexor tendon	27
18	Placing the trimmed foot palmar to the contralateral limb gives a good indication of how much the muscle tendon unit has shortened, visible at the gap between the ground and heels	27

19	To compensate for the shortening of the deep digital flexor tendon described in Fig 18, a wedge shoe, degree pad or bar wedge should be placed between the heels of the foot and the shoe	28
20	Pre- and post-surgical radiographs following transaction of the check carpal ligament in a horse with flexural deformity of the coffin joint	29
21	A dorsopalmar view of the navicular bone of a horse with navicular syndrome shows the lollypop-shaped synovial fossae on the distal border (arrows) and loss of the normal shape of the navicular bone due to enthesopathy of the extremity	31
22	This type of shoe provides protection and stability and reduces stress on the navicular bone	36
23	Picture showing the separation of the coffin bone from the dorsal hoof wall	38
24	A lateromedial radiograph of a normal foot with a radiopaque mark to show the dorsal hoof wall to allow for more accurate measurements	38
25	The arrowed radiolucent lines show that the coffin bone separated from the lamellae of the medial and lateral hoof wall in the dorsoproximal-palmarodistal 'standing' view	39
26	This image shows the venogram technique with the extension tube placed in the arrowed digital vein	41
27	Venograph with all three points of measurement	42
28	Ice bath in stocks for elongated icing of the feet	44
29	Two different planes are formed following farriery on the dorsal and palmar aspects of the ground surface	46
30	This foam sandwich is composed out of the compressed first foam block (A) which is trimmed and taped onto a second block (B). The shaded area should not be loaded	47
31	The Steward clog provides easy breakover whilst protecting the sole	48
32	Dorsal (A) and lateral (B) views show a 2cm wide groove below the under the coronet and resection of the distal toe	48
33	The heart bar shoe must be arranged in such a way that the frog plate (F) is above the level of the shoe's branches to apply even pressure over the entire frog. A rolled toe eases breakover	50
34	Radiography to fit the heart bar shoe with correct positioning	51
35	This is a glue on 'Outlaw shoe' which redistributes the weight evenly over the dorsal two-thirds of the foot when standing. By using a 5° wedge, it provides temporary relief to the flexor tendons, especially in the acute stage	51
36	Components of the equine digital support system: the Natural Balance shoe (A), plastic pad with built in frog plate (B), additional frog inserts (C) and wedge rails (D)	52
37	Illustration demonstrating the negative effects of the toe grab	57

38	The use of the Dalric B1 cuff to treat a young foal's coffin joint contracture	58
39	This horse evidently has mismatched feet, not club foot	60
40	The three forms of displacement of the distal phalanx	62
41	This radiograph of a foot with chronic and severe laminitis shows the effect of the coffin bone sinking (deficit at the dorsal coronet near the white arrow), the radiopaque line and the distal phalanx approaching the solar surface (black arrow)	62