

Department of Obstetrics and Food Animal Medicine
University of Veterinary Medicine Budapest



Clinical Relevance of Anti-Müllerian Hormone
evaluation in small animal practice

By
Tuva Regine N. Dahl

Supervisor:
Dr. Linda Müller, PhD, Assistant Professor

Budapest, Hungary
2023

1 Abstract

There have during the later years been done more research on the use of anti-Müllerian hormone (AMH) as a diagnostic tool in dogs and cats, of both female and male. There are still many uses of AMH that is not confirmed, but they are showing promising results in the few studies done. More research needs to be done about the use of AMH to confirm the results in many of the studies. The aim of this paper is to get an overview in the usefulness of AMH concentration as a diagnostic marker in small animal medicine. It has shown to be a helpful marker in different clinical disorders and may be used more frequently in small animal clinics as a potential marker for diseases related to gonadal disorders.

2 Table of content

1	<i>Abstract</i>	2
3	<i>Abbreviations</i>	4
4	<i>Introduction</i>	5
5	<i>Objectives/questions</i>	5
6	<i>Literature review</i>	6
6.1	The physiology of anti-Müllerian hormone	6
6.2	The use of AMH as a diagnostic marker in dogs and cats	7
6.3	Diagnostic tests available for detecting AMH	8
6.4	Anti-müllerian hormone in human medicine	9
7	<i>Methods</i>	10
8	<i>Result</i>	11
8.1	The use of Anti-Müllerian hormone in bitches	11
8.1.1	Intact or spayed bitches.....	11
8.1.2	Detecting the AMH concentration during the estrus cycle in female dogs	12
8.1.3	Granulosa cell tumor.....	14
8.1.4	Ovarian remnant syndrome and ovarian cysts	15
8.1.5	Prediction of litter size in bitches.....	16
8.2	The clinical relevance of anti-Müllerian hormone in male dogs	17
8.2.1	Castrated or intact male dogs.....	17
8.2.2	Sertoli cell tumor.....	17
8.2.3	Semen quality of male dogs	18
8.2.4	Cryptorchidism	18
8.2.5	Disorders of sexual development.....	19
8.3	The clinical relevance of anti-müllerian hormone in queens	19
8.3.1	AMH concentration of spayed or intact queens.....	19
8.3.2	Ovarian remnant syndrome and ovarian cysts in female cats.....	20
8.3.3	Anti-Müllerian hormone concentration in the oestrus cycle of the queen.....	21
8.3.4	Anti-Müllerian hormone concentration according to the age and pubertal stage of the female cat	22
8.4	The clinical relevance of anti-müllerian hormone in male cats	23
8.4.1	AMH concentration in castrated or intact male cats	23
8.4.2	Anti-Müllerian hormone concentration according to the age of the male cat	24
9	<i>Discussion and conclusion</i>	24
10	<i>Summary</i>	27
11	<i>References</i>	28

3 Abbreviations

AMH – Anti-Müllerian hormone

ORS – Ovary remnant syndrome

SCT – Sertoli cell tumor

GCT – Granulosa Cell tumor

PCOS - polycystic ovarian syndrome

ELISA – Enzyme linked immunosorbent assay

AN – Anoestrus

LP - Luteal phase

FP - Follicular phase

IOT - Immunotech

DSD – Disorders of sexual development

AI – Artificial insemination

LH – Luteinizing hormone

4 Introduction

Anti-Müllerian hormone is naturally produced and secreted by the granulosa cells in females and sertoli cells in males. It is inhibiting the development of the uterus in female fetuses, and it will lead to the development of the male genital tract in mammals [8, 19]. AMH concentration have been known and used in human medicine over a longer period of time. It has been proven to be a useful diagnostic method to detect ovarian reserve and menopause in women, and it have also shown promising results in the detection of polycystic ovarian syndrome and primary ovarian insufficiency [23]. It has been more commonly known and used during the later years, and especially in connection with detecting fertility status in females [18].

Anti-Müllerian hormone is present in both female and male dogs and cats. The value of AMH may vary slightly in baseline value depending on the age of the animal and depending on if it is a male or female, dog or cat [33]. The use of anti-Müllerian hormone as a diagnostic tool can be useful to diagnose reproductive disease. It has shown it can also be a helpful marker to detect where in the estrus cycle the bitch is in due to its increased value in female dogs during the late anestrus and up until proestrus about 6 days before estrus and may be used in addition to progesterone and LH [42]. It may also be useful detecting the oestrus in felines, but more research should be done in this area [12]. AMH concentration as a diagnostic tool may help make it easier to diagnose ovarian remnant syndrome, or confirm if the dog or cat have gone through ovariectomy or ovariohysterectomy, are castrated or is intact [14, 33]. It could also potentially help diagnose sertoli cell tumor and granulosa cell tumor. It have also shown promising results as a marker in other gonadal related problems like semen quality, detecting ovarian cysts and possibly detect the litter size in bitches [10, 17, 18, 27, 33]. There have not been done much research on AMH in dogs and cats and the first serum AMH documented in research was detected in dogs and cats in 2011 [34]. Mainly this paper will focus on the diseases or conditions where the AMH concentration could be a helpful diagnostic parameter in dogs and cats of both sexes.

5 Objectives/questions

Anti-Müllerian hormone in small animal veterinary medicine practice have shown can be used in different ways to diagnose disease and conditions related to the gonads. It is not well known as a diagnostic method and the hormone is not well known by general veterinary

practitioners. This paper will give an overview of anti-Müllerian hormone and summarize the various research done with the use of anti-Müllerian hormone as a diagnostic marker in the clinical practice of small animal medicine focusing on dogs and cats of both sexes. As the AMH main task is the development of the male reproductive tract and stopping the development of the female reproductive tract, it may be used for other diagnostic purposes. The value of the AMH has shown to be a beneficial diagnostic parameter for detecting the gonadectomy status of the dogs and cats. Some other purposes of the hormone may be used for in diagnostic purposes is to detect ovarian remnant syndrome, granulosa cell tumor, Sertoli cell tumor [1, 8, 14, 18].

6 Literature review

6.1 The physiology of anti-Müllerian hormone

Anti-Müllerian hormone also known as Müllerian inhibiting hormone is a glycoprotein hormone which is produced in the granulosa cells in female and in Sertoli cells in males and secreted from here. This hormone is a part of the transforming growth factor- β subfamily [6].

In males the anti-Müllerian hormone will inhibit the formation of the uterus in the fetuses by inhibiting the development of the paramesonephric duct that in females are developing into the female reproductive tract, and instead the wolffian duct is maintained and will form the male reproductive tract by regression of the Müllerian duct [29, 44]. In males the androgen from the testis will maintain the wolffian duct also known as mesonephric duct [8]. The wolffian duct will form the vas deferens, epididymis and seminal vesicles [8, 16].

In females mammals the Müllerian duct, also called paramesonephric duct will develop into the uterus, ovaries, salpinx, cervix, and the upper two thirds of the vagina and the wolffian duct will regress [8, 33, 40]. The AMH are secreted in the granulosa cells of the follicles. Depending on the growth stage of the follicle in the ovary, the layers of granulosa cells changes, and the layers thickens as it gets closer to the small antral follicular stage. The antral follicles have the most layer, which is from two to six layers of granulosa cells and the highest level of AMH is secreted. After this stage ovulation or atresia of the follicle occur and the levels of AMH will decrease. [44]. As for females the secretion of AMH has shown to be highest during the pre-antral and antral follicular phase, and it could be due to the increase of granulosa cells. The secretion have shown to be absent in the primordial follicles,

but is present in the primary and secondary follicles as these contain layers of granulosa cells and the primordial follicles only contain pre-granulosa cells [44].

During the time until puberty in female dog there is only small secretion of AMH from the granulosa cells and the secretion will increase after puberty before it will start to decline again after the bitch turns four years old [17, 34, 38]. Female cats have shown to have a higher level of secretion of AMH when they are kittens up to 3 months old, and it will decline as they grow older and have a decreased value from when they turn 12 months old [36]. Male dogs and cats have a higher AMH levels in young animals compared to after the puberty. After puberty the levels are decreased, but still detectable. The highest value of anti-Müllerian hormone have been measured in uncastrated male cats [33, 40]. In female dogs the AMH levels have shown to decline after the bitch turn four years old. The levels have shown to vary during the oestrus cycle [33, 42]. During the anestrus and proestrus the values of AMH have shown to be significantly increased in non-pregnant bitches [42].

6.2 The use of AMH as a diagnostic marker in dogs and cats

In dogs and cats, female and male the AMH can be used to confirm if the animal is intact, castrated or spayed. There are certain cases this might be used as if an animal is adopted or rehomed and the surgical scar is not visible any other reason the owner and veterinarian may not know if the animal is spayed or castrated [33]. The lower AMH concentration is strongly related to a spayed or neutered dog or cat. If the serum AMH higher, it could be that there is ovarian or testicular tissue present, which could indicate that the animal has ORS or is cryptorchid, or that the dog or cat is not spayed or castrated [14, 33]. If the AMH shows a negative result more testing should be done to rule out the possibility that there is no gonadal tissue present as it is not a confirmation that the animal has an absence of gonadal tissue [34, 42]. Other methods used to determine residues of gonadal tissue could be ultrasonographic imaging, P4 and oestradiol sampling, exploratory surgery [14, 33].

Other use of AMH can be in granulosa cell tumor or sertoli cell tumor as the sertoli and granulosa cells are secreting the AMH. This will lead to a higher level of blood AMH concentration [18, 27]. It has been indicated that AMH concentration may also be used for detecting the semen quality in dogs, litter size of the bitch, and detecting cryptorchid male dogs and ovarian cysts in females [10, 13, 17].

6.3 Diagnostic tests available for detecting AMH

There have during the later years been developed more tests to detect the AMH levels. The tests available for detection of AMH levels in canine and felines are tests made for humans and newer assays are made for canines and can be used for felines. In the table below is an overview over the assays used to detect AMH in humans as well as dogs and cats.

Table 1

Table containing the available tests found to be used for testing of AMH levels in dogs and cats.

Tests available, species	Company, reference
Commercial ELISA, human	Immunotech (IOT) [28]
Commercial ELISA, human	Diagnostic System Labs (DSL)[28]
AMH Gen II, human	Beckman coulter[20, 28]
Commercial ELISA, canine	Ansh Lab[37, 38]
Commercial ELISA, canine	Spaycheck, Preventia diagnostic Inc.[33]
Chemiluminescence immunoassay, human	Roche[12]

Previously there have veterinarians only had access to a human AMH ELISA test, and chemiluminescence immunoassay have also been used and approved for detecting serum AMH in dogs and cats [12, 33]. Human AMH Gen II ELISA kit may be used for dogs and cats [2, 13]. It is a newer generation of the previous commercial ELISA tests from IOT and DSL [20, 28]. The ELISA from IOT was used for the Gen II ELISA to calibrate the test [20]. In a study done in cats Gen II Elisa have been proven to have a 100% sensitivity and specificity in female felines. This suggest that it could safely be used in felines [2].

During the later years companies have manage to produce a commercial ELISA test for serum AMH concentration in canines. One created by Ansh Labs but is so far only for research purposes only within the United States. The test for canines from Ansh Labs have at least been used since 2015 for research and shown good results[15, 17, 34, 42].

One study done did testing to evaluate if a commercially available qualitative serum AMH ELISA assay for canines could be used to differentiate the intact and spayed female dogs with the use of AMH concentration, they tested it on 39 intact and 30 spayed bitches in the

study and found that the specificity was at 100% and sensitivity at 97.4%. This was the Spaycheck AMH ELISA from Preventia diagnostics Inc [33], and it seem to be advantageous to use to detect the gonadal status in dogs.

The canine-specific AMH ELISA test have shown have a considerably higher specificity and sensitivity than the human-specific AMH ELISA [17]. This canine specific test would be preferred to use for detecting AMH as it has a higher specificity and sensitivity.

One study used a chemiluminescence immunoassay made for humans to detect AMH concentration in felines. The assay was approved for felines. It had a minimum detection limit of 0.01 ng/ml and a maximum of 22.96 ng/ml [12]. This could be disadvantageous as the levels above and below those values are not detected.

6.4 Anti-müllerian hormone in human medicine

AMH levels can provide information about a woman's reproductive health and may also help guide with fertility treatment options. AMH can be used for detecting the ovarian reserve in humans as the AMH concentration is related with the number of follicles that can potentially ovulate and the quality of the eggs [10, 21]. Studies show that the serum AMH concentration have relation to the number of antral follicles. The AMH will be increased as the number of antral follicles is higher. The highest level have shown to be during the second follicular stage, but they will secrete AMH from the primordial follicular stage and until the small antral follicular stage [44]. It is also proven that low serum AMH and poor ovarian response are correlated [35]. This will mean that the AMH can be a possible marker to detect ovarian reserve and fertility status in humans.

During menopause in humans the AMH levels have shown to decline significantly. Serum AMH concentrations can be used in humans to help diagnose of ovarian dysfunction like polycystic ovary syndrome and primary ovarian insufficiency. Studies have shown that the levels of women with PCOS have had increased levels of AMH compared to the control group [23, 44]. It was also discovered that the levels of serum AMH varied as depending on the size of the ovaries in the women with PCOS [23]. The reason for the high AMH concentration in PCOS has been proven to be due to high number of antral follicles [9], and as explained above the AMH secretion is higher when there is a larger pool of small antral follicles.

For granulosa cell tumor in human medicine the AMH concentration have been used to detect the progress after a surgical removal of the ovaries as well as detecting reoccurrence

of the GCT. In women with GCT the concentration is higher and after surgical removal of the tumor with the ovaries the AMH concentration will decrease again [22].

7 Methods

In this literature review paper, Google Scholar was mainly used to search for articles about anti-müllerian hormone and the clinical use of AMH in dogs and cats, but also Pubmed and science direct was used as webpages for this search. In addition to these web references a few books were used to gather some physiological explanations about anti-müllerian hormone from the textbook Cunningham's Textbook of Veterinary Physiology (Bradly G. Klein), and literature for the description of diseases like sertoli cell tumor, granulosa cell tumor and ovarian remnant syndrome in dogs and cats from the textbook Veterinary Reproduction and Obstetrics (David E. Noakes). Also a few reviews that were relevant for this research was used as a reference.

In the search terms for this paper, where it seemed fit the words "and" or "or" was used. Search words used for this paper included the following: anti-müllerian hormone; Müllerian inhibiting hormone; physiology; sertoli cell tumor; granulosa cell tumor; ovarian remnant syndrome; gonadectomy; estrus cycle; progesterone; oestradiol; dog; cat; bitch; female; feline; male; tomcat; queen; puberty; human; polycystic ovarian syndrome; spay; castrate; cryptorchid; ovariohysterectomy; litter size; semen quality; ELISA.

Articles was anti-Müllerian hormone concentration was used as a diagnostic tool in diseases related to the reproductive system of dogs and cats was considered to be used in this review. Most of the articles had control groups or the animals in the study were the control group which was considered as this would give a more accurate result in the studies. The tests used for detecting the AMH concentration in the animals was of importance as well as it could affect the values and result. As reviewing the studies that used different assays for testing the exact value of the AMH in the animals were not the biggest focus. Looking at the results of the studies it was chosen that the values were to be described as "higher/increased" or "lower/decreased" compared to the other in most cases.

The focus was to use the newer research from the last 4-5 years published online in the above-mentioned web pages, but since there have been limited research done in each topic some articles published from the earlier years were used as well for this systematic literature review. As a foundation for which topic that was chosen for this review

This paper tries to summarize the most common diseases and disorders that can be or possible be detected by the AMH concentration in dogs or cats. If possible, more than one article was used to get a better view of the result and a better conclusion if the AMH could be used as a diagnostic tool in each topic.

8 Result

This section will be summarizing the research literature found on the use of AMH in clinically relevant reproductive disorders connected to granulosa and sertoli cells and gonadal status of dogs and cats of both sexes. The sections are divided into species and sexes and with the different problems related to them. AMH concentration have not been confirmed to be useful in all the topics due to the lack of more research studies like for the semen quality in male dogs, litter size and size of the dog. These are used to give an overview of all the confirmed and possible use of AMH and are therefore included.

8.1 The use of Anti-Müllerian hormone in bitches

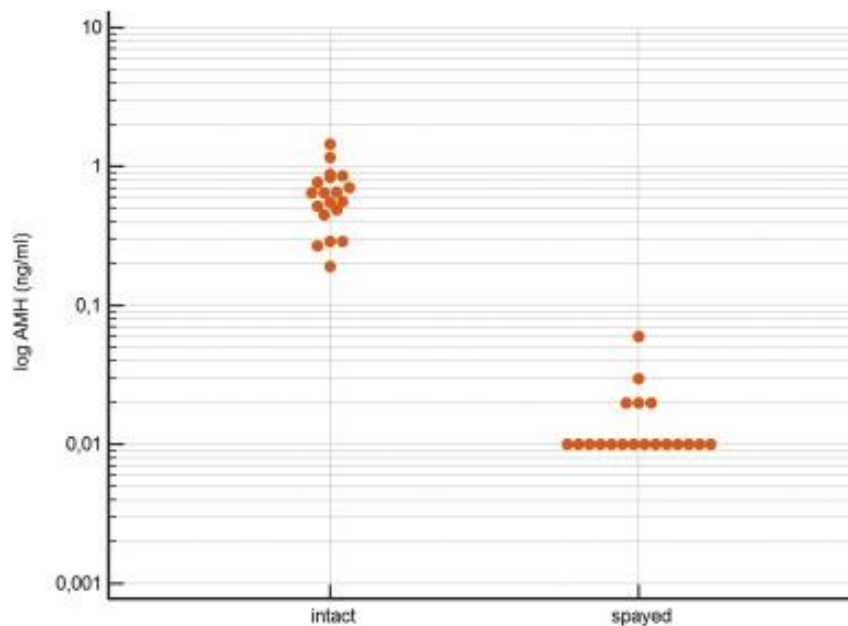
8.1.1 Intact or spayed bitches

The Anti-müllerian hormone have shown to be a good marker to differentiate the intact bitches from the spayed. The concentration of AMH will be significantly lower in the spayed compared to the intact dogs [33, 34, 42]. One study published in the Journal of Veterinary Diagnostic Investigations 2011 showed that human ELISA assay could be used to detect the gonadal status in a female dog. They had two studies about dogs gonadectomy status were the first was from dogs spayed earlier by different veterinarians where they looked at the AMH concentration of samples sent into the Diagnostic Center at Cornell University in Ithaca, New York, of the spayed dogs and compared the levels to samples from intact bitches. It showed the levels of AMH in the spayed bitches were lower than the levels in the intact. There were only one exemption were the level of a suspected spayed dog showed to be higher [34]. This could possibly be a disease related issue like ORS.

In the second study they did an AMH concentration check before and after spaying where they did the spaying at the Cornell University Hospital of Animals. In this study the had a larger number of young dogs down to the age of 3 months. The dogs between the age of 3-6 months showed a lower concentration of AMH before spaying and was therefore a less difference after the spaying, but they still showed a lower concentration of AMH after the

spay. The bitches above 6 months showed a greater difference in AMH concentration before and after spaying [34]. Both these studies published in the journal showed that AMH concentration could be a good diagnostic parameter to detect the gonadectomy status of the female dog.

Another study done to detect the AMH levels during the oestrus cycle was also testing the AMH concentration in 19 spayed and 19 intact bitches. It also showed if the bitch had been spayed for more than one year ago the level of AMH was 0.01 ng/ml with one exemption. The level of the bitches more recently spayed was a bit higher, but still significantly lower than the intact bitches with a level between 0.19-1.45 ng/ml [42]. In addition to AMH concentration they did a gynecological examination and blood progesterone measurements was done in both the spay/intact study and oestrogen cycle study [42].

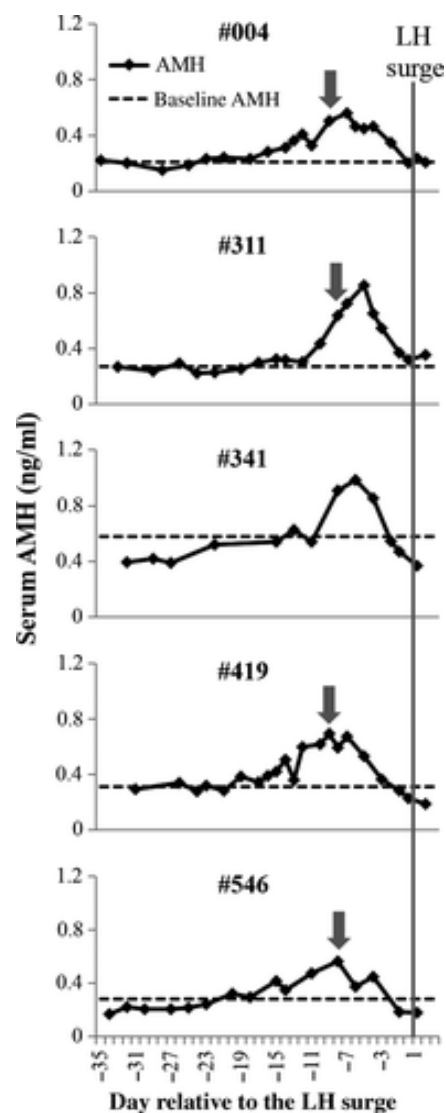


Figur 1: showing the difference in the AMH concentration in the intact and spayed bitches shown in a dot plot [42]

8.1.2 Detecting the AMH concentration during the estrus cycle in female dogs

During the oestrus cycle of a bitch the AMH is suspected to change due to its relation to number of antral follicles. A study showed the values of AMH was indeed increased during the anestrus and prooestrus as the number of antral follicles increased. They produced immunohistochemical data of AMH during the oestrus cycle of 5 female dogs between the age of 2,5 to 4,5 years. The immunoreactivity were the highest during the pre-antral and small antral follicles which increase in number during the anestrus and prooestrus [26]. The

decrease of the AMH around oestrus could possibly be a result of the development of the pre-ovulatory follicle or the atresia of the small antral follicle [26]. The study also showed that the baseline value of AMH may vary between different dogs even though they are about the same age. It also showed that AMH may be used to predict the LH surge by 8-9 days and may be used to predict when to use AI in dogs as of the progesterone and LH values could predict it but may be short time to prepare for the insemination as it only gives a two days' notice [26].



Figur 2: Showing the concentration of serum AMH of the five beagles in the study explained above, showing the LH surge, day 0, as the grey solid line, the dashed line shows the baseline AMH concentration. It also shows how the concentration of the AMH is increased related to the anestrus and prooestrus [26].

One more recent study done of female dogs to detect the oestrus cycle AMH concentration and differentiating the spayed from intact bitches from the AMH level was done using a total

of 59 female dogs [42]. As a preliminary test of the study, they looked at the AMH concentration in 19 intact bitches and 19 spayed of different breeds to detect if the AMH can be used to differentiate the intact from the spayed. They used a chemiluminescence immunoassay for testing the serum AMH which was approved for dogs [42].

The second study explained in this article was a study with beagles and labrador crossbreeds. The beagles in the study showed a higher baseline value compared to the labrador crossbreeds. AMH level during the oestrus cycle showed the highest value of serum AMH during the last three weeks until 6 days before ovulation and it decreased rapid during the last 3 days before ovulation. The lowest concentration was shown to be during the preovulatory, anestrus and metestrus and it varied in the bitches [42]. This may indicate that the AMH may be used as a possible marker to detect oestrus in the bitches. It also indicates that the baseline AMH may vary between the breeds.

8.1.3 Granulosa cell tumor

Granulosa cells of females produce AMH and in the case of granulosa cell tumors the value of AMH has shown to be increased significantly. Granulosa cell tumor (GCT) originate from the granulosa cells. It has been reported to be one of the most common ovarian tumors in bitches, and is also quite common in queens [32]. GCT may vary in size and can grow to become quite large [30]. In one study with 9 bitches with GCT the size varied from 0.3 to 15.0 cm [20]. The tumor may create an increase in hormonal activity resulting in secretion of oestrogen, anti-müllerian hormone and alpha-inhibin which may be used as a potential marker for diagnosing GCT [14, 15]. To get a definite diagnosis of the GCT a histopathological examination of the tumor have to be performed [15]. GCT rarely metastasize. Clinical signs of GCT may present as alopecia, continuous estrus, ascites and may also present with bone marrow suppression [14].

A study looking into the AMH levels in bitches with ovarian cysts and ovarian tumors was performed on 63 bitches with variable age from 1-15 years and different breeds. 14 of those bitches there were not any findings on the histopathological examination. The value of AMH appeared to be remarkably higher in the bitches with histopathologic confirmed GCT (n=9) compared to the other bitches with ovarian cysts or ovarian tumors like epithelial tumor, dysgeneromas and sarcoma. The aim of the study was to differentiate the GCT from other tumors using AMH. By the result of the AMH values of the GCT it ranged from 1.12 to ≤ 23 ng/ml compared to the other ovarian tumors and cyst which had AMH levels ranging from

0.11 up to 2.09 ng/ml [41]. This result confirmed that the AMH parameter could be a good diagnostic method to differentiate from the other types of tumors and for detecting the GCT.

8.1.4 Ovarian remnant syndrome and ovarian cysts

In female dogs or cats, AMH can be used to detect ovarian remnant syndrome (ORS). When a female dog or cat have gone through an ovariectomy or ovariohysterectomy (OHE) the serum AMH levels are highly reduced. If there are remnants of an ovary after the OHE, the value of AMH would be significantly higher due to the ovary tissue left during surgery [31, 42]. The bitches or queens that have a portion left of their ovary may return to oestrus after the OHE, this may present without getting the red vaginal discharge as they usually get during a normal oestrus if a complete hysterectomy is performed. Some of the symptoms of ORS the dog or cat may present with is symptoms of oestrus like swollen vulva, may have vaginal discharge usually when only ovariectomy is performed, they may also show sexual behavior and pseudopregnancy [31, 33].

The ORS does not necessarily occur right after the OHE, it may occur from 1 month or up to 10 years after the surgery and is highly variable [3]. A study showed that AMH does not increased in all cases with ORS. Due to the gonads are the only place where there is AMH production there is a possibility that if the ovarian remnant mostly contains luteal tissue the production of AMH might not be high enough to be detected in the blood. Corpa lutea does not produce AMH so in this case there are little production of the hormone [33].

The same study also shows that the use of both AMH and P4 as a diagnostic tool could be useful for the detection of ORS. For the detection of AMH levels, serum samples were taken for the qualitative serum AMH ELISA test available for dogs. For the P4 levels, serum was used in a chemiluminescent immunoassay test approved for the use in dogs. After testing the AMH and P4 levels in the dogs it showed that in some cases, the AMH was negative and the P4 was positive, and other cases the AMH was positive and the P4 negative, and some cases both were positive.

P4 test result	AMH test result		
	Positive	Inconclusive	Negative
Positive	25	6	6
Inconclusive	4	4	1
Negative	1	1	0

Figur 3: "Distribution of serum AMH and P4 test results for 48 spayed bitches with histologic confirmation of ORS" [33]

In those cases where both the P4 and AMH were negative there were no ovarian remnant detected during the exploratory surgery. Histological samples were gathered in 53 of cases where they did an exploratory laparotomy but only 48 were confirmed positive with ovarian remnant. Due to the lack of spayed dogs in the study that had gone through both testing of AMH, P4 and the exploratory surgery with the process of taking histological samples, there were only 2 bitches confirmed with all three negative result [33].

Studies have shown that serum AMH, human chorionic gonadotrophin hormone and Progesterone (P4) can be used as a diagnostic method for detecting ovarian remnant syndrome [5, 31, 33, 34]. It was acknowledged in one study from 2011 that serum AMH concentration alone could detect any presence of ovaries or ovary remnants by the use of a human-based ELISA test, but is said to have a high cost [34]. During the later years there have been developed a commercial ELISA test for serum AMH concentration in canines created by Ansh Labs but is available worldwide [2].

8.1.5 Prediction of litter size in bitches

Anti-müllerian hormone have shown to be a potential marker for determining the litter size in bitches. There have been studies looking at the size of the dog compared to the normal value of serum AMH compared to the dogs size and then compared it to the litter size of the bitch[17]. In the study they also found the mean AMH concentration in bitches above 4 years old is lower than in the bitches below 4 years of age [17].

According to one study done were they looked at the litter size and weight of the bitch, they could not definitely confirm if the AMH concentration could be used to determine the litter size. This may be due to a low number of animals in the trial as well as the AMH concentration have shown to possible be influenced by the age, body weight and their litter size [11].

8.2 The clinical relevance of anti-Müllerian hormone in male dogs

8.2.1 Castrated or intact male dogs

It may be useful to be able to detect the gonadal status in male dogs as some dogs may be cryptorchid or the dog have an unknown gonadal status. One study done at two institutes included 50 intact males and 48 castrated males in their study on the use of AMH concentration as a diagnostic tool to detect the castrated from the intact male dog [37]. The study showed a higher concentration of AMH in intact male dogs and a lower concentration in the neutered male dogs. They could confirm that the specificity and sensitivity was at a 100% in the study about the castrated and intact male dogs [37].

8.2.2 Sertoli cell tumor

AMH is secreted in male dogs and cats by sertoli cells. This means that AMH may be a potential biomarker for the detection of sertoli cell tumor (SCT) as the AMH is suspected to be higher in these cases [18]. Sertoli cell tumors are one of the more common tumors in male elderly dogs [1]. It is often known by the signs of feminization and are producing oestrogen. Some of the symptoms may be symmetrical alopecia, hyperpigmentation, penile atrophy, gynecomastia, prolapsed prepuce and attraction to males. This type of tumor may occur more often in cryptorchid dogs [18, 29]. The secretion of oestrogen can cause an obstructive uropathy due to squamous metaplasia of the prostate gland. During the rare cases where SCT causes metastasis, the metastatic tumors may also secrete oestradiol [30].

Oestradiol have been used as a marker for the SCT, but it is not a certain diagnostic method alone. It has been reported in cases where healthy dogs have oestradiol values above normal value and can be highly variable, and they may not show any relation of clinical signs of high oestradiol [1, 29]. Serum AMH may be considered as a diagnostic tool for this type of tumor due to the secretion of AMH by the sertoli cells, it has been known that the AMH can be a marker for young immature and neoplastic sertoli cells [4, 18]. It seems like it has not been many studies about the use of AMH as a diagnostic tool for Sertoli cell tumor in dogs. One study done to analyze if AMH can be used as a biomarker they compared dogs with a palpable testicular mass to healthy male dogs. The study showed promising results as 6 dogs with confirmed SCT had significantly increased levels of AMH [18].

A case study also showed the result of high AMH concentration in a dog with a tumor in a cryptorchid testicle on the right side, which was then confirmed as a sertoli cell tumor as

suspected due to the high oestradiol concentration. The concentration of AMH were decreased after they performed the castration of both testicles [1].

8.2.3 Semen quality of male dogs

AMH is thought to have a correlation with semen quality in male dogs. There was one study looking at the use of AMH concentration as a potential biomarker for the semen quality of 45 stud dogs. The results showed a negative relationship between serum AMH concentration and the semen quality. Both the morphology and motility of the sperm in the male dogs were negatively correlated to AMH concentration. The other spermatogenesis values did not seem to affect the AMH levels in any way [10]. A reason for increased AMH and the poor semen quality may be a result of abnormal sertoli cell function. The parameter may be used for detecting the sperm quality as if there is an increase of the AMH when there is a decrease in motility and morphology. Further studies need to be done to confirm this as this is until now the only study done about the relation of semen quality and AMH concentration [10].

8.2.4 Cryptorchidism

Cryptorchidism is when the testis has not fallen into the scrotum and it could remain in the abdomen, inguinal ring. Cryptorchid male dogs are prone to testicular neoplasia. One of those neoplasia could be sertoli cell tumor and as mentioned earlier it could increase the AMH concentration as the sertoli cells secrete AMH [18, 29]. In stallions with cryptorchidism it is proven that the AMH concentration is higher in the cryptorchid compared to the intact as well as in geldings [7]. A study was performed on dogs to detect if AMH concentrations were higher in cryptorchid canines. The study showed some higher levels of AMH concentrations in cryptorchid dogs, but the result was inconclusive as the levels of an intact dog also was in some dogs similar to some cryptorchids. They could confirm the presence of testicular tissue as the levels of both cryptorchid and intact dogs were higher than the castrated [13]. The AMH have shown to not be increased in all cases of cryptorchid male dogs [43]

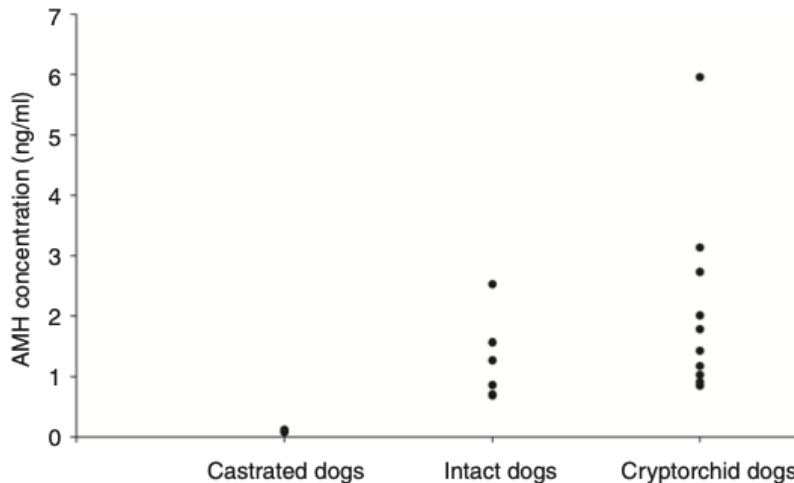


Figure 3: the concentration of AMH in castrated, intact and cryptorchid dogs [13].

8.2.5 Disorders of sexual development

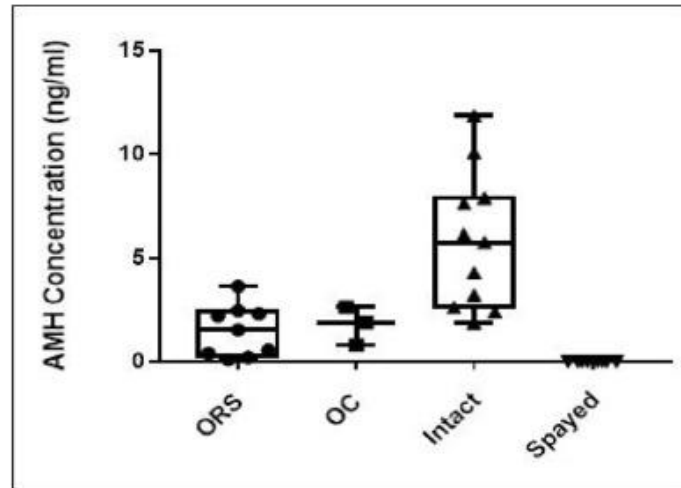
Disorders of sexual development is related to the different changes in the reproductive tract that can take place in a dog both female and male. It was suspected that anti-Müllerian hormone level could be used as a diagnostic tool in the detection of disorders of sexual development due to its relation to sertoli cells and it could detect testicular tissue in dogs. The AMH concentration was proven to be higher in the dogs with DSD compared to the intact dogs [43].

8.3 The clinical relevance of anti-müllerian hormone in queens

8.3.1 AMH concentration of spayed or intact queens

In cats, studies have shown that the concentration of AMH have been lower in the spayed compared to the intact female cats. One study could prove that the specificity and sensitivity were at 100% for confirming the female cat have gone through an ovariectomy or ovari hysterectomy or is intact using AMH concentration. They also showed the highest level of AMH were detected in the youngest female cats. The estrus cycle status was known in all intact female cats, and they used Busrelin to stimulate the female cats in both intact and spayed. This showed an increase in oestradiol, but did not appear to affect the concentration of AMH [2]. It has also been confirmed in an earlier study showing the AMH levels of 16 cats before and after spaying. It showed a very distinctive difference in the AMH concentration between when they were intact compared to when they were spayed. Three

cats had AMH levels in between the intact and spayed concentration and was diagnosed with ovarian remnant syndrome [34]. A newer study could also confirm that the levels of AMH in spayed female cats is significantly lower than the AMH concentration in intact female cats [14].



Figur 4: showing the concentration of AMH in spayed and intact cats as well as the AMH concentration in cats with ovarian remnant syndrome and ovarian cysts [14].

8.3.2 Ovarian remnant syndrome and ovarian cysts in female cats

A recent study in cats done at Hatay Mustafa Kemal University of veterinary medicine showed that the AMH concentration could be used as a diagnostic tool to detect spayed from intact queens. The levels of AMH are significantly low in the cats that are spayed compared to the intact cats. The study also explained that levels of serum AMH concentration in cats with ORS as well as cats with ovarian cysts will be notably increased [14]. But this will also mean that the AMH concentration is not the best diagnostic method to differentiate the ORS and ovarian cysts in cats.

The ovarian tissue left when a cat present with ORS may vary in size and therefore the values of AMH may also vary depending on the size of the ovarian remnant. It would in this case be difficult to differentiate the intact queen from a cat with ORS. Due to this the AMH alone cannot be used as a single diagnostic method for ORS [14], unless there is knowledge that the cat have been spayed. Other diagnostic methods for this could be ultrasonography, exploratory laparotomy, vaginal cytology in addition to anamnesis, usually the cat can present with estrus behavior [12, 14].

8.3.3 Anti-Müllerian hormone concentration in the oestrus cycle of the queen

A study from 2022 investigated the AMH concentration during the oestrus cycle. Five cycling queens, one pregnant and one acyclic cat were used in this investigation. The three young queens referred to is at the age of one and did not have their first heat when starting the study. The other cats were between the age of 1-3 years old and referred to as young adults[12]. The study showed during the anestrus the levels of AMH were at its highest and it was at its lowest during the oestrus and metoestrus. The difference in the values between the young adult and the young queens could suggest that the younger queens have a higher concentration of AMH compared to the adult cats. The acyclic cat showing the lowest level of AMH was confirmed with an ovarian cyst [12]. The author suggests that there should be done more research as there are still some uncertainties about the results. It could be confirmed that the oestrus cycles of the cats had a repeating pattern, but there were still high variations between the different cats[12].

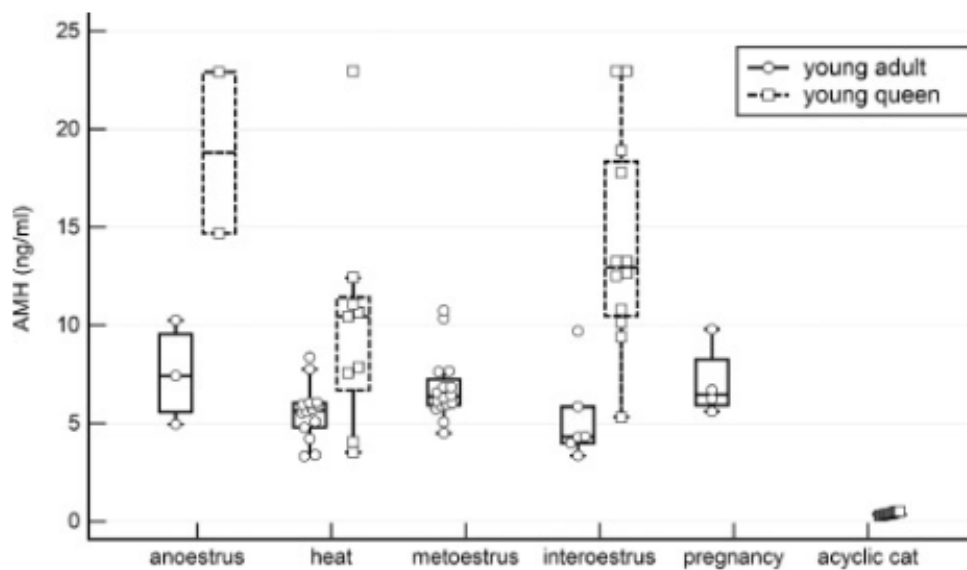


Figure 1: "Dot plot with an overlying box plot of the AMH concentration in the different cyclic stages of the young adult and young queens, of the pregnant cat and the acyclic cat"[12]

In a recent study done detecting AMH concentration in pregnant cats and cats in different stages of the oestrus cycle it showed that there were no significant difference in AMH concentration of the pregnant cat or non-pregnant cat in estrus or interestrus [15].

One study that researched the AMH concentration in queens could also determine the value of AMH in the cats in anoestrus were higher than the levels in the cats in follicular phase [21]. If comparing the box-plot below to the box-plot shown above they show a similar

pattern during the estrus cycles of the queens with the highest values during anoestrus and lower levels in the estrus and metoestrus.

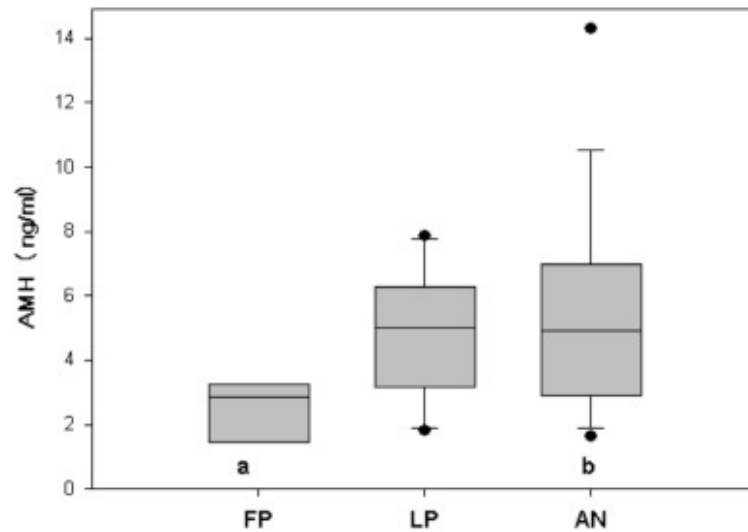


Figure 2: Anti-Müllerian value of 32 postpubertal queens showed in a box-plot [21]

8.3.4 Anti-Müllerian hormone concentration according to the age and pubertal stage of the female cat

In humans the level of AMH concentration in female neonates have been shown to be lower compared to the prepubertal and postpubertal [39]. One study has shown that similar to humans, the female cats have a lower concentration of AMH in the neonate stage of life and as for the cats in prepubertal stage of life the AMH concentration were at its highest before decreasing in the group of cats in postpubertal stage [21]. In the study they grouped the female cats according to the age of the cats. The AMH concentration were examined according to the age of the queen. The result showed a higher concentration of AMH in the queens below 12 months of age. The other age groups of 12 months and those above 12 months of age showed a lower level of AMH [21]. The study suggested that the reason for the value to decline from one year of age might be due to a gradual decline of the ovarian reserve as it have been shown in humans [9, 21].

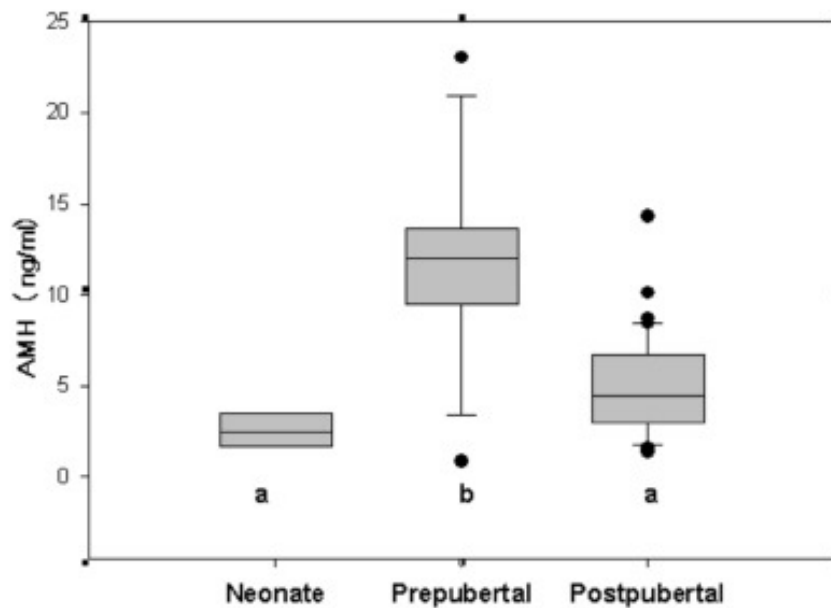


Figure 3: "Box-plot of anti-Müllerian hormone of 68 neonatal, prepubertal and postpubertal female cats. Different letters below the boxes represents $P < 0.01$." [21]

Another study where they investigated the age compared to the levels of AMH showed that the youngest female cats had the highest concentration. The level seemed to decrease from one year of age and above. The study only contained 16 cats and most of them were 1 year or younger [2].

8.4 The clinical relevance of anti-müllerian hormone in male cats

8.4.1 AMH concentration in castrated or intact male cats

It has been proven that AMH concentration can be used to detect intact from castrated male cats [2]. One study detecting concentration of AMH in intact and castrated cats showed that castrated male cats had a concentration below 0.14 ng/ml, and the intact males had significantly higher concentration of AMH. The concentration in intact males could seem to vary between the cats depending on their age and individual, but the oldest male cat in this study was 4 years old. The youngest cats had a higher level of AMH at 81.3 ng/ml and the lowest concentration for intact males were 4.8 ng/ml [2].

8.4.2 Anti-Müllerian hormone concentration according to the age of the male cat

A study done on gonadectomy status in cats showed that the youngest male cats had the highest AMH concentration. The older cats showed a much lower concentration compared to the two youngest [2]. According to one recent study done with detecting the AMH concentration in cats of different ages it was discovered that the male kittens have a higher concentration of AMH compared to the female kittens. The level of AMH concentration in the neonatal male kittens were not detectable by the assay used. In this study they only included 5 neonatal male kittens to compare them to the female. Their main focus on the study was to detect the AMH concentration in the female cats [21]. No specific study has focused on this topic and a proper study should be done to determine if AMH concentration in male cats is age related.

9 Discussion and conclusion

Anti-müllerian hormone as a clinical parameter has not shown to be very commonly used in small animal veterinary medicine. The studies related to this topic have been mostly done from 2011. Most studies seem to have been done on detecting gonadal status and ovarian remnant syndrome by the AMH concentration and most studies have shown to focus mostly on female dogs and cats. For some diseases and conditions, the AMH have proven to be a very beneficial parameter both alone and in addition to other parameters depending on the suspected diagnosis.

In the studies about the oestrus detection in dogs it showed that AMH level during the oestrus cycle showed the highest value of serum AMH during anestrus and proestrus. It showed the level to be highest the last three weeks until 6 days before ovulation and it declined rapidly during the last 3 days before ovulation [42]. P4 and LH values can be used for detection of oestrus, and it could be detected 2 days before ovulation. This gives a limited time for breeding [26]. AMH have shown to be a good additional parameter to detect the estrus as the values is high up to 6 days before ovulation [42].

For the studies detecting gonadal status in dogs, the different studies showed a small difference in the cutoff value of AMH concentration depending on the assay used.

The results of the studies done on gonadectomy status of dogs showed a very certain diagnosis using AMH concentration of intact, castrated or spayed dog. The AMH value of the different gonadectomy status showed that the values were significantly higher in intact

dogs compared to the spayed or castrated [33, 34, 37]. In both female and male cats it showed similar results as dogs of higher AMH levels in intact cats and lower levels in the spayed or castrated [2, 14, 34]. The studies in this topic also showed a high specificity and sensitivity of the testing and mostly 100% even though not all of them used the same tests [14, 33, 34, 37]. If the value were seem to be higher in those female dogs or cats it was suspected and confirmed ovarian remnant syndrome [14, 33, 34]. Due to the findings in these studies, it is suggested that AMH concentration could be beneficial as a diagnostic tool to detect the gonadal status of dogs and cats of both sexes.

AMH concentration has proven to be a remarkable additional diagnostic tool for detecting ORS as it shows an increase in AMH levels and if the animal is known to be spayed it could be a quite good parameter alone. If the gonadectomy status is unknown higher levels of AMH could also indicate an intact female dog or cat [14, 33]. Since it has not been proven to be a good parameter to use alone in every case to detect ORS it should be used as an additional diagnostic method to detect the disease. It could be used with P4 concentration as it was discovered in one study that if P4 and AMH concentration together showed a negative test it was unlikely that the dog or cat was confirmed with ORS. If one of them were positive and one negative it could mean that the dog or cat had ovarian remnant syndrome [14, 33]. In cats it was shown in one study that the values of AMH was overlapping in cats diagnosed with ovarian cysts and those with ovarian remnant syndrome [14].

AMH concentration in dogs and cats with granulosa cell tumor were presumed to have higher levels of AMH in dogs and cats as it have been proven to be higher in humans with GCT [22]. Studies have confirmed that AMH may be used as a parameter to detect the granulosa cell tumor in female dogs due to its significantly high concentration of serum AMH as the granulosa cells are the producer of the AMH [27, 32].

Sertoli cell tumors in dogs have shown to be one of the more common testicular tumors. Earlier the estradiol has been used as a parameter to detect the tumor as the tumor often have a secretion of this hormone. One study showed an increase in the levels of AMH in the dogs with SCT. One case study had the same result when detecting a SCT in a cryptorchid testicle[1]. This could possibly confirm the use of AMH as parameter for detecting the SCT, but more research should be done to confirm this. It has though shown to be a good additional parameter for the diagnosing of this type of tumor.

For the study about the semen quality the result could show that there was an increase in the AMH concentration when the semen morphology and motility were of low quality [10]. As this study is suggested to be the first on this topic and the age could influence result of AMH

concentration baseline [10], more research should be done to confirm this study. More research should be done in the studies about cryptorchidism in male dogs and litter size in bitches as well as it showed promising results using AMH levels [13, 17].

The AMH concentration have in a couple studies shown to vary depending on the age of the dog or cat. This may be thought to take into consideration when using AMH as a diagnostic parameter [2, 21].

In male cats the only use of AMH concentration that was found during the research was about detecting the castrated from the intact tomcat. In the studies about this topic, the results showed that the use of AMH concentration to detect the gonadectomy status in male cats was beneficial. It could be thought that AMH concentration could be a useful diagnostic tool for detecting sertoli cell tumors in cats as well as for dogs, but there were no such research to be found, and it is not very common for tomcats to have testicular tumors and even less common with sertoli cell tumor [24, 29]. Before the study done by Axné and Ström Holst in 2015, there have not been published any research articles about AMH concentration in male cats and it seems like there is not many published about male cats after this article as well. More recent there have not been more than a few research where the male cat were also in focus [2].

As anti-Müllerian hormone concentration can be detected by a blood sample and an assay made for AMH it has shown to be a simple diagnostic method, and if it can be used as a parameter in more disorders it could possibly make it easier for veterinarians to detect certain reproductive disorders. A larger number of studies should be performed in some of the topics to get a better result and to confirm is AMH concentration can be used as a diagnostic tool or as an additional diagnostic parameter. There should be a standard assay for detecting AMH levels in dogs and cats as it could give a more accurate result when comparing the studies.

10 Summary

The main purpose of this paper is to summarize the clinical use of anti-müllerian hormone as a diagnostic method in small animal veterinary practice. Due to difficulties diagnosing certain conditions there might be need for additional diagnostic tools in some diseases. AMH can be used as a single marker or an additional diagnostic tool to determine conditions related to the production of AMH in the granulosa cells and sertoli cells. There have during the last couple decades been done more research in the field of using AMH as a diagnostic method in conditions like ovarian remnant syndrome, sertoli cell tumor, granulosa cell tumor, detecting the estrus cycle in the bitch and queen. It may also be used for detecting if the animal is spayed/castrated or intact. AMH concentration have shown to be a very good parameter to detect the gonadectomy status of both dogs and cats of both sexes. It has also proven useful in the detection of ovarian remnant syndrome and granulosa cell tumor of female dogs and cats. The studies about AMH as a parameter for detecting oestrus have shown to be positive. It might not be the best as a parameter alone since the AMH value can vary in the different individuals, but due to a similar increase during the anestrus and early proestrus until 6 days before ovulation, it has shown to be useful as an additional parameter to P4 or LH concentration. It is also a beneficial parameter in detecting sertoli cell tumor and detecting if the male dog has any cryptorchid testicle, but more studies should probably be done in the latter one as the studies referred to in this review didn't detect if the cryptorchid testicle had any neoplasia such as sertoli cell tumor which then can increase the AMH significantly more.

The use of AMH in detecting semen quality, litter size has proven to be uncertain. Limited studies have been done on these topics, but the few studies done have shown it could possibly be a useful parameter, but more research must be done before confirming this.

11 References

1. Ano H, Hidaka Y, Katamoto H (2014) Evaluation of anti-Müllerian hormone in a dog with a Sertoli cell tumour. *Vet Dermatol* 25:142-e41. doi: 10.1111/vde.12112
2. Axner E, Ström Holst B (2015) Concentrations of anti-Müllerian hormone in the domestic cat. Relation with spay or neuter status and serum estradiol. *Theriogenology* 83:817–821. doi: 10.1016/j.theriogenology.2014.11.016
3. Ball RL, Birchard SJ, May LR, Threlfall WR, Young GS (2010) Ovarian remnant syndrome in dogs and cats: 21 cases (2000–2007). *Javma* 236:548–553. doi: 10.2460/javma.236.5.548
4. Banco B, Veronesi MC, Giudice C, Rota A, Grieco V (2012) Immunohistochemical Evaluation of the Expression of Anti-Müllerian Hormone in Mature, Immature and Neoplastic Canine Sertoli Cells. *Journal of Comparative Pathology* 146:18–23. doi: 10.1016/j.jcpa.2011.03.011
5. Buijtelts J, Beijerink N, Kooistra H, Dieleman S, Okkens A (2006) Effects of Gonadotrophin Releasing Hormone Administration on the Pituitary-Ovarian Axis in Anoestrous vs Ovariectomized Bitches. *Reprod Domest Anim* 41:555–561. doi: 10.1111/j.1439-0531.2006.00714.x
6. Cate RL, Mattaliano RJ, Hession C, Tizard R, Farber NM, Cheung A, Ninfa EG, Frey AZ, Gash DJ, Chow EP, Fisher RA, Bertoni JM, Torres G, Wallner BP, Ramachandran KL, Ragin RC, Manganaro TF, MacLaughlin DT, Donahoe PK (1986) Isolation of the bovine and human genes for müllerian inhibiting substance and expression of the human gene in animal cells. *Cell* 45:685–698. doi: 10.1016/0092-8674(86)90783-X
7. Claes A, Ball BA, Almeida J, Corbin CJ, Conley AJ (2013) Serum anti-Müllerian hormone concentrations in stallions: Developmental changes, seasonal variation, and differences between intact stallions, cryptorchid stallions, and geldings. *Theriogenology* 79:1229–1235. doi: 10.1016/j.theriogenology.2013.03.019
8. Cunningham JG, Klein BG (2013) Control of gonadal and gamete development. In: *Cunningham's textbook of veterinary physiology*, 5th ed. Elsevier/Saunders, St. Louis, Mo, pp 408–410
9. Dewailly D, Andersen CY, Balen A, Broekmans F, Dilaver N, Fanchin R, Griesinger G, Kelsey TW, La Marca A, Lambalk C, Mason H, Nelson SM, Visser JA, Wallace WH, Anderson RA (2014) The physiology and clinical utility of anti-Müllerian hormone in women. *Human Reproduction Update* 20:370–385. doi: 10.1093/humupd/dmt062
10. Domain G, Buczkowska J, Kalak P, Wydooghe E, Banchi P, Pascottini OB, Nizański W, Van Soom A (2022) Serum Anti-Müllerian Hormone: A Potential Semen Quality Biomarker in Stud Dogs? *Animals* 12:323. doi: 10.3390/ani12030323
11. Evci EC, Aslan S, Schäfer-Somi S, Ergene O, Saymer S, Darbaz I, Seyrek-İntaş K, Wehrend A (2023) Monitoring of canine pregnancy by considering Anti-Müllerian hormone, C-reactive protein, progesterone and complete blood count in pregnant and non-pregnant dogs. *Theriogenology* 195:69–76. doi: 10.1016/j.theriogenology.2022.10.020
12. Flock U, Reese S, Otzdorff C, Klein R, Walter B (2022) Anti-Müllerian hormone concentrations in queens throughout the estrous cycle. *Domestic Animal Endocrinology* 81:106749. doi: 10.1016/j.domaniend.2022.106749
13. Gharagozlou F, Youssefi R, Akbarinejad V, Mohammadkhani NI, Shahpoorzadeh T (2014) Anti-Müllerian hormone: a potential biomarker for differential diagnosis of cryptorchidism in dogs. *Veterinary Record* 175:460–460. doi: 10.1136/vr.102611
14. Gozer A, Bahan O, Dogruer G, Kutlu T (2023) Serum antimüllerian hormone concentrations in female cats. Relation with ovarian remnant syndrome, ovarian cysts and

- gonadectomy status. *Theriogenology* 200:106–113. doi: 10.1016/j.theriogenology.2023.02.010
15. Gültiken N, Yarim M, Aslan S, Gürler H, Yarim GF, Tuncay M, İnal S, Schäfer-Somi S (2022) Expression of Anti-Müllerian Hormone and Its Type 2 Receptor in the Ovary of Pregnant and Cyclic Domestic Cats. *Animals* 12:877. doi: 10.3390/ani12070877
 16. Hannema SE, Hughes IA (2007) Regulation of Wolffian Duct Development. *Horm Res Paediatr* 67:142–151. doi: 10.1159/000096644
 17. Hollinshead F, Walker C, Hanlon D (2017) Determination of the normal reference interval for anti-Müllerian hormone (AMH) in bitches and use of AMH as a potential predictor of litter size. *Reprod Dom Anim* 52:35–40. doi: 10.1111/rda.12822
 18. Holst BS, Dreimanis U (2015) Anti-Müllerian hormone: a potentially useful biomarker for the diagnosis of canine Sertoli cell tumours. *BMC Vet Res* 11:166. doi: 10.1186/s12917-015-0487-5
 19. Josso N, Lamarre I, Picard J-Y, Berta P, Davies N, Morichon N, Peschanski M, Jeny R (1993) Anti-Müllerian hormone in early human development. *Early Human Development* 33:91–99. doi: 10.1016/0378-3782(93)90204-8
 20. Kumar A, Kalra B, Patel A, McDavid L, Roudebush WE (2010) Development of a second generation anti-Müllerian hormone (AMH) ELISA. *Journal of Immunological Methods* 362:51–59. doi: 10.1016/j.jim.2010.08.011
 21. Lapuente C, Faya M, Blanco PG, Grisolia-Romero M, Marchetti C, Gobello C (2023) Anti-Müllerian hormone in queens: Serum concentrations and total ovarian follicle population. *Theriogenology* 197:111–115. doi: 10.1016/j.theriogenology.2022.11.033
 22. Marca AL, Volpe A (2007) The Anti-Mullerian hormone and ovarian cancer. *Human Reproduction Update* 13:265–273. doi: 10.1093/humupd/dml060
 23. Matsuzaki T, Munkhzaya M, Iwasa T, Tungalagsuvd A, Yano K, Mayila Y, Yanagihara R, Tokui T, Kato T, Kuwahara A, Matsui S, Irahara M (2017) Relationship between serum anti-Mullerian hormone and clinical parameters in polycystic ovary syndrome. *Endocr J* 64:531–541. doi: 10.1507/endocrj.EJ16-0501
 24. Miller MA, Hartnett SE, Ramos-Vara JA (2007) Interstitial Cell Tumor and Sertoli Cell Tumor in the Testis of a Cat. *Vet Pathol* 44:394–397. doi: 10.1354/vp.44-3-394
 25. Moolhuijsen LME, Visser JA (2020) Anti-Müllerian Hormone and Ovarian Reserve: Update on Assessing Ovarian Function. *The Journal of Clinical Endocrinology & Metabolism* 105:3361–3373. doi: 10.1210/clinem/dgaa513
 26. Nagashima J, Hansen B, Songsasen N, Travis A, Place N (2016) Anti-Müllerian Hormone in the Domestic Dog during the Anestrus to Oestrous Transition. *Reprod Dom Anim* 51:158–164. doi: 10.1111/rda.12660
 27. Nelissen S, Miller AD (2022) Comparison of anti-Müllerian hormone and inhibin immunolabeling in canine and equine granulosa cell tumors. *J VET Diagn Invest* 34:1027–1031. doi: 10.1177/10406387221124589
 28. Nelson SM, La Marca A (2011) The journey from the old to the new AMH assay: how to avoid getting lost in the values. *Reproductive BioMedicine Online* 23:411–420. doi: 10.1016/j.rbmo.2011.06.011
 29. Noakes DE (2009) Fertility, subfertility and infertility in male animals. In: *Veterinary reproduction and obstetrics*, 9. ed. Saunders Elsevier, London, p 745
 30. Noakes DE (2009) *Veterinary reproduction and obstetrics*, 9. ed. Saunders Elsevier, London
 31. Noakes DE (2009) Genital surgery in the bitch and queen, ovarian remnant syndrome. In: *Veterinary reproduction and obstetrics*, 9. ed. Saunders Elsevier, London, p 382
 32. Oviedo-Peñata CA, Hincapie L, Riaño-Benavides C, Maldonado-Estrada JG (2020)

Concomitant Presence of Ovarian Tumors (Teratoma and Granulosa Cell Tumor), and Pyometra in an English Bulldog Female Dog: A Case Report. *Front Vet Sci* 6:500. doi: 10.3389/fvets.2019.00500

33. Place NJ, Cheraskin J-L, Hansen BS (2019) Evaluation of combined assessments of serum anti-Müllerian hormone and progesterone concentrations for the diagnosis of ovarian remnant syndrome in dogs. *JAVMA* 254:1067–1072. doi: 10.2460/javma.254.9.1067
34. Place NJ, Hansen BS, Cheraskin J-L, Cudney SE, Flanders JA, Newmark AD, Barry B, Scarlett JM (2011) Measurement of serum anti-Müllerian hormone concentration in female dogs and cats before and after ovariohysterectomy. *J VET Diagn Invest* 23:524–527. doi: 10.1177/1040638711403428
35. van Rooij IAJ (2002) Serum anti-Müllerian hormone levels: a novel measure of ovarian reserve. *Human Reproduction* 17:3065–3071. doi: 10.1093/humrep/17.12.3065
36. Snoeck F, Sarrazin S, Wydooghe E, Van Soom A (2017) Age and anti-Müllerian hormone levels predict the success of in vitro maturation of cat oocytes. *Reprod Dom Anim* 52:98–102. doi: 10.1111/rda.12827
37. Themmen APN, Kalra B, Visser JA, Kumar A, Savjani G, de Gier J, Jaques S (2016) The use of anti-Müllerian hormone as diagnostic for gonadectomy status in dogs. *Theriogenology* 86:1467–1474. doi: 10.1016/j.theriogenology.2016.05.004
38. Turna Yilmaz Ö, Toydemir TSF, Kirsan I, Gunay Ucmak Z, Caliskan Karacam E (2015) Anti-Müllerian hormone as a diagnostic tool for ovarian remnant syndrome in bitches. *Vet Res Commun* 39:159–162. doi: 10.1007/s11259-015-9639-0
39. Visser JA, Themmen APN (2005) Anti-Müllerian hormone and folliculogenesis. *Molecular and Cellular Endocrinology* 234:81–86. doi: 10.1016/j.mce.2004.09.008
40. Walter B (2020) Anti-Müllerian hormone in dogs and cats reproduction. *Reprod Dom Anim* 55:26–31. doi: 10.1111/rda.13603
41. Walter B, Coelfen A, Jäger K, Reese S, Meyer-Lindenberg A, Aupperle-Lellbach H (2018) Anti-Müllerian hormone concentration in bitches with histopathologically diagnosed ovarian tumours and cysts. *Reprod Dom Anim* 53:784–792. doi: 10.1111/rda.13171
42. Walter B, Feulner H, Otzdorff C, Klein R, Reese S, Meyer-Lindenberg A (2019) Changes in anti-Müllerian hormone concentrations in bitches throughout the oestrous cycle. *Theriogenology* 127:114–119. doi: 10.1016/j.theriogenology.2019.01.007
43. Walter B, Flock U, Leykam C, Otzdorff C, Simmet K, Hecht W, Kempker L, Aupperle-Lellbach H, Reese S (2022) Serum anti-Müllerian hormone concentration as a diagnostic tool to identify testicular tissue in canine disorders of sexual development. *Domestic Animal Endocrinology* 78:106654. doi: 10.1016/j.domaniend.2021.106654
44. Weenen C (2004) Anti-Müllerian hormone expression pattern in the human ovary: potential implications for initial and cyclic follicle recruitment. *Molecular Human Reproduction* 10:77–83. doi: 10.1093/molehr/gah015

HuVetA
ELECTRONIC LICENSE AGREEMENT AND COPYRIGHT DECLARATION*

Name:..... Tuva Regine Nilssen. Dahl
Contact information (e-mail):..... tuvaregine@hotmail.com
Title of document (to be uploaded):.....
..... Clinical relevance of Anti-Müllerian hormone evaluation in small animal practice
.....
Publication data of document:..... 2023
Number of files submitted: 1

By accepting the present agreement the author or copyright owner grants non-exclusive license to HuVetA over the above mentioned document (including its abstract) to be converted to copy protected PDF format without changing its content, in order to archive, reproduce, and make accessible under the conditions specified below.

The author agrees that HuVetA may store more than one copy (accessible only to HuVetA administrators) of the licensed document exclusively for purposes of secure storage and backup, if necessary.

You state that the submission is your original work, and that you have the right to grant the rights contained in this license. You also state that your submission does not, to the best of your knowledge, infringe upon anyone's copyright. If the document has parts which you are not the copyright owner of, you have to indicate that you have obtained unrestricted permission from the copyright owner to grant the rights required by this Agreement, and that any such third-party owned material is clearly identified and acknowledged within the text of the licensed document.

The copyright owner defines the scope of access to the document stored in HuVetA as follows **(mark the appropriate box with an X)**:

- I grant unlimited online access,
- I grant access only through the intranet (IP range) of the University of Veterinary Medicine,
- I grant access only on one dedicated computer at the Ferenc Hutýra Library,
- I grant unlimited online access only to the bibliographic data and abstract of the document.

Please, define the **in-house accessibility of the document** by marking the below box with an **X**:

I grant in-house access (namely, reading the hard copy version of the document) at the Library.

If the preparation of the document to be uploaded was supported or sponsored by a firm or an organization, you also declare that you are entitled to sign the present Agreement concerning the document.

The operators of HuVetA do not assume any legal liability or responsibility towards the author/copyright holder/organizations in case somebody uses the material legally uploaded to HuVetA in a way that is unlawful.

Date: Budapest, 27.....day 03.....month 2023.....year


Author/copyright owner
signature

HuVetA Magyar Állatorvos-tudományi Archívum – Hungarian Veterinary Archive is an online veterinary repository operated by the Ferenc Hutýra Library, Archives and Museum. It is an electronic knowledge base which aims to collect, organize, store documents regarding Hungarian veterinary science and history, and make them searchable and accessible in line with current legal requirements and regulations.

HuVetA relies on the latest technology in order to provide easy searchability (by search engines, as well) and access to the full text document, whenever possible.

Based on the above, HuVetA aims to:

- *increase awareness of Hungarian veterinary science not only in Hungary, but also internationally;*
- *increase citation numbers of publications authored by Hungarian veterinarians, thus improve the impact factor of Hungarian veterinary journals;*
- *present the knowledge base of the University of Veterinary Medicine Budapest and its partners in a focussed way in order to improve the prestige of the Hungarian veterinary profession, and the competitiveness of the organizations in question;*
- *facilitate professional relations and collaboration;*
- *support open access.*



Thesis progress report for veterinary students

Name of student: Tuva Regine N. Dahl

Neptun code of the student: J2mnd7

Name and title of the supervisor: dr. Linda Müller

Department: Department of Obstetrics and Food Animal Medicine

Thesis title: Clinical Relevance of Anti-Müllerian Hormone evaluation in small animal practice

Consultation – 1st semester

	Timing			Topic / Remarks of the supervisor	Signature of the supervisor
	year	month	day		
1.	2021	08	02	Choosing the right topic	
2.	2021	09	17	Topic, thesis announcement form	
3.	2021	10	10	Methods of literature research	
4.	2022	04	20	Formal requirements	
5.	2022	04	20	Materials and methods	

Grade achieved at the end of the first semester: 5

Consultation – 2nd semester

	Timing			Topic / Remarks of the supervisor	Signature of the supervisor
	year	month	day		
1.	2023	01	27	Main parts, Table of content	
2.	2023	03	15	First draft	
3.	2023	03	22	Implemented second version	
4.	2023	03	26	Last version	
5.	2023	03	26	Last corrections	

Grade achieved at the end of the second semester: 5



The thesis meets the requirements of the Study and Examination Rules of the University and the Guide to Thesis Writing.

I accept the thesis and found suitable to defence,

signature of the supervisor

Signature of the student: *Tuva Dald*

Signature of the secretary of the department:

Date of handing the thesis in *27.03.2023*