

SZENT ISTVÁN UNIVERSITY
FACULTY OF VETERINARY SCIENCE
Clinic for Large Animals

Equine Laminitis

– A Review & Retrospective Study –

Anna-Christina Krampf

Dr. Tóth, Péter
Clinic for Large Animals
Szent István University, Budapest

Budapest, 2012

INDEX

INTRODUCTION	5
SURVEY OF LITERATURE	6
1. HISTORICAL PERSPECTIVE ON EQUINE LAMINITIS	6
2. ANATOMY AND HISTOLOGY OF THE HOOF	7
2.1. HOOF STRUCTURES	7
2.2. THE SUSPENSORY APPARATUS OF THE DISTAL PHALANX	8
2.3. BLOOD SUPPLY	9
3. STAGES OF LAMINITIS	9
4. CLINICAL SIGNS	10
4.1. ACUTE PHASE	10
OBEL GRADES OF LAMENESS	12
4.2. CHRONIC PHASE	13
5. PATHOLOGICAL CHANGES OF THE HOOF	14
5.1. HISTOLOGICAL CHANGES	14
5.2. CHRONIC LAMINITIS	16
ROTATION OF THE DISTAL PHALANX	17
DISTAL DISPLACEMENT	19
MEDIOLATERAL ROTATION	19
HOOF-HORN GROWTH AND THE LAMELLAR WEDGE	20
COMPLICATIONS	22
6. CAUSES AND RISK FACTORS	25
6.1. INFLAMMATORY AND ACUTE GASTROINTESTINAL DISEASES	25
CARBOHYDRATE OVERLOAD	25
ENDOTOXEMIA AND SEPSIS	27
INFLAMMATORY DISEASES	29
BLACK WALNUT SHAVINGS	30
6.2. METABOLIC AND ENDOCRINE DISTURBANCES	31
EQUINE METABOLIC SYNDROME	31
<i>INSULIN RESISTANCE</i>	32
<i>OBESITY</i>	35
PITUITARY PARS INTERMEDIA DYSFUNCTION	36

GLUCOCORTICOID THERAPY	38
6.3. TRAUMATIC CAUSES	39
SUPPORTING LIMB LAMINITIS	39
ROAD FOUNDER	40
7. PATHOPHYSIOLOGIC THEORIES	40
7.1. ENZYME ACTIVATION (MATRIX METALLOPROTEINASE ACTIVITY)	40
7.2. VASCULAR ALTERATIONS	42
VASOCONSTRICTION AND ISCHEMIA	42
VASODILATION	43
7.3. INFLAMMATORY MEDIATORS	44
7.4. MECHANICAL TRAUMA	45
8. DIAGNOSIS	45
8.1. RADIOLOGY	45
8.2. VENOGRAPHY	49
9. TREATMENT	51
9.1. MANAGEMENT AND CARE OF THE LAMINITIC HORSE	51
9.2. HOOF CARE AND THERAPEUTIC SHOEING	52
HOOF TRIMMING	52
HEEL ELEVATION	54
FROG AND SOLE SUPPORT	55
BREAKOVER POINT	56
SHOE TYPES	57
HOOF CASTING	61
9.3. MEDICATION	62
VASODILATORS AND ANTICOAGULANTS	62
ANTI-INFLAMMATORY DRUGS	63
PAIN MANAGEMENT	64
ANTIOXIDANTS	64
ENDOTOXIN NEUTRALIZATION	65
INSULIN SENSITIVITY MODULATION	65
METALLOPROTEINASE INHIBITORS	65
9.4. SURGICAL PROCEDURES	66
DORSAL HOOF WALL RESECTION	66
TOTAL HOOF WALL ABLATION	68
HOOF WALL DRILLING	69
DEEP DIGITAL FLEXOR TENOTOMY	69

9.5. ALTERNATIVE THERAPIES	70
CRYOTHERAPY	70
MAGGOT DEBRIDEMENT THERAPY	72
10. PREVENTION	73
<u>RETROSPECTIVE STUDY ON EQUINE LAMINITIS</u>	<u>75</u>
MATERIALS AND METHODS	75
RESULTS	76
DISCUSSION	81
SUMMARY	85
<u>APPENDICES</u>	<u>87</u>
APPENDIX 1 – ABBREVIATIONS & ACRONYMS	87
APPENDIX 2 – LIST OF REFERENCES	88
<u>ACKNOWLEDGEMENTS</u>	<u>97</u>
<u>COPYRIGHT DECLARATION</u>	<u>98</u>

INTRODUCTION

Laminitis is an extremely painful and crippling disease of the equine foot, which not uncommonly leads to euthanasia of the animal. However, experience has shown that equine laminitis is a systemic disease that manifests itself as pathological changes of the hoof, rather than just as a local medical condition (Hood, 1999). Literally, the word laminitis means ‘inflammation of the laminae’ that are part of the dermo-epidermal junction of the equine hoof. In fact, laminitis is characterized by a collapse of the suspensory apparatus of the equine digit. As the strong bond between hoof capsule and third phalanx loosens and finally dissolves, the distal phalanx becomes displaced by bodyweight pressure and locomotory stresses. However, the pathophysiological mechanism that causes the damage to the lamellar interface is still poorly understood (Pollitt, 2008). It seems to the author that the more people addressing this topic in depth, the greater the diversity of opinions.

The estimated frequency of equine laminitis is at 1.5% to 34% (Wylie et al., 2011) and laminitis is responsible for approximately 15% of all cases of equine lameness (Huntington et al., 2009). A general survey conducted in the United States in the year 2000 showed that the most commonly listed cause of laminitis was the pasture-induced type with an incidence of 45% (USDA, 2000). However, the occurrence of equine laminitis and its most frequent causes are seasonal and differ greatly depending on geographical locations.

The purpose of this thesis is to supply an impartial overview of equine laminitis, its causes, pathomechanisms and treatment opportunities, taking into account recent research findings. With the inclusion of a retrospective study of the cases of equine laminitis that occurred and were treated at the large animal clinic of Szent István University, Budapest, the author would like to determine the incidence and proportion of causes, progression of the laminitis cases and their outcomes over a 5-year period. This paper also serves as a reflection of personal experiences and includes a subjective approach to this topic, taking into consideration the knowledge that was acquired in the course of writing it.

SURVEY OF LITERATURE

1. HISTORICAL PERSPECTIVE ON EQUINE LAMINITIS

Heymering (2010) reports that the awareness of equine laminitis can be traced back to ancient history. It seems that in 380 BC the first veterinary document about laminitis was prepared by Xenophon. He made reference to the disease under the name 'barley surfeit', without describing its symptoms. In addition, the Greek philosopher and polymath Aristotle noted that laminitis could be associated with indigestion (Heymering, 2010). Hence, the Greek term for laminitis is 'Kritiasis', which means 'overfeeding of barley' (Bergsten, 2003). The first treatment for this condition was developed by Columella in 55 AD. Since he characterized laminitis as 'blood descending to the feet', Columella suggested bleeding of the affected limb as a possible therapy. At the beginning of the 4th century, Apsyrtus treated the disease, which he termed 'barley disease', with bleeding, exercise and dietary restriction, of which the last two are still employed in the management of horses suffering from equine metabolic syndrome, which predisposes them to laminitis. In 1548 therapeutic shoeing was at first thought by Fritzherbert to be advantageous in the treatment of laminitic horses or ponies. In the 18th, 19th and 20th centuries, several different types of shoeing and minor surgical procedures, like hoof wall resection and hoof wall grooving, were invented and modified. Herbert Mayo took a step forward, in 1823, in the understanding of the pathology of laminitis by describing the secondary laminae of the hoof. Heymering (2010) notes that the first one to succeed in inducing laminitis experimentally by carbohydrate overload was Åkerblom in 1934. And, in 1948, Nils Obel created a laminitis grading system, according to the severity of lameness and appearance of clinical symptoms, which is still widely used today (Heymering, 2010; Pollitt, 2008).

Especially during the last decades, intensive research has been done on laminitis worldwide. But despite a great deal of effort, equine laminitis still remains a devastating disease with an obscure pathophysiology, which can in many cases only be treated with minor effectiveness.

2. ANATOMY AND HISTOLOGY OF THE HOOF

2.1. HOOF STRUCTURES

The hoof is understood to consist of all anatomical structures encased by the hoof capsule plus the hoof capsule itself (Wissdorf et al., 2002). Besides tendons, cartilages and ligaments, these encapsulated structures are: the distal part of the second phalanx, the entire third phalanx, the navicular bone, the coffin joint and the navicular bursa. Important for the understanding of the pathology of laminitis are the morphology of the hoof capsule and especially the suspensory apparatus of the pedal bone.

The outermost layer of the hoof is the epidermis or hoof capsule, which can be divided into the following macroscopic structures: wall, white line, sole, frog and bars. From the outside to the inside the hoof wall consists of a thin shiny layer, called the tectorium or stratum externum, followed by the thick pigmented tubular hoof wall, called stratum medium, and finally the lamellar stratum internum (Pollitt, 2008; Wissdorf et al., 2002). The hoof horn consists mainly of mature fully keratinised cells, called anuclear corneocytes. Keratinocytes are produced by germinal cells located in the coronary band, white line, sole and frog. Therefore the new hoof wall is produced in the coronary band and grows in a proximo-distal direction. Maturing keratinocytes that become organized into thin, elongated cylinders form the hoof wall tubules. These tubules are embedded in a keratinized cellular matrix. The stratum internum of the epidermis forms approximately 550-600 primary epidermal lamellae, each sending out 100-200 secondary lamellae that perfectly interlock with the dermal lamellae of the corium (Pollitt, 2008; Wissdorf et al., 2002). This connection is called suspensory apparatus of the third phalanx and presents the site where the laminitic process starts.

Underlying the hoof wall is the dermis or corium. The dermis is a connective tissue matrix embedding numerous arteries, veins, capillaries and nerves. Its function is to nourish the avascular epidermis and to connect it with the periosteal surface of the distal phalanx. Whereas one side of the corium connects with the epidermis by means of a basement membrane, the other side is strongly attached to the pedal bone and the periosteum, respectively. Originating in the cortical bone of the distal phalanx, a vast number of collagen fibres spread into the dermal lamellae, subdividing into fine fibrils that penetrate through the crypts of the secondary lamellae to finally merge with the basement membrane of the epidermis (Pollitt, 1991; Wissdorf et al., 2002).

The coronary band is made up of the coronary corium, its basement membrane and the germinal epidermal cells. The coronary corium, lying in the coronary groove of the hoof wall,

has a large number of vascularized papillae projecting into the hoof tubules. It is firmly attached to the hoof cartilage and can be pulled distally by the sinking pedal bone in the case of chronic laminitis (Pollitt, 2008). Like the hoof wall, the sole, bars and frog consist of tubular horn and intertubular keratinised matrix. In contrast to the horn of the hoof wall, that of the frog and bars is softer. The tubules of the sole are arranged in a 45° angle to the ground surface and, consequently, parallel to the tubules of the dorsal hoof wall (Wissdorf et al., 2002).

2.2. THE SUSPENSORY APPARATUS OF THE DISTAL PHALANX

The basic elements of the suspensory apparatus of the pedal bone are the interlocking dermal and epidermal lamellae (**Figure 1**). Each primary lamella is covered with numerous smaller secondary lamellae to increase its surface (Pollitt, 2008; Wissdorf et al., 2002).

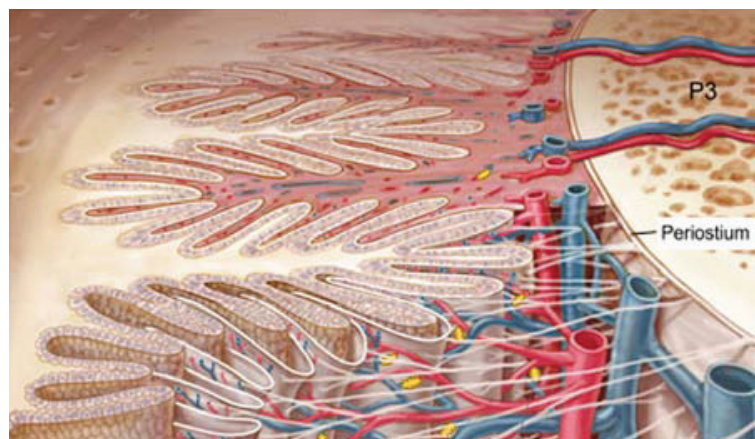


Figure 1: *Suspensory apparatus of the distal phalanx.* Source: Pollitt, 2008

From left to right, this image shows the epidermis with its primary and secondary lamellae, the thin basement membrane, the dermal connective tissue and vasculature, and the P3.

The basement membrane, a thin sheet of connective tissue fibres, coats the secondary epidermal lamellae and joins them to the digital corium. Its main components are fibrillar collagen type IV and a glycoprotein called laminin. In the cell membrane of the basal cells lining the secondary epidermal lamellae, a special type of attachment discs can be found. These discs, referred to as hemidesmosomes, are situated on the cell wall that rests upon the basement membrane. Each hemidesmosome sends out a large number of sub-microscopic anchoring filaments that are interwoven into the collagen matrix of the basement membrane. One anchoring filament consists of a single laminin molecule. Laminin and collagen are

known substrates of matrix metalloproteinases, a special type of connective-tissue enzymes (Pollitt, 2008). The relevance of these enzymes will be discussed later in the context of the pathophysiological background of laminitis.

2.3. BLOOD SUPPLY

The equine hoof is supplied with arterial blood by the final branch of the arteria digitalis palmaris/plantarum medialis and lateralis. These arteries reach the palmar/plantar surface of the third phalanx and enter the bone through the medial or lateral foramen soleare, before they merge to form the terminal arch. The terminal arch is the origin of several small arteries that nourish the parietal and solar corium. The bars and frog are supplied by the ramus tori digitalis, which arises from the palmar/plantar digital artery proximal to the hoof cartilage. The coronary band is vascularized by the arteria coronalis that arises from either the digital arteries or the rami tori digitales (Wissdorf et al., 2002). Blood is evacuated from the foot by the vena digitalis palmaris/plantarum medialis and lateralis. Venous blood is collected in the solar plexus, the coronary plexus, the sublamellar venous plexus and the circumflex vessels (Baldwin and Pollitt, 2010; Wissdorf et al., 2002). Those structures are helpful in determining the severity of chronic laminitis by means of venography (discussed in chapter 8.2).

The digital microcirculation of the equine foot is complemented by countless arteriovenous anastomoses (AVAs) that are supposed to have their role in local thermoregulation. Those anastomoses have low resistance compared with the nutrient capillaries. AVAs are capable of drawing more than 50% of total limb blood flow and therefore their dilation might be involved in the pathogenesis of laminitis¹ (Pollitt, 1991).

3. STAGES OF LAMINITIS

Depending on the overall pathological changes and the appearance of clinical symptoms, the course of equine laminitis can be subdivided into three stages (Pollitt, 2008; White, 2005).

The first stage is called the *prodromal* or *developmental phase*. It is the timespan between the onset of pathological lamellar changes and the appearance of the first clinical symptoms and takes approximately 1-2 days. Lamellar resolution is most often triggered by an underlying disease that occurs prior to the developmental phase. As horses have as yet shown no clinical

¹ Further information can be found under point 7.2.

signs, laminitis is usually not recognized during this timespan but can be suspected according to the type and severity of the underlying disease, if present.

The *acute phase* begins with the onset of clinical symptoms, such as increased hoof temperature, increased digital pulse and lameness and ends as soon as the distal phalanx displaces or after more than 72 hours of foot pain. Thereafter the disease is termed chronic. However, some horses do not move on to the chronic phase but seem to make a complete recovery after the acute stage (van Eps, 2010a).

Laminitis is considered chronic if the clinical symptoms continue for more than 72 hours or once the pedal bone displaces due to the mechanical collapse of its suspensory apparatus. The condition can either become compensated or uncompensated. *Compensated chronic laminitis* is defined by a stabilization of the distal phalanx without further descent or rotation and when new hoof wall and sole tissue are produced. If lamellar degeneration and hence the displacement of the distal phalanx continues, this is referred to as *uncompensated chronic laminitis*. Possible consequences are penetration of the sole by the pedal bone, abscess formation, osteitis and atrophy of the bone or even complete detachment of the hoof capsule (Morrison, 2010a; Pollitt, 2008). The condition in which the third phalanx descends is commonly referred to as 'founder'. Although this is usually a chronic process, the third phalanx might sink within a few days in very severe cases. Therefore, some studies terms this particular type of laminitis 'acute founder' (Eustace and Emery, 2009) or 'fatal sinker syndrome' (Floyd and Mansmann, 2007).

4. CLINICAL SIGNS

4.1 ACUTE PHASE

Horses and ponies are usually suspected to be suffering from laminitis when the disease has already progressed to the acute phase and the first clinical signs can be observed. Because the clinical symptoms are not always pathognomic, careful inspection and monitoring of the animal, plus additional diagnostic methods such as radiology, and the detection of an underlying disease might be helpful in setting up a reliable diagnosis.

In moderate to severe cases the horse or pony will have an increased heart rate, increased respiratory rate, spontaneous sweating and mild to severe hyperthermia. Most laminitic horses are restless and shift their weight from one side to the other or alternately lift one foot and then another to reduce the pain, which is caused by the weight load on the laminae.

A withdrawal reaction can be provoked by means of a hoof tester or by manual application of rotational force to the hoof (van Eps, 2010a).

Persistent digital hyperthermia, caused by vasodilation, can be detected in most horses suffering from laminitis during the acute phase and sometimes even during the developmental phase of the disease (de Laat et al., 2012a). However, hoof temperature is strongly related to the ambient temperature. Palpation of the digital arteries above the fetlock might reveal an bounding, intensive pulse. The horse should preferably be examined after a period of rest because exercise or even a few steps can exaggerate the digital pulse of healthy horses (Redden, 2005; Pollitt, 2008). Furthermore, other pathological conditions, e.g. navicular disease or abscessation, can also lead to a bounding digital pulse.

The characteristic stance of a laminitic horse is a good diagnostic aid. If only the forefeet are affected, as it is usually the case because they bear about 65% of the horse's weight, the horse places the forefeet out in front of the body to shift the load from the painful toes to the heels. The hind feet are positioned under the abdomen to set a greater weight load on the hindquarters (**Figure 2**). Sometimes the forelimbs are placed back underneath the abdomen and flexed, which decreases the tension of the deep digital flexor tendon on the third phalanx.

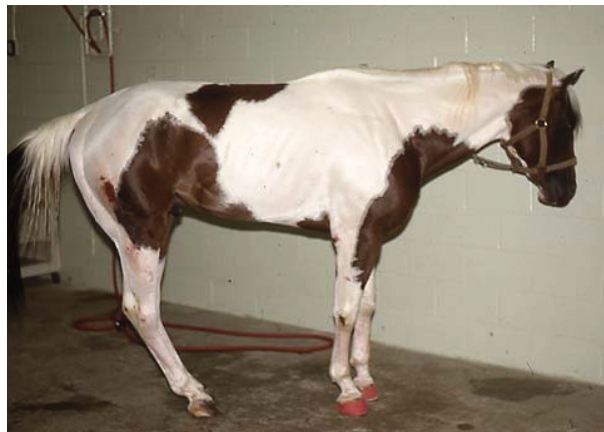

Figure 2: *Typical stance of a horse with laminitic front limbs.* Source: White, 2005

The horse tries to unload the painful front hooves by shifting the majority of the bodyweight to the hind limbs. This is achieved by placing the hind limbs under the abdomen.

When laminitis occurs in the hind feet, the assembly of all four feet will be reversed (Pollitt, 2008; White, 2005). In cases where a horse or pony has overly painful front or hind limbs or, in cases where all four hoofs are affected, the animal will be recumbent (Redden, 2005). If the front or hind limbs are more severely affected, not only depends on the distribution of the

horse's bodyweight, but also on its hoof conformation and angle. However, equine laminitis limited to the hind hooves seems to occur significantly less frequently.

Lameness might be the most obvious sign and is often the first symptom observed by the horse owner. Most horses are reluctant to move and appear to be 'treading on eggshells'. Because the deep digital flexor tendon puts traction on the distal phalanx, thereby increasing the shearing forces acting on the laminae, the posterior phase of the forelimb stride is kept as short as possible. While walking, the horse will usually place the hooves with the heels first, and keep the swinging phase of the stride of the affected limbs short, as during this period the contralateral limb suffers a double burden. That is also the reason why laminitic horses are reluctant to lift one front limb or hind limb respectively (Pollitt, 2008; White, 2005). During inspection of the animal's gait, special attention should be paid to the manner in which the horse places its feet, as it is an indicator of distribution of lamellar injury (O'Grady, 2010). With mild forelimb laminitis, the horse's gait may appear normal, but it should always also be inspected during turning movements, which exacerbate lameness on the inward limb (van Eps, 2010a).

OBEL GRADES OF LAMENESS

In 1948, the Swedish veterinarian Nils Obel developed a grading system for lameness in equine laminitis based on the severity of clinical symptoms. This system identifies four grades of lameness, named after their author. Obel grade I laminitis describes the least severe type of lameness, when the affected animal shifts its weight from one leg to the other but shows no lameness at walking pace. Horses or ponies with Obel grade II laminitis are reluctant to turn on hard surfaces and are obviously lame at the trot. Their gait appears stiff. However, a horse with Obel grade II lameness doesn't resist or show great discomfort in the contralateral limb when one foot is lifted. With Obel grade III laminitis the animal shows lameness even at walking pace and will often move unwillingly. Furthermore, the animal will resist lifting one leg due to the increased pain in the contralateral limb, which would have to bear double the weight. Obel grade IV laminitis is the severest degree of laminitis. The horse will be reluctant to move and is often recumbent (Pollitt, 2008; White, 2005).

4.2 CHRONIC PHASE

The chronic phase of equine laminitis is characterized by a mechanical collapse of the suspensory apparatus of the distal phalanx, meaning that the majority of the lamellae have lost their attachment and there is little or no connection between the hoof capsule and the third phalanx. The consequence is that the pedal bone rotates and/or descends in severe cases.

As the coronary corium, a constituent of the coronary band, is firmly attached to the hoof cartilage, the coronary band connective tissue follows the descending movement of the third phalanx (Pollitt, 2008). This creates a noticeable depression above the proximal extent of the coronary band and the sharp margin of the proximal hoof capsule becomes palpable. The width and depth of this supracorony depression reflects the degree to which the distal phalanx has foundered (Eustace and Emery, 2009). Contrary to the described depression, in some cases with extensive inflammation, the coronary band becomes edematous and bulges over the proximal edge of the hoof wall (Rucker, 2010).

The growth of the dorsal hoof wall is impaired which leads to a relative overgrowth of the heels. Fluctuations in the growth rate of the dorsal hoof wall create a characteristic appearance of growth rings. These growth rings, running roughly parallel to the coronet, diverge at the heels and converge at the toe region (**Figure 3**). Continuous retarded growth leads to a ‘dished’ appearance of the dorsal hoof wall and, if not corrected, the hoof wall will curve and grow upwards, into what can be described as ‘Aladdin’s slippers’ (Eustace and Emery, 2009; Pollitt, 2008).



Figure 3: *Growth rings in case of chronic laminitis.* Source: own figure

This picture shows the hoof of a pony with chronic pasture-induced laminitis. The prominent growth lines diverge from the dorsal surface of the hoof capsule towards the heels.

Due to the pressure exerted by the displaced phalanx, the sole loses its concavity, becomes flat and later forms a convex bulge over the tip of the coffin bone. In deteriorating cases the third phalanx can cause the sole to crack and the corium and tip of the phalanx to prolapse through the sole. The white line, transition of the dorsal hoof wall into the sole horn, becomes wider, reflecting the increasing space between the dorsal surface of the distal phalanx and the inner surface of the hoof capsule (O'Grady, 2010; Pollitt, 2008; White, 2005).

5. PATHOLOGICAL CHANGES OF THE HOOF

5.1 HISTOLOGICAL CHANGES

During the developmental and acute phase of equine laminitis pathological changes are confined to the suspensory apparatus of the distal phalanx. The original pathomechanism of laminitis takes place under the hoof capsule and can only be visualized by microscopic investigation of tissue explants.

The secondary epidermal lamellae of a healthy hoof interlock perfectly with the secondary lamellae of the digital corium, which are formed by a thin strand of connective tissue. The junction between the epidermal and dermal lamellae consists of the basement membrane, a thin layer of fibrillar collagen, and the glycoprotein laminin. A single row of basal cells lines the secondary epidermal lamellae to which the basement membrane is tightly adherent. The physiological characteristics of the secondary epidermal lamellae are their rounded tips, the oval basal cell nuclei positioned away from the basement membrane, and the basement membrane lying tightly upon the lamellae, penetrating deeply into their crypts (**Figure 4, p. 15 below**). The dermal connective tissue strands fill the spaces between the secondary lamellae without a gap (Pollitt, 2008).

At the Australian Equine Laminitis Research Unit (AELRU), a laminitis assessment system was established by means of lamellar tissue staining and immunohistochemical methods (Pollitt, 2008). Hematoxylin & eosin (HE) or periodic acid-Schiff (PAS) staining can be used to demonstrate the epidermal lamellae and the basement membrane in histological sections, whereas hemidesmosomes are best observed by electron microscopic investigation. Additionally, immunohistochemical methods using basement membrane specific antibodies, were conducted at the AELRU to emphasize the basement membrane.

Initially, the basal cells of the secondary epidermal lamellae lose their intercellular attachment and appear to slide over each other. Their cell nuclei become rounded and shift towards the

basement membrane. The secondary lamellae have a stretched appearance and a tapered tip (**Figure 5, p. 16 below**). At those tapered tips, the basement membrane starts to separate from the underlying basal cells, enabled by the degradation of laminin. These changes can be detected towards the end of the developmental phase of equine laminitis prior to the onset of clinical symptoms and characterize grade 1 histological laminitis. Grade 2 histological laminitis is defined by a retraction of the basement membrane. The dermal and epidermal lamellae move apart from each other, resulting in the formation of amorphous clumps of epidermal cells. A rapid and complete basement membrane separation from all epidermal lamellae surrounding the distal phalanx leads to its entire detachment from the hoof capsule and the phalangeal bone sinks distally. This worst-case scenario is referred to as grade 3 histological laminitis (Pollitt, 2008).

Electron microscopic examination of lamellar sections taken from laminitic horses showed a decreased number of hemidesmosomes compared with samples from healthy horses. Pollitt (2008) suspected a correlation between their density and the severity of the manifestation of the disease. Other histological alterations occurring during the early stages of equine laminitis are: edema formation in the extravascular space, which is probably compressing the capillaries and small arteries between and nearby to the secondary epidermal lamellae; microvascular thrombosis; leukocyte infiltration; and mitosis and apoptosis of the epidermal basal cells (de Laat et al., 2011a; Weiss et al., 1994; White, 2005).

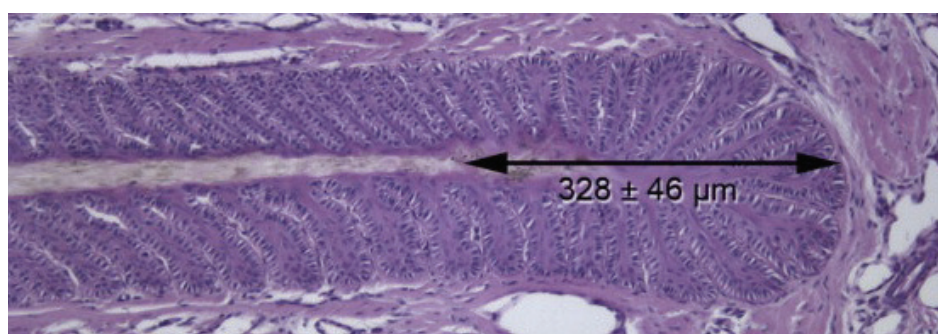


Figure 4: *Lamellar histology of a healthy hoof.* Source: de Laat et al., 2011a

The picture shows a primary epidermal lamella (PEL) with its numerous secondary lamellae, surrounded by the connective tissue and blood vessels of the dermis. The tips of the secondary lamellae are rounded. The distance between the keratinized axis of the PEL and its axial tip has been measured (de Laat et al., 2011a).

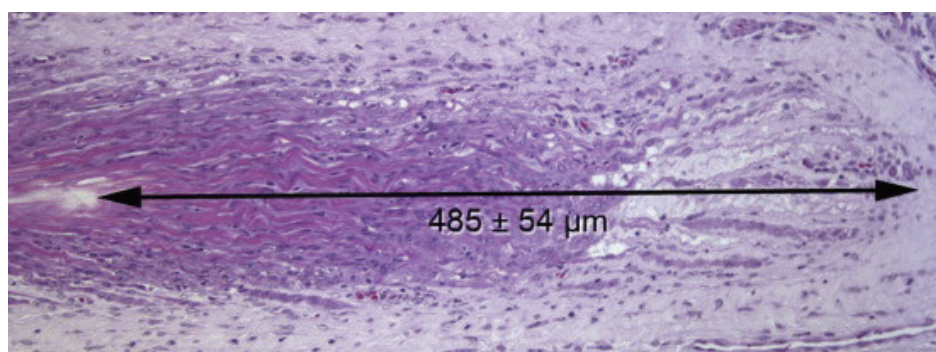


Figure 5: *Lamellar histology in case of oligofructose-induced laminitis.*

Source: de Laat et al., 2011a

The picture shows a primary epidermal lamella (PEL) with its numerous secondary lamellae, surrounded by the connective tissue and blood vessels of the dermis. The secondary epidermal lamellae are stretched and have a tapered tip. The distance between the keratinized axis of the primary epidermal lamella and its axial tip is increased (de Laat et al., 2011a).

5.2 CHRONIC LAMINITIS

After the collapse of the lamellar attachment apparatus, when the forces on the lamellae exceed their strength, the distal phalanx starts to displace within the hoof capsule. These forces are the animal's bodyweight, the tension of the deep digital flexor tendon and the stress at the moment of breakover. Depending on the distribution of the lamellar damage, the bone either rotates or sinks. The latter is the most severe form, referred to as 'sinker' or 'founder', and occurs after complete epidermal detachment. Two main types of rotation can be identified: dorsopalmar/dorsoplantar rotation, where the tip of the distal phalanx moves away from the dorsal hoof wall, and unilateral rotation, where the phalanx rotates either to the medial or lateral side of the hoof. Combinations of these forms can also be found (O'Grady, 2010). Rotation to the medial or lateral side is usually referred to as mediolateral rotation, even though the author finds this not to be the most suitable description, as the term 'mediolateral' describes a rotation from the medial to the lateral aspect of the hoof only. Nevertheless, for the sake of simplicity it will be referred to as mediolateral rotation hereafter.

ROTATION OF THE DISTAL PHALANX

Horses usually load most of their weight on the dorsal hoof wall, the peripheral sole at the toe and to a lesser degree on the heels. In standing position and while walking, the sole and frog are not weightbearing (Hampson and Pollitt, 2011). After a laminitic insult to the hooves the increased mechanical load on the dorsal lamellae by the animal's bodyweight plus the traction of the deep digital flexor tendon often cause disruption of the dorsal attachment of the hoof wall. The dorsal laminae are the only supportive structures of the toe region whereas the heels are additionally supported by the frog and bars. This makes a lamellar separation less likely in these zones (Morrison, 2010a). Two types of rotation along the longitudinal axis of the hoof can be identified: dorsal capsular rotation and phalangeal rotation. Deviation of the dorsal surface of the distal phalanx with respect to the hoof capsule, with the pedal bone staying correctly aligned to the middle and proximal phalanx, is referred to as dorsal capsular rotation (**Figure 6**). In the case of phalangeal rotation, the distal phalanx rotates away from the dorsal hoof capsule, disrupting the axis of the phalangeal bones and resulting in an abnormal flexure of the distal interphalangeal joint (O'Grady, 2010) (**Figure 7, p. 18 below**). Combinations of these two forms are possible.

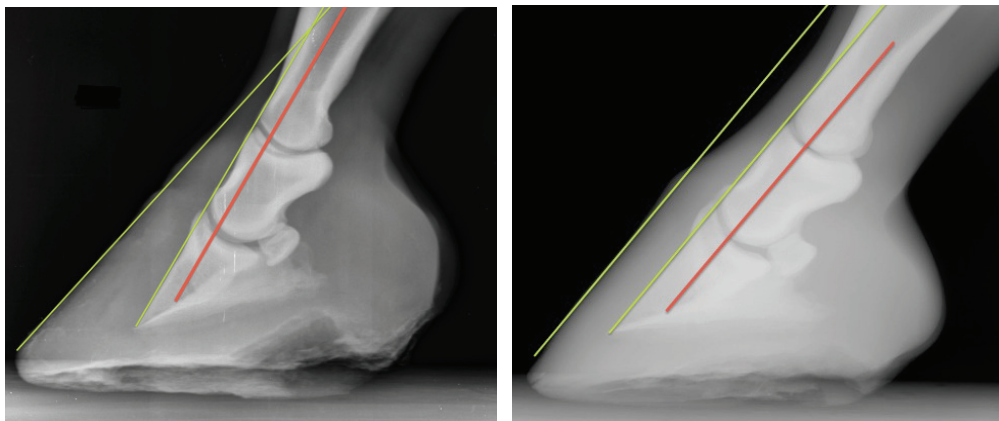


Figure 6: *Dorsal capsular rotation (left) & reference X-ray (right).* Source: own figure

The red line indicates the straight axis of the phalanges, while the green lines in the left picture show that the dorsal surface of the pedal bone is parallel to the phalangeal axis, while it diverges from the dorsal hoof wall.

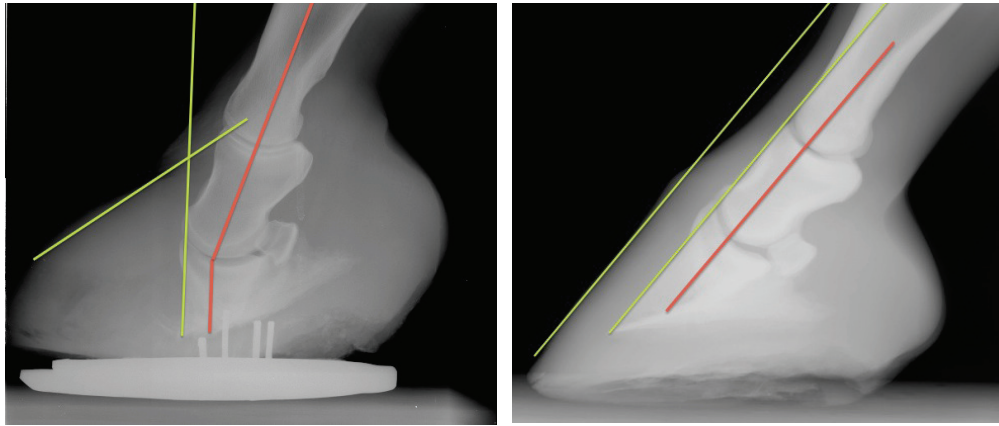


Figure 7: *Phalangeal rotation (left) & reference X-ray (right).* Source: own figure

The red line in the left picture demonstrates that the distal phalanx has rotated with respect to the axis of the proximal phalanges, resulting in flexure of the coffin joint. The green lines indicate the dorsal surface of the hoof capsule and the distal phalanx.

During each stride, the deep digital flexor tendon, that has its insertion site at the palmar/plantar plane of the distal phalanx, exerts traction on the pedal bone. Especially at the moment of breakover, the load is concentrated at the dorsal aspect of the hoof (Morrison, 2010a). Without an intact suspensory apparatus, the pedal bone gets pulled away from the dorsal hoof wall, resulting in phalangeal rotation. Another theory about the reason for distal phalanx rotation was established by Pollitt (2008), who states that inward-growing hoof tubules of the terminal wall and sole might push the tip of the third phalanx down and backwards. The descending distal tip of the third phalanx drags down the tubular growth zone that is located beneath it which leads to distorted inward growth of the new hoof horn. The alteration of the hoof growth in chronic laminitis cases will be discussed in more depth on the following pages. In addition, the tip of the third phalanx compresses the capillaries of the terminal papillae and the circumflex vessels. The pressure load and the disabled blood supply can lead to necrosis of the sole and in more severe cases to osteolysis, distal margin fractures and osteitis. Rotation of the pedal bone is a chronic process and it usually takes some weeks for the distal phalanx to rotate to a degree that can be detected on a radiographic examination (Pollitt, 2008).

DISTAL DISPLACEMENT

Vertical displacement of the distal phalanx occurs in cases of circumferential lamellar loss. This condition is commonly called ‘sinker’ or ‘founder’. In contrast to rotation of the distal phalanx, this downward displacement might take place within a few days after the developmental phase and this condition is also referred to as ‘acute founder’ (Eustace and Emery, 2009) or ‘fatal sinker syndrome’ (Floyd, 2007a). These cases are very severe and their prognosis unfavourable. Common consequences of circumferential breakdown of the dermo-epidermal junction are lamellar necrosis and sloughing of the entire hoof capsule. The sole appears collapsed and friable and a deep depression in the coronary band will be noticed all around the hoof. In advanced cases, as the circulation is lost, the coronary band will be swollen instead. As the capsule starts to detach, serum, blood or pus might extrude at the coronary border (Floyd, 2007a).

Fatal sinker syndrome is frequently seen in mares with septic metritis. Horses with distal phalangeal displacement are usually in a very bad general condition with tachycardia, increased blood pressure, injected mucus membranes, edematous distal legs and a bounding digital pulse (Floyd, 2007b). Venous-filling deficits can be detected in the circumflex vessels and circumferential in the sublamellar vascular beds (Rucker, 2010). Horses usually desire recumbency as they are in very severe pain. However, a reduction of pain can often be detected as the ischemic necrosis of the hoof tissues progresses and the animal’s condition seems to improve until the hoof capsule is sloughed off (Rucker, 2010).

Immediate hoof wall ablation and transfixation pin casting might be the only way to save an acutely foundered horse (Floyd, 2007b).

MEDIOLATERAL ROTATION

Mediolateral displacement of the distal phalanx is less frequently recorded than the above-mentioned types of chronic laminitis. However, this might be due to the fact that this condition cannot be detected on mediolateral X-rays, and is often missed by the practitioner if dorsal capsular or phalangeal rotation has been readily diagnosed and no further investigations into mediolateral rotation are taken into consideration.

Unilateral displacement is probably caused by unevenly distributed weightload and mechanical stresses during locomotion. Most horses load the medial side of their front feet more than the lateral and therefore rotation to the medial aspect of the hoof occurs more often (Rucker, 2010; O’Grady, 2010). Distribution of the weightload is determined by the conformation of the hoof. The lateral wall of a proper hoof creates an angle of approximately

75° to the ground surface whereas the angle between the ground and the medial wall is about 82° (Wissdorf et al., 2002). This shows that the centre of pressure is generally located slightly medial to the longitudinal axis of the equine hoof (Morrison, 2010a). Often the hoof conformation diverges from the norm and horses with hooves that are offset to the lateral side will experience an even greater pressure on the medial aspect of the hoof and are therefore prone to develop medial rotation of the distal phalanx under laminitic conditions (O'Grady, 2010). In a study investigating the hoof wall growth in cases of chronic laminitis, a correlation between the length of the hoof horn and a predilection for rotation to either the lateral or medial side could not be demonstrated (Hertsch and Teschner, 2011).

After diagnosing chronic laminitis, the farrier or veterinary surgeon often provides the affected hooves with heel elevation devices to decrease the traction force of the deep digital flexor tendon, which usually decreases pain and discomfort. However, the risk of subsequent mediolateral rotation seems to be increased after heel elevation if the horse has a laterally offset hoof conformation, as heel elevation shifts the ground reaction force from the dorsal hoof wall to the heels and quarters (Morrison, 2010a; O'Grady, 2010).

The best way to diagnose mediolateral rotation is by radiologic examination from a dorsopalmar/plantar view. In some cases the sinking phalanx will create a palpable depression above the coronary band on the side of the foot towards which the distal phalanx is rotating.

HOOF-HORN GROWTH AND THE LAMELLAR WEDGE

The hoof horn of the equine digits becomes worn with use and is continually replaced throughout the animal's life. The horn of the hoof walls, which is produced at growth zone of the coronary band, grows in a proximo-distal direction (Pollitt, 2008). The dorsal, lateral, medial and heel parts of the hoof capsule grow at different speeds, according to their abrasion. Differences between breeds and individuals should also be considered. The dorsal wall grows around 0.4-0.8 cm per month and will be completely replaced within 12 months, whereas replacement of the heels can be completed in as little as 4 months because of their inferior length. The sole and frog horn usually grow more slowly than the rest of the hoof but can be renewed within 2 to 3 months (Wissdorf et al., 2002).

One of the clinical signs of chronic laminitis is an obvious deformity of the hoof wall. Growth rings or laminitic rings can be detected running parallel to the coronet. The distance between the lines increases from the toe to the heels. Growth rings can also occur after infectious diseases, feed adjustment or increased mechanical stress. These rings, in contrast to the laminitic growth rings, are not only parallel to the coronet but also to each other (Wissdorf et

al., 2002). The dorsal hoof wall growth seems to be delayed, resulting in a relative heel overgrowth. In fact it is not the amount of horn produced that is altered but its direction. Only the visible length of the hoof wall is reduced. A study of hoof-horn growth revealed that the horn tubules lie in folds. Also worthy of note is the observation that the horn tubules of the medial or lateral hoof wall do not fold in cases of mediolateral rotation (Hertsch and Teschner, 2011).

When the distal phalanx descends, it distorts the growth zone of the coronary band. Its soft tissue is dragged beneath the margin of the hoof capsule and the coronary papillae become kinked and continue to produce new hoof horn in a different direction (**Figure 8**). The coronary cushion, between the coronary margin of the hoof wall and the extensor processes of the third phalanx, becomes narrower and the coronary band is compressed internally. If the distal phalanx continues to displace distally, the coronary band will not be able to withstand this tension and will break away from the hoof capsule. This damage is called ‘coronary band shear lesion’. The site of compression depends on the type of pedal-bone displacement and in the case of unilateral displacement, the coronary band will most frequently suffer impingement on the medial side (Morrison, 2010a; Pollitt, 2008; Rucker, 2010).

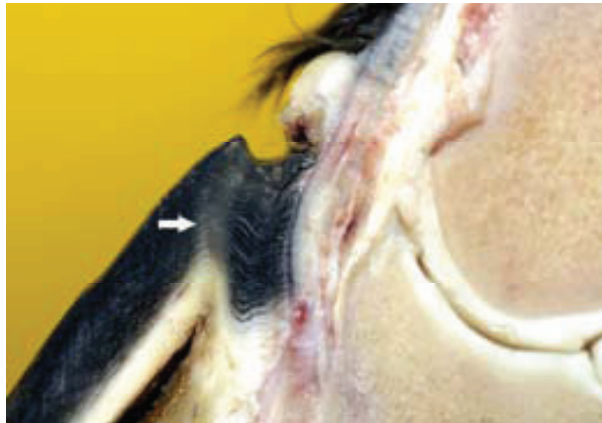

Figure 8: *Kinked hoof wall tubules at the coronary band.* Source: Pollitt, 2008

When the distal phalanx dislocates, it takes the coronary papillae with it, thereby interrupting normal hoof wall growth. Instead of running in a parallel and downward direction, the proximal hoof wall tubules are kinked (arrow) and grow towards the extensor process of the P3.

Similar changes occur in the apical region of the hoof. The descending tip of the distal phalanx compresses the solar corium and displaces it. As this is also a site of tubular-horn production, the distal wall and sole tubules start to grow inwards, towards the bone, instead of in their normal straight and parallel downward orientation (Collins et al., 2010; Pollitt, 2008).

The resulting pressure on the tip of the pedal bone can cause osteolysis or fractures. Furthermore, Pollitt (2008) suspected that the inward-growing horn tubules may contribute to a further rotation of the third phalanx.

When the distal phalanx rotates, the space between its dorsal surface and the dorsal hoof wall widens. As this area appears wedge-shaped in the hoof's cross-section, it is referred to as the *lamellar wedge* (Collins et al., 2010).

In cases of a mild rotation, this space is occupied only by stretched and weakened laminar tissue. But if the basement membrane is destroyed, normal restoration of the lamellar architecture is unlikely and epidermal cells hyperproliferate to close the gap between corium and dermis. If the rotation is severe, the lamellar wedge initially consists of necrotic or inflamed tissue and haemorrhage. Laceration of the vasculature leads to formation of serous fluid-filled pockets, the so-called seromas. Afterwards, when the distal phalanx is stabilized, the damaged tissue undergoes some kind of regeneration or healing process and is replaced by hyperplastic and hyperkeratinized epidermis (Collins et al., 2010; O'Grady, 2010).

The lamellar wedge maintains the physical and mechanical integrity of the hoof by supporting the bone. However, it is not nearly as robust as the healthy suspensory apparatus of the distal phalanx, and will break down under enhanced pressure. The exaggerated proliferation of tubular horn and lamellar tissue results in a thickened, dysplastic hoof horn. This abnormal horn, which is slightly yellow on digital cross-section, is sometimes called 'scar horn' or 'ectopic white line' and fills the space between the epidermal and dermal components of the hoof (Collins et al., 2010). The actual white line, the junction between the wall and the sole horn, widens over time, as the lamellar wedge increases in size. This becomes apparent after approximately 36 days on the trimmed solear hoof surface and often serves as an indicator for chronic laminitis (Collins et al., 2010).

COMPLICATIONS

Distal phalanx instability, tissue compression and decreased perfusion of the laminitic hoof are often associated with seroma and abscess formation, necrosis, bruising, bone atrophy or osteitis and bone fragmentation.

In uncompensated forms of chronic laminitis, where the distal phalanx cannot be stabilized and continues to descend, it compresses the solar corium leading to necrosis of the sole. Due to the increased pressure, the sole bulges out over the tip of the coffin bone and becomes crumbly with a tendency to crack. Consequently, the solar corium and the tip of the distal phalanx prolapse through the sole (**Figure 9, p. 23 below**).

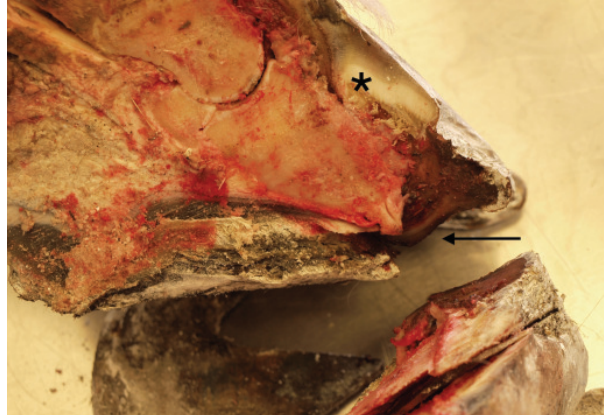


Figure 9: *Prolapse of the distal phalanx.* Source: own figure

This picture shows a severe case of uncompensated chronic laminitis. The longitudinal section of the hoof shows the compressed and necrotized solar corium with prolapse of the distal phalanx (arrow) and the distorted horn tubules (asterisk).

As the integrity of the sole horn is impaired, bacteria and other microorganisms can easily enter the hoof and cause sepsis of the distal phalanx and soft tissue. This is often detected several weeks after the onset of laminitis (Rucker, 2010).

A recent study revealed that the laminar tissue in horses suffering from chronic laminitis is colonized by environmental, potentially pathogenic bacteria at a 100-fold higher level than that of healthy horses (Onishi et al., 2012). The bacteria isolated from the lamellar tissue in both Gram-positive and Gram-negative species, are capable of forming microbial biofilm communities. Biofilm infections are characterized by microorganisms that anchor to a surface and bind to each other by an extracellular matrix with protective properties. Therefore they develop an increased antibiotic resistance (Proal, 2008). The weak point of the equine hoof capsule is the white line, which is a possible site of entrance for microorganisms from the environment. It was suspected that in healthy horses the host's defence mechanism fights the intruding microbes and keeps their count low, whereas this mechanism fails in laminitic horses. The high load of biofilm-forming bacteria, discovered in this study, could be the reason why horses with chronic laminitis commonly suffer from repeated foot abscessation and appear to have a poorer response to antibiotic treatment (Onishi et al., 2012).

Not only will the solar corium necrotize under the pressure of the distal phalanx, but also the tip of the phalanx might undergo pressure atrophy and osteolysis (**Figure 10, p. 24 below**).

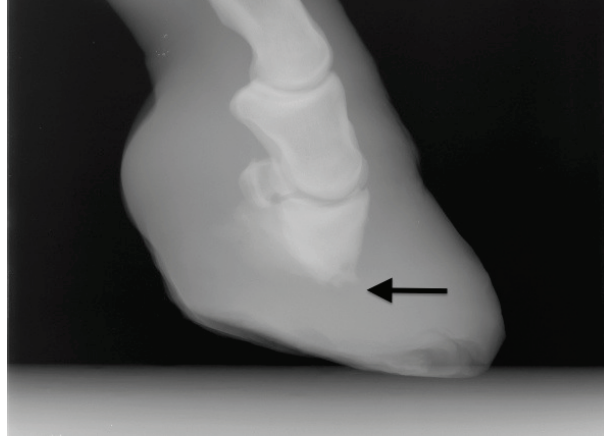


Figure 10: *Osteolysis of the tip of the P3.* Source: own figure

Severe chronic laminitis with rotation and osteolysis of the P3. The tip of the bone (arrow) is less radiopaque and has lost its distinct borders.

Secondary bacterial infections of the bone can lead to osteitis, which is extremely painful and causes pronounced lameness. The state of the distal phalanx can best be evaluated by means of dorsopalmar/dorsoplantar or dorsopalmar/dorsoplantar oblique X-rays (Eustace, 1992; Rucker, 2010). This will be elaborated later in the context of diagnostic measures.

Pockets filled with serous fluids, the seromas, are generated following severe damage to the vasculature beneath the hoof capsule. Triggered by septic inflammation of the soft tissue or the distal phalanx, these pockets can turn into abscesses, which can disrupt either through the sole or migrate up to the coronary band. Serum, pus or gas might discharge above the coronary margin of the hoof capsule (Eustace, 1992; Pollitt, 2008).

In cases where the distal phalanx has prolapsed through the sole, distal flexor tenotomy is the fastest and probably the only way to restore digital perfusion, which is essential for recovery, and to reduce the pain. Furthermore, complete or partial hoof capsule ablation is a drastic but favourable procedure. In this way abscesses can be drained, necrotic bone and soft tissue can be surgically debrided and the hoof-horn tubules will grow back in their normal arrangement. The horse should also receive systemic antimicrobial therapy and regional limb perfusion is advised to support the healing processes (Morrison, 2010a; Rucker, 2010).

6. CAUSES AND RISK FACTORS

6.1 INFLAMMATORY AND ACUTE GASTROINTESTINAL DISEASES

CARBOHYDRATE OVERLOAD

Alimentary carbohydrate overload is caused by an increased intake of non-structural carbohydrates, namely starch and water-soluble carbohydrates such as fructans and sugars.

There are two types of carbohydrate overfeeding in horses and ponies. One is defined by an increased intake of starch or grains, also referred to as ‘grain founder’. The other one is referred to as ‘grass founder’ and is caused by grazing on lush pastures with a high content of fructans (Pollitt, 2008). However, the term ‘founder’ might not always be appropriate as it literally refers to the vertical downward displacement of the distal phalanx in cases of chronic laminitis.

Grain founder is usually the consequence of overfeeding the horse a diet with high grain content. Especially dangerous are wheat, sorghum, corn and barley grains (Pollitt, 2008). Some horses or ponies might manage to reach the feed storage room and gorge themselves on grains. In cases of acute carbohydrate overload the animal will show signs of colic and might develop symptoms of acute laminitis as early as 40-48 hours after the grain intake (Watts and Pollitt, 2010). If grain overfeeding is suspected, the stomach of the horse should be emptied and paraffin oil administered via a nasogastric tube to decrease the intestinal transit time (Rendle, 2006).

Grass founder may result if horses or ponies are allowed to graze on lush pastures that contain high amounts of fructans or starch. In contrast to grain overload it is seldom an acute condition. Plants produce sugars via the process of photosynthesis. This occurs during the daytime, as photosynthesis requires sunlight. During the night plants use up these sugars to create energy and compounds needed for their growth. This process is called respiration. If the rate of photosynthesis exceeds the growth rate, sugars are stored as fructans or starch, depending on the plant species. The optimum temperature for most plants to produce sugars is above 10-15°C whereas respiration requires a temperature higher than 5-10°C. If the temperature drops below 5°C during the night, plant growth will be interrupted and more storage carbohydrates will accumulate (Watts and Pollitt, 2010). Taking these facts into consideration, it seems obvious that pastures are especially high in carbohydrates during spring time, when temperatures are still low during the nights; sunlight and rain are supplied to the plants in sufficient amounts; and grasses tend to grow intensively. Most at risk are

ponies and obese animals when grazing on lush pastures, since they are prone to insulin resistance and a high carbohydrate intake can easily trigger laminitis. However, insulin resistance will be discussed in a separate section. Horses at risk should have restricted access to pastures and should be provided with hay. After the grass is cut, the plants continue to utilize the carbohydrate storages until their water content is depleted, causing the starch or fructan level to be decreased. Thus hay has a lower carbohydrates content than fresh grass. Soaking the hay in water prior to feeding can also reduce its sugar content (Huntington et al., 2009).

If the intake of carbohydrates exceeds the small intestinal digestive capacity, the carbohydrate-rich feed will reach the large intestine and undergo microbial fermentation. The limit of the small intestinal capacity to digest starch is 0.4% of bodyweight per meal and a dosage of less than 0.2% of bodyweight is recommended. Excessive carbohydrate fermentation will take place in the caecum and probably to a greater extent in the colon, as fine particles like grains transit the caecum quite fast (Respondek et al., 2008). Starch and fructans are fermented to form lactic acid in the large intestine. An increased proliferation of lactic acid-producing bacteria, particularly *Streptococcus bovis*, *Streptococcus equinus* and *Lactobacilli*, has been reported in the large intestine of horses after experimentally induced carbohydrate overload (Milinovich et al., 2010). Due to the excessive amount of lactate, the pH of the intestinal fluid in the large intestine decreases, triggering the death of other bacteria species. Consequently dead bacteria release detrimental substances like endotoxins, exotoxins, amines and bacterial DNA. Especially when high numbers of *Enterobacteriaceae*, normal inhabitants of the equine digestive tract, are lysed, endotoxins are released. Endotoxins and lactate can cause increased vasodilation in the intestinal mucosa. As early as 24 hours after carbohydrate overload, degeneration of the epithelial tight junctions has been detected in the caecum (Pollitt, 2008; Suagee et al., 2012). Since the structural integrity of the large intestine is weakened, toxic bacterial substances and lactate can reach the bloodstream. The result is a systemic inflammatory response in which platelets and leukocytes are activated (White, 2005). Inflammatory mediators and microthrombi formation are thought to be involved in the pathophysiology of equine laminitis (Weiss et al., 1994). Weiss et al. (1997) proved the hyperaggregability of platelets and increased numbers of platelet-neutrophil aggregates in the lamellar tissue of ponies during the developmental phase of alimentary-induced laminitis. Additionally, Bailey et al. (2004a) detected that vasoactive amines, produced by hindgut bacteria, can cause vasoconstriction in the equine limbs if they enter the bloodstream. Furthermore, endothelin, a potent endogenous vasoconstrictor, has been

identified in increased amounts in lamellar connective tissue after acute carbohydrate overload (Katwa et al., 1999). By causing decreased perfusion of the digital laminae, these substances could contribute to the development of equine laminitis.

Experimentally, laminitis can be induced by the administration of high amounts of oligofructose or starch directly into the stomach via a nasogastric tube (Respondek et al., 2008). These experimental models of equine laminitis have been and still are used for further research.

Visser and Pollitt (2011a) conducted a study that detected leukocyte (monocyte and neutrophils) infiltration and an increase in interleukin-6 (IL-6) gene expression in lamellar-tissue explants from horses with experimentally induced laminitis (oligofructose model). They also found that IL-6 triggered pro-matrix metalloproteinase-9 secretion, the inactive precursor of matrix metalloproteinase-9, which in turn might be involved in lamellar basement membrane damage. Additionally, Bailey et al. (2009) measured increased endotoxin levels in the plasma of horses after experimentally induced oligofructose overload and suggested that endotoxins activate platelets, thereby indirectly activating white blood cells, which causes inflammatory changes of the suspensory apparatus of the third phalanx. Another possible mechanism by which carbohydrate overload and/or the resulting endotoxaemia might act on the digital lamellae was suggested by a study that examined the effect of intravenous endotoxin (lipopolysaccharide) or per oral oligofructose administration on the insulin sensitivity of horses (Tóth et al., 2009). It was demonstrated that both endotoxaemia and carbohydrate overload reduced insulin sensitivity in the animals being experimented on. In response to decreased insulin sensitivity, the pancreas liberates higher amounts of insulin to keep the blood-glucose level in its physiological range. Hyperinsulinaemia in turn has been proven to cause laminitis in clinically healthy ponies and horses (Asplin et al., 2007a; de Laat et al., 2010).

ENDOTOXEMIA AND SEPSIS

Sepsis is caused if bacteria or their toxins enter the systemic circulation and is manifested as a systemic inflammatory response syndrome (SIRS). Clinical signs include fever, elevated heart and respiratory rates, purple discolouration of the mucous membranes, a purple line on the gingiva above the teeth (the so-called 'toxic line'), increased capillary refill time, petechial haemorrhages on the mucosal membranes, cardiovascular dysfunction, and shock. If only bacterial endotoxins enter the bloodstream, it is referred to as endotoxemia; however, the clinical appearance can be the same. Endotoxins are lipopolysaccharide components of the

bacterial cell wall of some Gram-negative bacteria. In contrast to exotoxins, bacterial endotoxins are only released if the bacteria die or when they undergo rapid proliferation, by which they produce an excess of bacterial cell-wall sections (Radostits et al., 2007).

Enterobacteriaceae, like *Escherichia coli* and *Salmonella* species, are part of the normal microflora of the equine digestive tract (Sakazaki and Miura, 1956). In healthy horses those bacteria, their endotoxins and other bacterial components or products are only crossing the intestinal mucosal barrier in very small amounts and are eliminated by the liver. If intestinal integrity is impaired, larger amounts of these substances enter the systemic circulation, causing septicaemia and endotoxemia, respectively (Radostits et al., 2007).

Bacteria and their products are most often absorbed from the intestine, but the uterus, peritoneum, or less frequently, the mammary glands are also possible sites where they can enter the bloodstream. Horses are overly sensitive to intestinal diseases, such as enteritis, large intestinal displacement, strangulation, invagination, obstruction and postoperative paralytic ileus, all of which can impair the protective mucosal barrier (Radostits et al., 2007). Additionally, carbohydrate overload has been shown to reduce intestinal integrity, allowing endotoxins and bacterial amines to enter the bloodstream (Pollitt, 2008; Suagee et al., 2012). The equine digital lamellae seem very susceptible to either the bacterial substances themselves or the cells and inflammatory mediators of the host's immune response. However, in several clinical studies, endotoxins alone failed to produce laminitis (Divers, 2010; Tadros and Frank, 2012). Nevertheless, circulating bacteria, endotoxins and other foreign materials can cause the formation of platelet thrombi by damaging the intima of blood vessels (Radostits et al., 2007). Microthrombosis has been detected in lamellar tissue samples from laminitic horses and the consequent digital hypoperfusion and ischemia are possible causes of equine laminitis (Weiss et al., 1994).

The deleterious effect of endotoxins is mediated mainly by an increased production of cytokines, platelet-activating factor, vasoactive amines, leukotrienes, proteinases, prostaglandins and toxic oxygen metabolites by host cells (Radostits et al., 2007). Vasoactive amines are generated by many bacteria from amino acids and can reach the systemic circulation after a carbohydrate overdose. These amines have been proven to decrease digital arterial blood flow in horses (Bailey et al., 2004a). Furthermore, Tóth et al. (2008; 2009) demonstrated that lipopolysaccharides administered in an intravenous infusion led to a significant decrease in insulin sensitivity. The pancreas showed a compensatory response, which means that it produced higher levels of insulin. The resulting hyperinsulinaemia has

been proven to cause laminitis in ponies and horses (Asplin et al., 2007a; de Laat et al., 2010), which will be more fully explained later on.

INFLAMMATORY DISEASES

Horses suffering from systemic inflammatory diseases are at high risk of equine laminitis. Acute intestinal disorders and metritis are often considered as laminitis trigger events. These diseases are mainly caused by Gram-negative bacteria and therefore endotoxins and other bacterial substances are thought to mediate the insult on the digital lamellae. However, severe Gram-positive infections, often associated with pneumonia, pleuritis or myositis, can also cause systemic inflammation and laminitis (Divers, 2010). An increased proinflammatory cytokine expression in response to pathogen-associated molecular pattern molecules (PAMPs), like cell-wall components, of Gram-negative bacteria has been detected, but not in response to those of Gram-positive bacteria (Leise et al., 2010). This suggests that inflammatory mediators alone can affect the lamellar integrity without the mediation of endotoxins. When PAMPs and damage-associated molecular pattern molecules (DAMPs), components of damaged host cells originating from the site of infection or trauma, get into the bloodstream, the body reacts with a systemic inflammatory response. PAMPs and DAMPs are bound to fixed macrophages, which react by releasing cytokines, e.g., tumor necrosis factor alpha and interleukins. The presence of these cytokines, PAMPs and DAMPs in the systemic circulation leads to endothelial events in the microvasculature of different organs. The endothelial cells express chemokines and adhesion molecules on their surface and thereby connect to leukocytes, which subsequently migrate into the surrounding tissues. The extravasation of leukocytes leads to organ damage by leukocyte-derived reactive oxygen and nitrogen species, proteases and cytokines (Belknap, 2010). Besides infectious diseases, severe trauma and anaphylactic reactions to parasites, drugs or feed components can also lead to a systemic inflammatory response affecting the digital integrity.

The main components of the equine lamellar basement membrane – collagen type IV and laminin – have also been detected in a variety of other organs in horses, such as the skin and stomach. These organs reacted with basement membrane degradation to induced laminitis, which supports the thesis that conversely the lamellar basement membrane reacts to systemic trigger factors originating from other organ tissues (Visser and Pollitt, 2011b). If a horse suffers from severe systemic inflammation, the hooves should be considered a shock organ and should be given special attention by means of regular monitoring and preventive measures like cryotherapy (Divers, 2010; Pollitt, 2008).

BLACK WALNUT SHAVINGS

Horses that are bedded on shavings from the black walnut tree (*Juglans nigra*) develop acute laminitis. Residues from lumber industries processing black walnut heartwood can sometimes accidentally be mixed with other wood species and end up in the horse stable as bedding material. Even if it constitutes only 10% of the total bedding, it may cause clinical symptoms, such as edema of the limbs and digital pain, within 24 to 48 hours. If the horse is exposed to greater amounts of black walnut shavings or over a period of time, the clinical symptoms of laminitis can be severe and the edema can extend along the ventral abdomen. In addition, the horse usually shows signs of colic (Cassens and Hooser, 2005).

Clinical symptoms of laminitis can occur as early as 6 to 8 hours after oral administration of black walnut extract (White, 2005). Thus, black walnut extract (BWE) serves as a good experimental model for research on laminitis. Experimental induction of laminitis is accomplished by soaking the heartwood shavings in water for 12 hours, filtering the water and feeding it via a nasogastric tube (Belknap, 2010).

Black walnut extract leads to a systemic inflammatory response in horses (Divers, 2010), which starts within 1.5 hours after nasogastric administration (Belknap, 2010).

Increased expression of endothelial adhesion molecules and chemokines triggers the migration of circulating leukocytes into lamellar tissue. Lamellar gene expression of chemokines showed a 100-fold increase after 1.5 hours and neutropenia was detected 4 hours after BWE administration (Belknap, 2010). Neutrophil granulocytes are suspected of increasing MMP-9 activity in lamellar tissue, which in turn might be responsible for lamellar basement membrane damage and dermo-epidermal separation (Loftus et al., 2006). An increase in cyclooxygenase 2 enzyme was detected within the first hours after black walnut extract-induced laminitis, which is released at inflammatory sites in the presence of inflammatory mediators like tumor necrosis factor alpha (TNF- α) (Divers, 2010). TNF- α was not detected in the digital laminae but was increased in the lungs and liver by which these organs contribute to the systemic inflammation (Belknap, 2010). Cyclooxygenases produce prostaglandin and thromboxane among others, thus causing vasoconstriction and platelet aggregation (Noschka et al., 2009). Vasoconstriction and platelet thrombi could contribute to lamellar injury by leading to digital hypoperfusion and ischemia. Furthermore, high levels of endothelin, vasoconstricting peptides that are released from the vascular endothelium, have been reported to increase within 5 hours after black walnut extract administration (Bailey et al., 2004b). Endothelin reduces the digital arterial blood flow, leading to hypoperfusion and ischemia of the equine digit. In addition, Hurley et al. (2011) proved that the black walnut

extract generates reactive oxygen species, which can trigger metalloproteinase secretion as well as activation (Clutterbuck et al., 2010).

Orsini et al. (2009) established the theory that the toxic effect of black walnut wood might be the tree's defence mechanism against parasitic insects – a mechanism that uses uncontrolled inflammation as a weapon. Without doubt, the black walnut tree's poisonous substance, called 'juglone', has an adverse effect on a variety of plants growing in the tree's vicinity, and may even cause their dieback (Dana and Lerner, 1994).

The shavings of black walnut trees can be identified by their chocolate brown colour and horses must be immediately removed from a contaminated stable and a veterinarian should be consulted (Cassens and Hooser, 2005).

6.2 METABOLIC AND ENDOCRINE DISTURBANCES

EQUINE METABOLIC SYNDROME

Equine metabolic syndrome (EMS) is characterized by insulin resistance, general obesity or regional adiposity (tail head, prepuce, mammary gland region, cresty neck) and a history of laminitis (Pollitt, 2008; Frank, 2011). Further blood testing might reveal an increased fasting glucose, insulin and leptin concentration. Pony breeds, Morgan horses, Paso Finos, Arabians, Saddlebreds, Quarter horses and Tennessee Walking horses are most commonly affected and horses with EMS are often described as 'easy keepers' (Frank, 2011).

EMS is frequently manifested clinically when the pony or horse is allowed to graze on lush pastures and develops pasture-associated laminitis, or when the animal enters negative energy balance (e.g. due to hospitalization) and consequently develops hypertriglyceridemia. Due to the decreased insulin sensitivity of bodily tissues and a resulting lack of intracellular glucose availability, insulin-resistant horses easily mobilize lipids as a source of energy. Hence these horses and ponies are prone to hyperlipidemia (Frank, 2011).

Treiber et al. (2006) succeeded in providing a dominant inheritance pattern for pasture-associated laminitis in ponies. However, environmental circumstances and management of a genetically-prone pony also influence on the clinical manifestation and outbreak of EMS. Regular exercise and dietary restrictions can prevent or reduce obesity and might therefore prevent laminitis in susceptible animals. Moreover, Treiber established the term pre-laminitic metabolic syndrome (PLMS) for healthy horses that are prone to develop EMS according to their phenotype and genetic background (Treiber et al., 2006).

Walsh and colleagues (2007) provided evidence that plasma insulin concentrations are strongly correlated with the occurrence and grade of laminitis in a study including horses with EMS and equine Cushing's disease. They detected that the onset of laminitis was associated with a plasma insulin level that exceeded 100 $\mu\text{IU}/\text{ml}$ ². Interestingly, weight loss did not significantly decrease insulin levels in this study. In any case, a decreased insulin concentration appeared to engender an amelioration of the clinical signs of laminitis.

The clinical appearance of horses suffering from EMS and those with equine Cushing's disease (pituitary pars intermedia dysfunction – PPID) can be quite similar and it is useful to test not only the insulin but also the plasma ACTH levels in case of doubt. Whereas both diseases cause hyperinsulinemia, only horses with PPID will show increased ACTH levels. Nevertheless, further metabolic tests should be done to diagnose PPID, as ACTH levels might undergo seasonal and individual fluctuations (Walsh et al., 2007).

The exact mechanism by which EMS contributes to the development of chronic laminitis is not yet completely defined. Most probably insulin resistance and the resulting hyperinsulinemia encourage vasoconstriction and alter endothelial function while obesity sets the body in a pro-inflammatory state (Geor and Frank, 2009).

Horses with endocrinopathic laminitis often suffer recurrent bouts of laminitis and commonly develop severe symptoms of chronic laminitis. Those horses undergo only a slow recovery process and might never reach their previous soundness (Walsh et al., 2007).

INSULIN RESISTANCE

Insulin resistance is one of the main characteristics of equine metabolic syndrome and is most probably the factor leading to laminitis. It is defined by a glucose uptake impairment of tissues via insulin-stimulated glucose transporters (Asplin et al., 2007a). As a response to chronic insulin resistance, the pancreas produces and liberates greater amounts of insulin. An increased level of circulating insulin is able to activate glucose transporters and the blood glucose level returns to normal. But if the horse or pony faces a significant glucose challenge, for instance uptake of lush, fast-growing grasses in spring, the insulin resistance cannot readily be compensated. Excess insulin will be produced and the consequent insulin toxicity will provoke laminitis (Sillence et al., 2007).

Asplin and colleagues (2007a) managed to induce laminitis in clinically healthy ponies by experimentally induced hyperinsulinemia. The ponies in this trial received a constant intravenous insulin infusion for a maximum of 72 hours while euglycemia was maintained by

² The reference value for plasma insulin concentration is 8 to 30 $\mu\text{IU}/\text{ml}$.

means of a second infusion with glucose. The rate of glucose administration was adjusted throughout the experiment. During the infusion, the serum insulin concentration was 1036 ± 55 $\mu\text{IU/ml}$ on average. All animals were euthanized as soon as they showed signs of Obel grade 2 laminitis. Digital lamellar tissue samples were taken and histologically examined. Clinical and histological signs of laminitis were detected in all four hooves of all the test animals.

Because horses are suspected to be more insulin-sensitive than ponies, de Laat et al. (2010) conducted a comparative experiment in which they succeeded in inducing laminitis in normal Standardbred horses. As in the previous trial, the horses received an intravenous insulin infusion for a maximum of 72 hours under euglycemic conditions. At the onset of Obel grade 2 laminitis, the test animals were euthanized and lamellar tissues histologically examined. The mean serum insulin concentration averaged 1036 ± 129 $\mu\text{IU/ml}$ and all test animals developed acute laminitis. Additionally, the glucose metabolism rate was calculated and the result was higher than that calculated for ponies, which confirmed that horses have a stronger insulin sensitivity. Insulin baseline values higher than 1000 $\mu\text{IU/ml}$ have also been reported in naturally occurring cases of EMS (Huntington et al., 2009).

There are different theories about how insulin triggers the onset of laminitis: impairment of glucose uptake, vascular effects and pro-inflammatory effects (Huntington et al., 2009).

In another study, Asplin et al. (2007b) measured the effect of insulin on glucose uptake in the equine hoof by means of a lamellar explant model. Additionally, they used the PCR technique to evaluate the expression of glucose transporter mRNA in lamellar tissue. Targets of the PCR examination were an insulin-dependent glucose transporter (GLUT-4) gene and an insulin-independent glucose transporter (GLUT-1) gene. Tissue explants were stimulated with insulin for different lengths of time but the resulting glucose uptake didn't differ from the basal glucose uptake. Mainly the GLUT-1 gene was expressed in the lamellar hoof tissue. These findings lead to the conclusion that the lamellar glucose uptake is independent of insulin. Consequently, glucose uptake impairment of the hooves caused by insulin resistance in the digital tissue is unlikely to be the pathomechanism that leads to laminitis in horses and ponies with EMS.

It seems more likely that insulin affects the digital vasculature. By causing vasoconstriction it might, however, in turn deprive the lamellar tissue of glucose, leading to cell starvation (Bailey, 2010). Equine lamellar tissue has an absolute requirement for glucose and if experimentally incubated in the absence of glucose, the lamellae separate easily (Sillence et al., 2007).

Vascular endothelial cells in human patients with insulin resistance and obesity produce decreased amounts of nitric oxide (NO), which is responsible for vasodilation. Advanced glycation end products (AGEs) further impair endothelial NO production (Huntington et al., 2009). Glycation (coupling of glucose and proteins or lipids) in the endothelial cells leads under inflammatory conditions to an accumulation of AGEs. They alter cell functions by binding to multiple cell-surface binding sites (the best known of these is the signal transducing receptor called RAGE), which results in the production and release of pro-inflammatory cytokines, reactive oxygen species (ROS), thrombosis and over-expression of extracellular proteins, most importantly collagen and laminin. RAGE is present in the equine lamellae on keratinocytes, vascular endothelial cells and monocytes (de Laat et al., 2012b). The increased accumulation of AGEs in lamellar tissue at the beginning of the acute phase of laminitis, experimentally induced by hyperinsulinemia, has been demonstrated in a recent study by de Laat et al. (2012b). Additionally, they detected an upregulation of insulin-independent GLUT-1 gene expression after treatment with insulin intravenous infusions. Due to the fact that AGE accumulation was not detected during the developmental phase of laminitis but rather followed histological changes, it is supposed that AGE-RAGE interactions contribute to further lamellar damage but are not involved in the pathogenesis of laminitis (de Laat et al., 2012b).

Studies in human medicine have shown that insulin stimulates the vascular endothelial cells to release endothelin, which is a potent vasoconstrictor, whereas the NO production is impaired due to decreased insulin sensitivity. This imbalance leads to vasoconstriction and promotes platelet activation, leukocyte adhesion and subsequent leukocyte extravasation (Geor and Frank, 2009). An increased production of neutrophil-derived reactive oxygen species upon phagocytosis in correlation to serum insulin concentration has recently been established (Holbrook et al., 2012).

Contradicting the vasoconstriction theory, however, are the results of two independent human studies demonstrating that transient hyperinsulinemia led to vasodilation in the vascular bed of the forearm. Both studies found that insulin causes both sympathetic vasoconstrictor activation and vasodilation of the forearm vasculature, with the latter overriding the former (Anderson et al., 1991; Scott et al., 2002). However, if this vasodilation occurs in the equine digital arteriovenous shunts, the blood is withdrawn from the capillary bed, resulting in hypoperfusion and ischemia (Orsini et al., 2009). On the other hand, recent in vitro research on equine laminar veins has shown that insulin normally counteracts the venoconstriction

mediated by endothelin and alpha-adrenoreceptors. In the case of insulin resistance, this mechanism could be impaired and vasoconstriction would prevail (Keen et al., 2012).

Besides the effects of insulin on vascular dynamics, it is hypothesized to have an effect on metalloproteinase activity (Geor and Frank, 2009). MMPs are activated by oxidative stress (ROS), hypoperfusion and pro-inflammatory cytokines (Orsini et al., 2009). Laminin, the anchoring component between the epidermal basal cells and the lamellar basement membrane, is a substrate of these enzymes and their enhanced activity leads to dermo-epidermal separation (Pollitt, 2008).

Hyperinsulinemia also elicits increased plasma levels of inflammatory cytokines, namely tumor necrosis factor alpha and interleukin-6 (Suagee et al., 2011), accentuating the suggestion that insulin-induced inflammatory changes in the body contribute to laminitis.

OBESITY

Horses and ponies with equine metabolic syndrome are often in an overall obese nutritional state and/or have regional adiposity. Regional adiposity can most commonly be seen in the form of a pronounced neck crest, the so-called 'cresty neck'. Adipose tissue expansion is furthermore frequently found at the tail head, around the preputium in geldings and in the mammary gland region in mares. However, obesity doesn't inevitably lead to insulin resistance. The development of EMS or insulin resistance depends in large part on the breed and genetic background of the animal (Frank, 2011).

Adipose tissue, more precisely adipocytes and adipose tissue macrophages, is regarded as the largest endocrine organ in the body. It secretes a large number of cytokines that are referred to as adipokines. These bioactive substances include leptin, resistin, adiponectin and macrophage-derived pro-inflammatory cytokines like tumor necrosis factor alpha (TNF- α), interleukin 1 (IL-1 β) and interleukin 6 (IL-6) (Frank, 2011; Geor and Frank, 2009). Obese adipose tissue is marked by adipocyte hypertrophy and consequent angiogenesis, immune-cell infiltration and increased production of pro-inflammatory adipokines. It is therefore believed that obesity leads to a state of chronic, low-grade inflammation (Suganami and Ogawa, 2010). Obese adipose tissue produces high amounts of monocyte chemoattractant protein-1 (MCP-1). MCP-1 leads to increased infiltration of monocytes that differentiate into tissue macrophages. These macrophages in turn produce TNF- α and other pro-inflammatory cytokines (Suganami and Ogawa, 2010). Circulating TNF- α can inhibit insulin-receptor signalling in adipose tissue and skeletal muscle. Additionally, it alters endothelial function via up-regulation of adhesion molecules and cellular expression of endothelin-1, and it induces oxidative stress. Insulin-

stimulated production of nitric oxide, by contrast, is impaired due to inhibited insulin-receptor signalling (Geor and Frank, 2009). Leukocyte infiltration into digital lamellar tissue and vasoconstriction could be the consequences. In humans abdominal fat is supposed to have a greater inflammatory potential than that of other adipose storage locations. As horses and ponies with insulin resistance tend to store adipose tissue along the crest of their neck, this cresty neck might have a greater basal inflammation than other depots (Suagee et al., 2012). Besides contributing to the chronic inflammatory state, obesity can also contribute to insulin resistance and laminitis by its deleterious effect on the liver. The increased release of fatty acids into the portal circulation leads to lipid accumulation in the liver. Hepatic lipidosis can impair insulin hepatic clearance, which also makes a contribution to hyperinsulinemia. Furthermore, the clearance of endotoxins and other gut-derived trigger factors for laminitis would be aggrieved (Geor and Frank, 2009).

PITUITARY PARS INTERMEDIA DYSFUNCTION

Equine pituitary pars intermedia dysfunction (PPID) is a slowly progressing disease caused by an adenoma or adenomatous hypertrophy of the intermediate lobe of the hypophysis and is associated with an increased risk of laminitis. It is the most common endocrinologic disturbance in aged horses and affects more than 10% of horses older than 15 years (McGowan, 2005). Horses with PPID usually have a typical appearance. They are obese, have a cresty neck, supraorbital fat deposition and a long, curly haircoat that fails to shed (hirsutism) (Messer, 2007; Radostits et al., 2007). Another frequently observed clinical sign of PPID is polyuria and polydipsia. Possible mechanisms are that glycosuria causes osmotic diuresis or that the increased pituitary pars intermedia tissue impinges on the posterior pituitary gland and/or the hypothalamus, thereby interfering with the production and/or release of ADH (antidiuretic hormone) (McKenzie, 2007). Affected animals have increased serum glucose, cortisol, adrenocorticotrophic hormone and insulin concentrations (Pollitt, 2008).

PPID is also referred to as equine Cushing's disease, because the clinical appearance is similar to that in human Cushing's disease. In fact the disease in horses originates from the melanotropic cells rather than the corticotropin cells as in humans (Messer, 1999). The pars intermedia cells, the melanotropes, are inhibited by dopamine that is released by special neurons in the hypothalamus. Therefore it is supposed that a degeneration of those hypothalamic neurons and the resultant lack of inhibitory effect on the pars intermedia causes equine Cushing's disease (Eustace, 1991). In the absence of the inhibitory effect of dopamine,

melanotropes release uncontrolled amounts of pro-opiomelanocortin, which is in contrast to the corticotrope secretion of the adrenocorticotrophic hormone (ACTH) not under a negative feedback control by glucocorticoids. Pro-opiomelanocortin is converted into other active hormones including ACTH, which in turn stimulate the adrenal cortex to produce and secrete corticosteroids (Messer, 1999; Radostits et al., 2007). The excessive amount of circulating glucocorticoids predisposes the animal to infections, as glucocorticoids up-regulate anti-inflammatory proteins while they down-regulate pro-inflammatory proteins. Moreover, wound healing is delayed. Another effect of glucocorticoids is to increase the blood-glucose level. This is achieved by enhanced gluconeogenesis in the liver (the synthesis of glucose from glycerol or amino acids) and decreased glucose uptake in muscle and fat tissue. To generate amino acids and glycerol, a breakdown product of triglycerides, glucocorticoids stimulate fat and protein catabolism in adipose tissue and muscles respectively. Chronic hyperglycemia leads to the exhaustion of the glucose transport proteins. Consequently they are less responsive to insulin and insulin resistance develops. As a compensatory mechanism, the pancreas secretes larger amounts of insulin. A higher blood-insulin level can activate the glucose transporters and the blood-glucose level can return to normal. The persistent hyperinsulinemia in turn triggers laminitis (Sillence et al., 2007).

Glucose uptake by the digital lamellae seems to be rather independent of insulin, whereas the presence of insulin-dependent glucose transporters (GLUT-4) in the coronary band indicates that the coronary papillae, thus the hoof wall growth, depend on insulin-mediated glucose uptake to a greater degree (Sillence et al., 2007). Insulin-mediated glucose uptake is directly impaired by glucocorticoids, as they limit the movement of glucose transporters to the cell surface and cause an increased production of adrenalin receptors. Adrenalin further blocks glucose uptake by de-activating insulin receptors. Nevertheless, the simultaneous presence of a great number of insulin-independent GLUT-1 transporters shows that the coronary band is probably independent of insulin (Sillence et al., 2007).

Besides the direct effect of glucocorticoids, obesity and regional adipose tissue deposits can cause a state of low-grade chronic inflammation, contributing to the development of laminitis (Suagee et al., 2012; Suganami and Ogawa, 2010).

The pathophysiological mechanisms, by which insulin and obesity cause equine laminitis, have been discussed in more detail in the context of equine metabolic syndrome.

GLUCOCORTICOID THERAPY

Glucocorticoid drugs, such as betamethasone and methylprednisolone, are widely used to treat non-infectious inflammatory diseases. Corticosteroids, including glucocorticoids, mineralocorticoids and sex steroids, are endogenously produced by the adrenal gland. So far there is no evidence that mineralocorticoid or sex steroid administration would put the animal at a greater risk of equine laminitis (Bailey, 2010). Even though there hasn't been sufficient scientific research on glucocorticoid drug-induced laminitis, there have still been many cases reported. The presumption is that doses 8 to 10 times higher than the recommended therapeutic dose can trigger equine laminitis (Bailey, 2010).

A study in which healthy horses received 0.8 mg/kg dexamethasone intravenously every second day for 21 days was conducted by Tiley et al. (2007). Horses showed an increased mean plasma glucose concentration, a significant decrease in insulin sensitivity and an increased acute insulin response to glucose. Thus, long-term administration of glucocorticoids probably affects lamellar integrity mediated by high serum concentrations of insulin. Glucocorticoids cause a surge of insulin due to the stimulation of gluconeogenesis in the liver and a consequent rise in the blood-glucose level. Most of the synthetic glucocorticoids are more potent than endogenous cortisol and can lead to insulin resistance if administered for a prolonged time (Bailey, 2010). A chronic state of hyperglycemia can lead to exhaustion of glucose transport proteins. Subsequently, higher amounts of insulin are secreted to activate the glucose transporters and thus keep the blood-glucose level within its physiological range. The persistent hyperinsulinemia in turn triggers laminitis (Sillence et al., 2007).

Insulin-mediated glucose uptake is directly impaired by glucocorticoids, as they limit the movement of glucose transporters to the cell surface and cause an increased production of adrenalin receptors. Adrenalin further blocks glucose uptake by de-activating insulin receptors. However, the presence of a great number of insulin-independent GLUT-1 transporters indicates that the equine hoof's glucose uptake is rather independent of insulin (Sillence et al., 2007).

Furthermore, glucocorticoid therapy decreases protein (e.g. hoof keratin) synthesis, may impair the mucosal barrier of the intestine leading to increased absorption of harmful bacterial components, increase blood-vessel contractility, and delay the healing process of already damaged lamellar tissue (Bailey, 2010).

Ponies and horses with EMS or PPID are especially endangered by long-term administration or even a single high-dose administration of glucocorticoid drugs.

6.3 TRAUMATIC CAUSES

SUPPORTING LIMB LAMINITIS

Unilateral non-weight-bearing lameness can cause laminitis in the contralateral limb. As soon as the horse lifts one foot off the ground, the contralateral one bears the double weight, which accounts for 60-65% of the total bodyweight in the case of the front limb (Pollitt, 2008). Severe injuries, like complete fractures or sepsis involving a synovial structure, are extremely painful and might prevent the horse from completely or even partially loading the affected limb. Load-induced impairment of blood perfusion of the suspensory apparatus of the distal phalanx is the presumed cause of laminitis in the weight-bearing limb. When the limb is fully loaded, the vessels of the dorsal laminae are compressed and cannot be supplied with blood, as proven by venographic examinations on healthy hooves (Redden, 2004). Prolonged lack of perfusion is probably the reason for laminitis in cases of non-weight-bearing lameness in the contralateral leg. The horse's bodyweight, the duration for which the foot is fully loaded, and the structural properties of the hoof capsule, determine if and how severely the hoof will develop laminitis (Redden, 2004; Virgin et al., 2011). A hoof with a thin sole, low heels, hoof wall defects or a negative palmar angle³ is more prone to develop supporting limb laminitis than one with good conformation and integrity (Redden, 2004). The first clinical signs of laminitis often occur 3 to 6 weeks after the injury to the contralateral limb, but in severe cases lamellar pathology can occur after just 2 days of unrelieved and complete weight bearing (Pollitt, 2008; Redden, 2004).

Decreasing the tension of the deep digital flexor tendon by heel elevation and supporting the frog and sole with an elastic putty-like material can prevent supporting limb laminitis and should be accomplished as soon as possible. Heel elevation should result in a palmar angle of approximately 20° and moving the point of functional breakover backwards can provide additional comfort. The best time to do this is directly after surgical intervention on the injured leg while the horse is still recumbent under general anaesthesia. If the horse is not recumbent it should be suspended in a sling or at least the injured leg should be stabilized well enough to allow lifting of the contralateral limb in order to apply the above-mentioned mechanical support (Redden, 2004). Additional preventive measures include stabilizing the supporting limb with an elastic bandage and provision of deep bedding to encourage the horse to lie down, which relieves the weight load (Pollitt, 2008).

³ The palmar angle of the hoof is the angle of the palmar (or plantar) margin of the distal phalanx in relation to the ground surface and should be 3-5° in a healthy hoof (Redden, 2004).

ROAD FOUNDER

Overworking a horse on hard surfaces and/or a bad trimming or bad general hoof-horn condition can result in road founder, or concussion laminitis. In the past this type of laminitis was more frequently detected in heavy carriage horses (Rooney, n.d.).

Heavy bodyweight and a long toe contribute to laminitis when the horse is forced to move excessively on hard roads. The long toe in combination with the hard surface causes a difficult breakover at the end of the support phase of the stride, which exerts increased tearing forces acting on the dorsal lamellae. Traction of the deep digital flexor tendon on the distal phalanx causes additional stress on the lamellae in the toe region (Rooney, n.d.). Horses with a bodyweight more than 550 kg, are especially prone to road founder if exercised or worked on hard ground (Hamilton-Fletcher, 2004). Blood spots can sometimes be detected in the white line of horses with road founder. These bloody spots are thought to be haemorrhages originating from the disrupted laminae, descending into the white line (Rooney, n.d.).

However, even lightweight horses with a normal hoof shape can also suffer laminitis due to the excessive hammering caused by jumping or galloping on hard surfaces (Hamilton-Fletcher, 2004).

7. PATHOPHYSIOLOGIC THEORIES

A definite pathomechanism of the development of laminitis has not yet been established. However, there are several theoretical approaches. The author will deal with each of these theories separately, although they seem to be connected in some respects or interdependent.

7.1 ENZYME ACTIVATION (MATRIX METALLOPROTEINASE ACTIVITY)

Uncontrolled, excessive activation of matrix metalloproteinases (MMPs) causes lamellar separation. This theory was established first by the Australian Equine Laminitis Research Unit (Huntington et al., 2009). MMP-2 (gelatinase) and MMP-14 (membrane-type MMP or MT-MMP) have been detected in healthy equine digital lamellar tissue (Pollitt, 2008). MMP-9 (gelatinase) has also been detected in lamellar tissue explants collected during acute laminitis. However, it seems to be leukocyte-derived (de Laat et al., 2011b). Laminin and collagen, both main components of the lamellar extracellular matrix, basement membrane and the hemidesmosome anchoring filaments, are known substrates of these enzymes (Pollitt, 2008). Their lysis causes detachment of the epidermal lamellae from the basement membrane.

A staggered detachment and reattachment process is required for continual hoof wall growth and cellular movement within the lamellae. Furthermore, reconstruction after minor lamellar injuries is achieved with the help of MMP activity. To control MMP activity, tissue inhibitors of metalloproteinases (TIMPs) are almost simultaneously activated (Pollitt, 2008). An imbalance between TIMPs and MMPs can have pathological consequences in the body besides laminitis, such as cancer and osteoarthritis (de Laat et al., 2011b). The chances are that haematogenous delivery of certain laminitis trigger-factors from the gut, endometrium or other distant sites are responsible for the excessive release and activation of MMPs. Matrix metalloproteinases are secreted in an inactive form as zymogens, the so-called pro-MMPs, which are activated by proteases such as trypsin and plasmin (Bailey et al., 2004b). Pro-MMP release and pro-MT-MMP expression on the cell surface are induced by growth factors, bacterial components, reactive oxygen species, nitric oxide and inflammatory cytokines, such as tumor necrosis factor alpha or interleukins, which indicates a correlation between inflammation and MMP activity (Clutterbuck et al., 2010). *Streptococcus bovis*⁴-derived substances have been able to activate these enzymes in vitro (Pollitt, 2008).

A possible link between vascular alterations, inflammation and MMP activation is that ischemia due to vasoconstriction of the digital vessels could lead to the release of inflammatory mediators, which in turn brings about increased secretion and activation of metalloproteinases. Furthermore, the reperfusion of lamellar tissue after prolonged ischemia can trigger MMP expression due to reactive oxygen species and an inflammatory response (Clutterbuck et al., 2010).

Increased expression of MMP-2 has been documented in horses with experimentally induced carbohydrate overload and during flare-ups of naturally occurring chronic laminitis, but detection of increased amounts of activated MMP-2 or their zymogens has failed in cases of black walnut toxicosis, insulin-induced laminitis or naturally occurring cases of acute laminitis (de Laat et al., 2011b). Nevertheless, levels of pro-MMP-9 were reported to be increased in experimentally insulin-induced, carbohydrate overload-induced, acute and aggravated chronic laminitis (de Laat et al., 2011b; Loftus et al., 2009; Visser and Pollitt, 2011a). Another study proved an increased transcription of epidermal basal and parabasal cell-derived MMP-14 concomitant with a decreased transcription of TIMP-2 in tissue explants obtained from an oligofructose-induced laminitis model (Kyaw-Tanner, 2008).

⁴ *Streptococcus bovis* is one of the main bacteria responsible for lactate production during carbohydrate overload (Milinovich et al., 2010).

Interestingly, the snakebite of American lance-head vipers (*Bothrops* spp.) causes laminitis in the bitten and in the contralateral limb, characterized by lamellar basement membrane separation. Other clinical signs include pronounced edema, vesicles, blisters, severe pain, haemorrhages and coagulopathy (Acosta de Pérez et al., 2006). Acosta de Pérez et al. (2006) presumed that metalloproteinases in the venom of the snake are responsible for the dermo-epidermal separation. Previous work had proven the existence of a dimeric metalloproteinase in the venom of *Bothrops* spp. (Cominetti et al., 2003).

7.2 VASCULAR ALTERATIONS

Another common supposition about the pathophysiological mechanism behind equine laminitis is that vascular alterations are responsible for the impairment of the dermo-epidermal bond. Whether vasoconstriction or vasodilation is the pre-existing factor remains unclear. In the author's opinion both situations can lead to lamellar damage. It seems obvious that once dermo-epidermal separation has occurred (after the onset of lameness), thrombosis and vascular distortion can impair the digital blood supply, aggravating the condition and complicating lamellar healing. Whether a constricted or dilated vascular status initiates the destructive process probably depends on the underlying cause of laminitis.

VASOCONSTRICTION AND ISCHEMIA

Vasoconstriction and ischemia can contribute to laminitis in different ways. One consequence of decreased digital perfusion is the impeded supply of oxygen and glucose. However, the hoof lamellar metabolism appears to be mainly anaerobic, hence the oxygen demand is low (Pollitt, 2008). On the other hand, the digital laminae have a very high demand for glucose and its deprivation leads to lamellar collapse. An in-vitro study with lamellar explants has shown that the number of hemidesmosomes⁵ steadily decreased until they finally disappeared when the tissue was cultured in the absence of glucose (French and Pollitt, 2004).

Not only vasoconstriction but also redirection of the blood through dilated arteriovenous shunts leads to digital hypoperfusion, as the blood can bypass the capillary beds of the hoof. Arteriovenous anastomoses (AVAs) in the dermal lamellar microcirculation are capable of withdrawing 50% of the total limb blood flow when they are fully dilated. Dilatation of AVAs could also explain the pulsation of the digital arteries and the increased hoof temperature

⁵ Hemidesmosomes are attachment discs of the epidermal basal cells. They send out a vast number of anchoring filaments (laminin) to link the epidermal cells to the basement membrane (Pollitt, 2008).

during the developmental phase of laminitis while the digital laminae simultaneously suffer ischemia (Pollitt, 1991).

Bacterial endotoxins are known to trigger intravascular platelet aggregation, accumulation of leukocyte-platelet-aggregates and a subsequent increase in platelet-derived serotonin, which is a biogenic amine that can cause vascular alterations in the equine digital blood vessels (Davis and Palmer, 1965; Milinovich et al., 2010). Vasoactive amines, produced by hindgut bacteria, can also cause vasoconstriction in the equine feet if they enter the blood circulation (Bailey et al., 2004a). Furthermore, endothelin, a potent endogenous vasoconstrictor, has been identified in increased amounts in the laminar connective tissue of laminitic horses after acute carbohydrate overload (Katwa et al., 1999).

Equine digital veins seem much more sensitive to vasoconstricting substances than the digital arteries, leading to disproportionate venoconstriction, which in turn results in edema formation and microthrombosis (Orsini et al., 2009; Peroni et al., 2006). Microvascular thrombosis and compression of the digital capillaries by edema of the surrounding tissue further prevents digital blood flow.

Another argument for the involvement of ischemia in laminitis is the fact that laminitis can develop due to non-weight-bearing lameness in the contralateral limb. If the horse fully loads one leg, the sublamellar capillary bed is compressed and not supplied with blood, as venographic evidence shows. Prolonged hypoperfusion or ischemia is most probably the cause of supporting limb laminitis (Redden, 2004).

Another possibility is that ischemia indirectly affects the laminae due to reperfusion injury. If a tissue suffers prolonged ischemia and the blood supply suddenly returns, oxygen-free radicals are generated. Those free radicals can damage the vascular endothelial cells, leading to leukocyte and platelet adhesion (Bailey et al., 2004b).

VASODILATION

One of the earliest clinical symptoms of laminitis is in many cases an elevated hoof temperature, which leads to the conclusion that the digital blood flow is increased shortly before the onset of lameness (Huntington et al., 2009). Another aspect that militates against ischemia as a general cause of laminitis is that cryotherapy of the hooves and consequent vasoconstriction after induced carbohydrate overload or naturally occurring acute colitis, can prevent the onset of laminitis (Pollitt, 2008). However, the preventive effect of cold therapy can also be attributable to a decrease in metabolic and enzymatic (MMP) activity. In cases where inflammatory mediators, bacterial substances and other laminitis trigger-factors reach

the hoof on the haematogenous route, vasodilation would facilitate their harmful effect on the digital laminae (Pollitt, 2008).

Experiments with horses at risk of laminitis showed that most horses actually had increased hoof-lamellar temperature and thus the digital vasculature was dilated during the developmental phase of laminitis (Pollitt, 2008).

7.3 INFLAMMATORY MEDIATORS

Inflammation may be the common feature in all cases of equine laminitis.

The inflammatory events and histological changes detected early in laminitis are quite similar to those occurring in human sepsis leading to organ failure (Belknap et al., 2007). Thus Orsini and colleagues (2009) proposed that laminitis might simply be collateral damage from the body's defence against toxins or bacterial substances.

Marked upregulation of inflammatory cytokines, such as TNF- α , IL-1 β , IL-6 and IL-8, has been detected at an early stage of laminitis in the black walnut extract model, the carbohydrate overload model and in lipopolysaccharide-induced laminitis (Belknap et al., 2007; Suagee et al., 2011; Tadros and Frank, 2012). Interleukin 8 attracts and activates neutrophil granulocytes, which are correlated with MMP-9 expression in the lamellar tissue (Visser and Pollitt, 2011a). Thus, inflammatory mediators can trigger metalloproteinase activation in the digital laminae, thereby linking the MMP activity and the inflammatory mediator theory. Furthermore, pro-inflammatory cytokines cause vascular dysfunction, or more precisely, vasoconstriction, platelet and leukocyte activation (Huntington et al., 2009). Examination of laminar tissue explants from the carbohydrate-overload model has proved that leukocyte accumulation occurs prior to major histological changes, indicating that they contribute to basement membrane damage rather than being a consequence of it (Faleiros et al., 2011). In any case, there seems to be no doubt, that infectious inflammatory diseases, as well as other conditions, such as black walnut toxicosis and obesity, are important risk factors for laminitis and most probably act on the equine digital lamellae mediated by the pro-inflammatory response of the animal's body.

7.4 MECHANICAL TRAUMA

As described earlier, increased stresses on the suspensory apparatus of the distal phalanx, in terms of tension, shearing and concussion, can lead to mechanical damage to the dermo-epidermal bond. Examples are excessive galloping or jumping on hard surfaces or overworking a horse with poor-quality hooves and long toes on hard roads (Hamilton-Fletcher, 2004; Rooney, n.d.).

8. DIAGNOSIS

8.1 RADIOLOGY

Whereas acute laminitis is mainly diagnosed based on clinical signs, chronic laminitis can be diagnosed very well by means of radiographic images. X-rays of all hooves should be taken even in cases of acute laminitis in order to have a reference for subsequent examinations, and these should be repeated every 3 to 4 days in the initial period (van Eps, 2010a). Radiographs not only help in making a diagnosis, but are also useful in determining deteriorations of the condition or treatment results. The lateromedial radiograph of the hoof has probably the most diagnostic value. However, it is always advisable to take X-rays from a dorsopalmar/dorsoplantar and dorsopalmar/-plantar oblique view as well in order to diagnose mediolateral rotation and to check the integrity of the tip of the third phalanx.

Lateromedial X-rays can be used to evaluate the distance between the hoof wall and the distal phalanx. In healthy horses, the so-called hoof distal phalangeal distance (HDPD) never varies within one hoof and normally measures 16-18 mm⁶ (Pollitt, 2008). If the distal phalanx sinks vertically, the distance increases uniformly along the whole length of the dorsal outline of the distal phalanx. This can be difficult to detect without reference images. It might therefore be helpful to determine the length of the palmar cortex of the distal phalanx, which is measured from the tip of the pedal bone to its articulation with the navicular bone. The HDPD should be about 25% of this value (Pollitt, 2008) (**Figure 11, p. 46 below**). Cases of capsular or phalangeal rotation will be more obvious, since the HDPD will be greater in the distal aspect of the pedal bone (**Figure 12, p. 46 below**).

⁶ This HDPD refers to horses weighing 400-450kg (Pollitt, 2008).

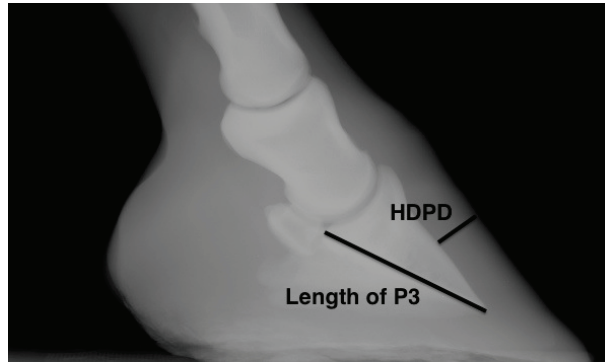


Figure 11: *Hoof distal phalangeal distance.* Source: own figure

The hoof distal phalangeal distance (HDPD) should be about 25% of the length of the P3, measured from its tip to its contact surface with the navicular bone (Pollitt, 2008).

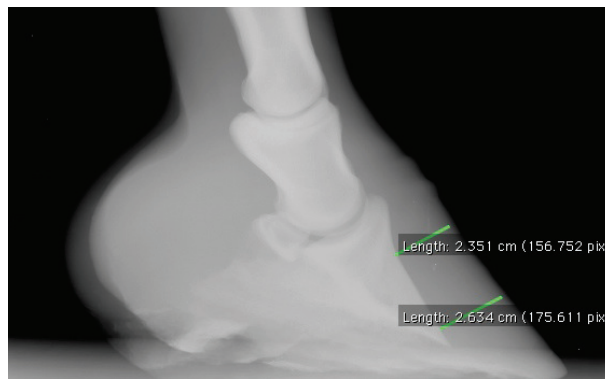


Figure 12: *Rotation of the P3 – Diagnostic measurement.* Source: own figure

The distance between the dorsal surface of the P3 and the hoof capsule is distally increased.

The quality of the radiographs is especially important for these measures. Prior to radiographic examination, the hooves should be cleaned and the shoes preferably removed. The X-ray beam should be in at right angles to the sagittal plane of the foot. The foot must be placed on a wooden block at least 10 cm thick, because the X-ray machine cannot be lowered closer than 10 cm to the ground. The practitioner should fix a metal bar to the top of the wooden block and a straight metal wire to the dorsal aspect of the hoof wall in its sagittal plane. These will serve as reference points to ensure exact measurements (Pollitt, 2008). Comparing the length of the metal wire with the length of its radiographic image enables the practitioner to detect and adjust magnifications on the X-ray picture. To correct the HDPD or other distances, the image distance should be multiplied by the actual length of the wire and divided by its image lengths (Eustace and Emery, 2009). A drawing pin can be pinned into the

apex of the frog as an orientation point for accurate placement of shoes and other supporting devices (Pollitt, 2008).

Another useful measurement is the distance between the extensor process of the third phalanx and the point where the sub-coronary horn (periople) changes from hard to soft (indicated by a radiolucent marker). This distance varies greatly among individuals or breeds, and measures 0-10 mm on average (van Eps, 2010a) (**Figure 13**). Nevertheless, it aids the detection of phalangeal displacement if the X-rays are taken consecutively.

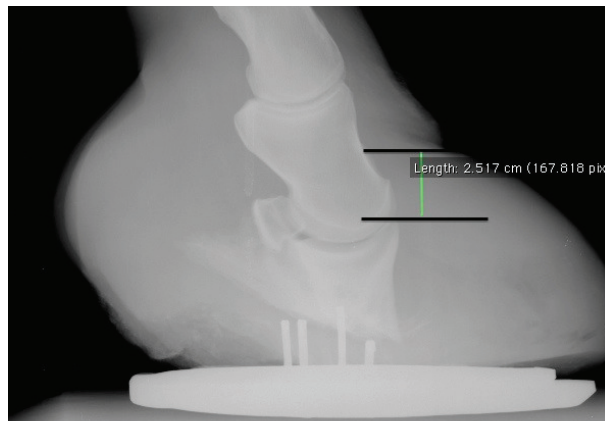


Figure 13: *Rotation and distal displacement of the P3.* Source: own figure

Severe rotation and distal displacement of the P3. The distance between the extensor process of the distal phalanx and the periople is severely increased. In healthy hooves this distance measures 0-10mm (van Eps, 2010a).

Lateromedial radiographs also reveal the distance between the tip of the coffin bone and the ground, the sole thickness and the angle of the solar surface of the distal phalanx relative to the ground (palmar angle) (O'Grady, 2010), which should be about 3-5° (Redden, 2004). The palmar angle increases in cases of capsular/phalangeal rotation.

In some advanced cases, a radiolucent line, beneath the dorsal hoof wall, can be seen on the lateromedial X-ray (**Figure 14, p. 48 below**). Contrary to the belief of some persons, that this line is produced by a seroma in the damaged lamellar tissue, it is more likely that the line reflects gas or air accumulation under the hoof capsule, as serum does not appear radiolucent on radiographic images. As long as the wall and sole horn are intact, air cannot infiltrate the space created by lamellar separation. This line probably reflects air that has entered through cracks in the hoof horn or gas that has been produced internally by bacteria (Eustace, 1992). Another explanation could be that the increasing distance between the hoof wall and distal phalanx creates a vacuum that extracts gaseous substances from the blood (Pollitt, 2008).

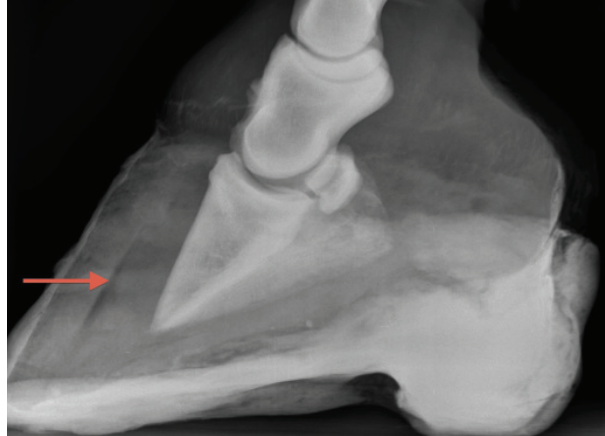


Figure 14: Radiolucent line on a lateromedial X-ray. Source: own figure

In this lateromedial X-ray of a cast hoof with dorsal capsular displacement of the distal phalanx, a radiolucent line (arrow) is clearly visible under the dorsal hoof capsule. This line reflects gas accumulation between the separated hoof capsule and the P3.

Dorsopalmar/Dorsoplantar X-rays are taken to assess a mediolateral rotation of the pedal bone. In cases of medial or lateral rotation, the interphalangeal joint space will be widened on the affected side and a line drawn across the articular surface of this joint or through the foramens of the semi lunar canal will not be parallel to the ground (O’Grady, 2010) (**Figure 15**).

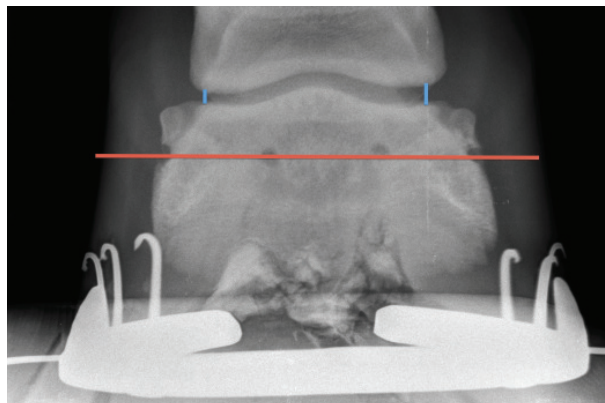


Figure 15: Mild mediolateral rotation of the P3. Source: own figure

To diagnose mediolateral rotation on a dorsopalmar/dorsoplantar X-ray, the space of the distal interphalangeal joint can be measured (blue lines), which will be increased on the side of rotation, or a line can be drawn either across the interphalangeal-joint surface of the P3 or through the foramen of the semi-lunar canals (red line). In cases of mediolateral rotation, this line will not be parallel to the ground (O’Grady, 2010).

Dorsopalmar/Dorsoplantar oblique X-rays show the tip of the distal phalanx, which might be undergoing pressure atrophy or progressive osteitis. Even fractures of the tip of the pedal bone can occur in severe cases of uncompensated chronic laminitis and can be detected on these oblique radiographs (Eustace, 1992; Rucker, 2010).

8.2 VENOGRAPHY

Venography (retrograde venous angiography) reveals vascular perfusion deficits of the equine hoof in a standing horse. The fact that the equine digital veins are valveless enables near complete retrograde filling with radiopaque contrast material (Pollitt, 2008). The horse should be sedated and abaxial sesamoid nerve block be performed on the selected limb to dilate the vessels. An elastic bandage should be tightly wrapped around the fetlock in a proximo-distal direction to further dilate the digital veins, eliminate the influence of blood pressure and to reduce venous blood flow. Thereafter, an indwelling catheter with extension tube is placed in the palmar/plantar digital vein. In most horses about 20-25 ml radiopaque contrast material can be injected. Digital radiographs should be taken immediately after the injection to prevent diffusion of the contrast material from the digital vasculature into the adjacent tissues. The horse must not load its full weight onto the investigated limb, as the dorsal sub-lamellar plexus cannot fill with blood under this pressure (Baldwin and Pollitt, 2010; Pollitt, 2008). By slightly pushing the horse's shoulder, the majority of the weight load will be shifted to the contralateral side, unloading the hoof under inspection.

Lateromedial venograms of healthy and non-weight-bearing hooves display the vessels of the terminal papillae at the distal end of the lamellae, the solar venous plexus, the circumflex vessels, the dorsal sub-lamellar venous plexus and the coronary plexus with the vessels of the coronary papillae (**Figure 16, p. 50 below**). In cases of chronic laminitis, a filling deficit of the coronary plexus and a widened blurred sub-lamellar plexus can be detected (**Figure 17, p. 50 below**). The latter is probably the result of the lamellar distortion and subsequent contrast leakage at the time of infusion. Inward-growing proximal hoof-horn tubules and the increasing lamellar wedge compress the coronary plexus and the dorsal sub-lamellar plexus respectively. As the third phalanx displaces distally, the terminal papillae form a visible notch dorsal to the rest of the circumflex vessels and the solar plexus becomes obliterated or even penetrated by the tip of the distal phalanx (Baldwin and Pollitt, 2010).

The severity of the disease is strongly associated with venous-filling deficits on the venographic images (Pollitt, 2008). Thus venography might be a helpful method for evaluating the animal's prognosis. Furthermore, this technique can be used to evaluate

vascular and dermal integrity and amelioration of the condition after carrying out therapeutic measures (Baldwin and Pollitt, 2010).

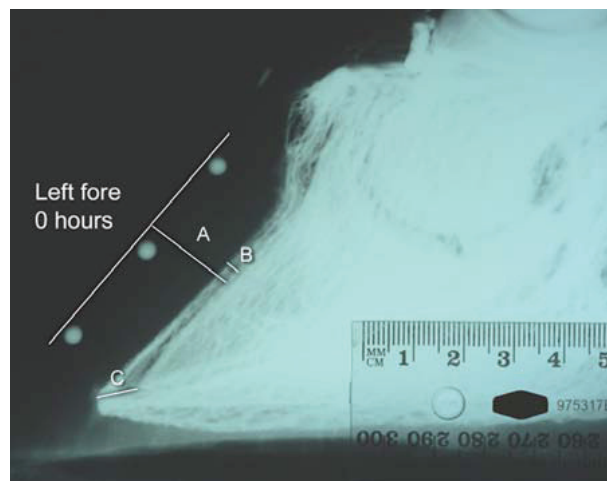


Figure 16: *Lateromedial venogram of a healthy front hoof.* Source: Pollitt, 2008

The HDPD (A), the width of the dorsal sublamellar venous plexus (B), and the distance between the circumflex vessels and the tip of the P3 (C) are highlighted.

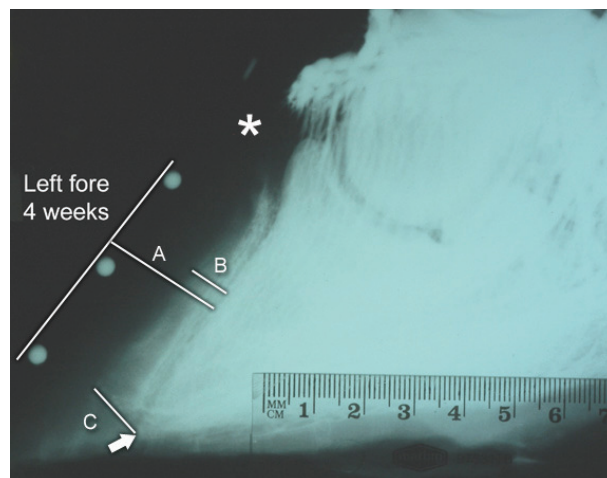


Figure 17: *Lateromedial venogram, 4 weeks after the development of acute laminitis.*

Source: Pollitt, 2008

The increased HDPD (A), the blurred and widened dorsal sublamellar venous plexus (B), and the increased distance between the circumflex vessels and the tip of the P3 (C) are highlighted. The filling deficit of the coronary plexus is also clearly visible (asterisk).

9. TREATMENT

9.1. MANAGEMENT AND CARE OF THE LAMINITIC HORSE

Laminitis hardly ever occurs without an underlying pathological condition. Therefore, the first step in laminitis therapy should be to identify the fundamental cause and to treat it effectively. In general, it is important to provide the laminitic horse with the best possible comfort and to avoid environmental or physical stress. Furthermore, frequent monitoring of the basic clinical values, the hoof temperature and intensity of the digital pulse is necessary to estimate the severity of pain and to react to it.

As soon as laminitis has been diagnosed, the horse should be confined to a stall and shouldn't be walked to decrease the stresses on the digital suspensory apparatus brought about at the breakover point during locomotion and by the tension of the deep digital flexor tendon (van Eps, 2010a). If possible, all following examinations should be performed on-site. As laminitic horses often have an increased body temperature and, if recumbent, will sweat underneath, making them prone to developing decubital ulcers, the environmental temperature should be kept below 16°C (Floyd, 2007c). In compensated chronic cases or after regression of clinical symptoms, stall rest should be continued but must be balanced with some light exercise to encourage normal function and growth of the hoof capsule by repeated expansion and contraction of the hoof (O'Grady, 2010).

Even though the procedure bears the risk of increased pain or further injury to the lamellae, conventional shoes should be removed, as they concentrate the animal's weight on the periphery and dorsal aspect of the foot. This can be achieved with minimal pain and damage if the horse is treated beforehand with abaxial sesamoid nerve blocks and if each nail is pulled individually (Parks, 2003; Rendle, 2006).

Deep bedding should be provided to encourage the horse to lie down, which unburdens the hooves and thus minimizes the pain. It also reduces concussion during locomotion and provides the possibility for the horse to find a counterbalanced stance and hoof tilt that decreases the pain and provides most comfort. Sand is probably the best choice as it moulds to the foot and supports the sole, but it is difficult to clean. Other suitable materials are deep shavings or straw (van Eps, 2010a). The recumbent horse should be encouraged to stand up several times per day to clean the bedding and loosen it up. This restores blood circulation to the body parts that were compressed and prevents decubital sore, which in turn would predispose the horse to septic myositis (Floyd, 2007c).

Tranquillizers and sedatives can be administered to contribute to recumbency (van Eps, 2010a). A more elaborate weight-reducing method is to suspend the horse in a sling (Reilly et al., 2010). However, a sling will not always be available and the procedure might expose the animal to unnecessary stress.

Horses or ponies with laminitis should be provided with good-quality, low-carbohydrate feed and water ad libitum. If the horse is recumbent, hay should be placed close to the horse's head and it might be necessary to hand-feed the animal (Floyd, 2007c).

9.2. HOOF CARE AND THERAPEUTIC SHOERING

Particularly in chronic cases of equine laminitis, supportive measures to stabilize the pedal bone and to contribute to the horse's comfort by reducing the pain are paramount. There are many different techniques and shoe systems, pre-fabricated or self-made, that can be beneficial. However, the choice of therapy should always be made on an individual basis according to the hoof conformation, horn quality, and the type of distal phalanx displacement.

HOOF TRIMMING

In chronic cases of laminitis where the third phalanx has rotated, hoof trimming is necessary to restore the physiological anatomic relationship between the pedal bone and hoof capsule, and should be performed before therapeutic shoeing. To restore normal orientation of the third phalanx to the ground of the hoof in cases of rotation, where the palmar angle is increased, the heels and quarters need to be trimmed back as much as possible. If required, the hoof capsule can be trimmed more on the medial or lateral side according to a lateral or medial displacement of the coffin bone (Morrison, 2010a). Radiographs can help to estimate the degree to which the heels have to be trimmed (O'Grady, 2010) (**Figure 18, p. 53 below**).

Care should be taken not to cause soreness by immoderate trimming. The live sole, characterized by a greater moisture content than the dead part, must not be invaded and the frog should only be trimmed back until it appears pliable (Morrison, 2010a; O'Grady, 2010). The normal angle between the solar surface of the pedal bone and the ground surface of the hoof is 3-5° (Redden, 2004). The sole under the tip of the phalanx should not be thinner than 15-20 mm, as this would predispose to bruising and pain. If the sole under the dorsal margin of the bone is already less than this reference value, only the part of the solar surface of the hoof that is thicker than 15-20 mm can be trimmed, which is commonly the area behind the widest point of the hoof. Consequently, this creates two planes on the ground surface of the

hoof. These two planes can either be gradually aligned to each other as the hoof capsule grows or the hoof should be trimmed bit by bit (O'Grady, 2010).

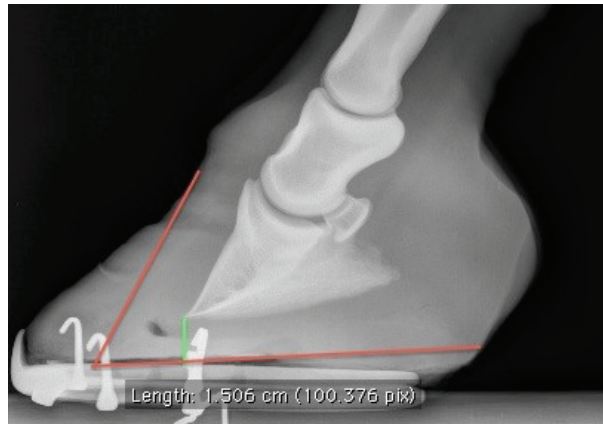


Figure 18: *Guidance for corrective hoof trimming.* Source: own figure

Lateromedial X-rays can be used as a guide for hoof trimming. The sole under the tip of the phalanx should not be thinner than 15-20 mm (green line), as this would predispose to bruising and pain (O'Grady). The red lines indicate the intended hoof-capsule shape.

Decreasing the height of the heels shifts the weight pressure from the stressed dorsal hoof wall more to the palmar/plantar half of the hoof. However, the disadvantage is that the deep digital flexor tendon (DDFT) is then put under greater tension, which is transferred to the dorsal lamellar interface, causing intense pain. This detrimental effect of hoof trimming can be reversed by means of therapeutic shoeing, including the backward shift of the breakover point and heel elevation, thereby restoring the original palmar angle (before the hoof trim) (Morrison, 2010a). As this obviously seems to counteract the effect of heel trimming, Morrison (2010a) gives a plausible explanation of why hoof trimming it is still advantageous. He explains that the goal is to achieve a different weight distribution. After re-establishing a normal orientation of the solar surface of the pedal bone to the ground of the hoof by trimming and subsequent heel elevation to decrease the DDFT, the palmar angle will be the same as before the procedure, but the weight of the horse will be supported by the wedges to a greater extent and therefore be shifted away from the dorsal digital lamellae (Morrison, 2010a).

It is also important to re-establish the correct relationship between the dorsal surface of the distal phalanx and the dorsal hoof wall. This can be achieved by rasping away the dorsal hoof wall until it is parallel to the dorsal surface of the pedal bone. The most recent horn at the

proximal part of the dorsal hoof wall serves as an orientation, as the new hoof horn usually grows in a parallel orientation to the displaced distal phalanx (Eustace, 1992) (**Figure 19**).

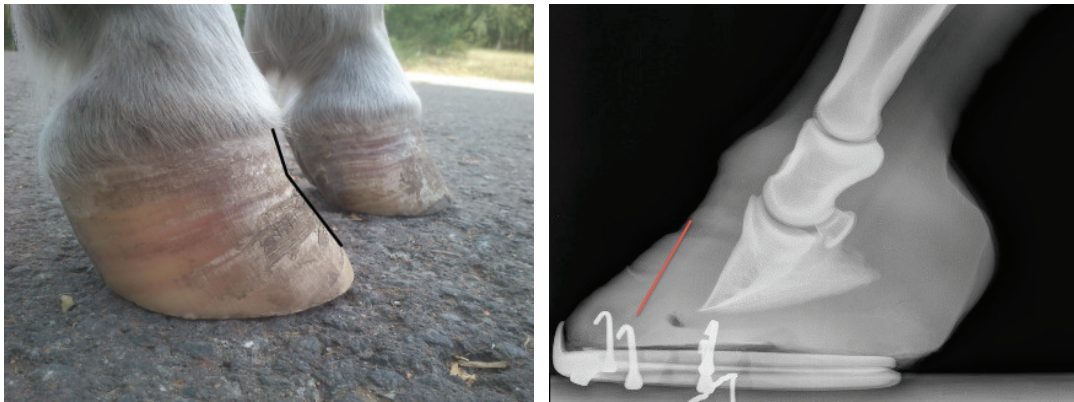


Figure 19: *Hoof wall growth after the rotation of the P3.* Source: own figure

The picture on the left shows the chronically affected hooves of a Shetland pony with EMS. The new proximal hoof wall is growing at a different angle to the ground than the older distal hoof wall (black lines).

The right picture shows a radiographic image of a hoof with rotated P3. The dorsal hoof wall grows parallel to the displaced P3 (red line).

HEEL ELEVATION

Raising the heels of the horse decreases the rotary forces on the distal phalanx caused by contraction of the deep digital flexor muscle. This tension can be decreased by almost 60% by creating a palmar angle of approximately 20° (Pollitt, 2008; Redden, 2004). To achieve this, Redden (2004) uses a heel elevation of 10° in combination with functional breakover-point relocation. As the pull of the deep digital flexor tendon causes increased damage and pain on the dorsal lamellae, many horses show immediate amelioration of lameness after heel elevation. Furthermore, heel elevation relocates the centre of pressure towards the heels, so the quarters and heels assume a greater portion of weight bearing to unburden the toe region (Morrison, 2010a). Prior to heel elevation, the hoof should be cleaned and trimmed. Raising the heels can be done by using wedged shoes, pads or rails. After the heel elevation the horse should just land heels first while walking (O'Grady, 2010). Radiographic images obtained before and after the procedure and measurement of the palmar angle will help to determine the correct amount of elevation.

Caution is advised in acute founder or sinker cases where heel elevation can cause aggravation of the condition, as it might increase the compression on the dorsal aspect of the coronary corium and thus could accelerate the vertical displacement process (Eustace, 1992). This opinion is supported by a recent study by Ramsey et al. (2011), who stated that raising the palmar angle could increase the load on the dorsal dermo-epidermal junction. Another contraindication is the mediolateral rotation of the third phalanx. Heel elevation might cause this condition to deteriorate (Morrison, 2010a).

If heel elevating devices or shoes are used over a long period of time, the deep digital flexor muscle and its tendon might undergo some intrinsic shortening. Sudden removal of the heel elevation can be harmful and should be accomplished gradually over time (O'Grady, 2010).

FROG AND SOLE SUPPORT

In most laminitis cases the laminae in the toe region of the hoof wall are affected most severely. Load on the wall should be reduced by recruiting the sole, frog and bars to bear weight. With the help of radiographs and a judicious hoof-tester examination, the site of greatest pain, where the tip of the third phalanx presses on the solar corium, can be identified on the sole and marked with a felt-tip pen. Sole support should be applied, preferably only palmar/plantar, to this mark. Common methods to support the sole include pads placed between the sole and shoe and application of synthetic composites, such as silicone, polyurethane, elastomer and dental impression materials. These materials conform perfectly with the sole surface and fill the space between the branches of the shoe; hence the entire solar surface can be loaded. The elasticity and hardness respectively can be adjusted according to the needs of the individual horse (Morrison, 2010a; O'Grady, 2010).

The frog can be supported by means of heart-bar shoes, frog pads or the above-mentioned synthetic composite (O'Grady, 2010). Ric Redden developed a frog-support device made of urethane, which is glued to the hoof and which he amusingly named 'lily pad' (Reilly et al., 2010). The frog support device/material should never protrude over the distal hoof wall margin, as in that case the frog would have to bear most of the weight (Eustace, 1992).

If a sole and/or frog support is used on an unshod hoof, they can be glued to the horn and additionally the hoof capsule, including the sole, can be wrapped with adhesive tape.

BRAKOVER POINT

Breakover refers to the moment during the horse's stride when the heels start to lift from the ground and the hoof rolls over. The point of breakover is the point that experiences the greatest stress during this moment, which is at the toe region of the hoof wall. Consequently the dorsal lamellae have to sustain an increased pressure. Directly before the moment of breakover, when the heels are still in contact with the ground, the deep digital flexor tendon exerts the greatest rotation force on the distal phalanx, which in turn sets the dorsal lamellae under further tension.

After separation of the dermo-epidermal bond has occurred, the weight of the animal and the aforementioned forces lead to displacement of the distal phalanx. To stabilize the pedal bone, to reduce the stress on the dorsal lamellae and to relieve some pain, the breakover point should be shifted backwards under the foot (Redden, 2004). This can be done by rounding over the toe of the shoe or by setting the shoe palmarly/plantarly. However, care should be taken to ensure that the toe of the shoe is not positioned immediately under the dorsal margin of the coffin bone, as this might increase the pressure on the tip of the bone (O'Grady, 2010). Heel elevation should be combined with adjustment of the breakover point to prevent crushing of the heels. This allows the horse to self-adjust the hoof angle and heel load by rolling forwards onto the toe or backwards onto the heels. How far backwards the breakover point has to be set depends on the palmar angle of the hoof. If the palmar angle is zero or negative, the breakover point should be under the centre of the distal interphalangeal joint (**Figure 20, p. 57 below**). In case of a positive palmar angle the breakover point should be slightly behind the dorsal margin of the coffin bone (Redden, 2004) (**Figure 20, p. 57 below**). Another method is to set the point of breakover directly under the most dorsal point of the coronary band (Morrison, 2010a).

O'Grady (2010) by contrast states that the breakover point should not be shifted palmarly to the tip of the third phalanx, as it decreases the area of ground surface, leading to instability of the foot. He suggests positioning the point of breakover some millimetres dorsal to it.

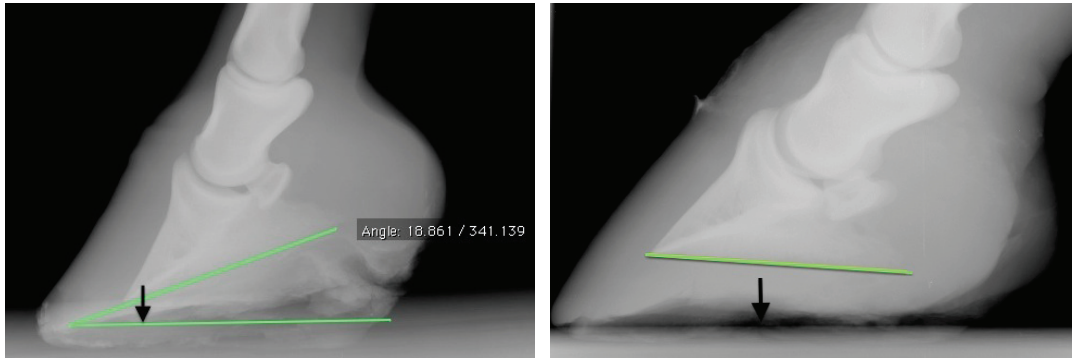


Figure 20: *Hoof palmar angle and breakover point.* Source: own figure

The left picture shows a hoof with mild chronic laminitis and a positive palmar angle, whereas the right picture shows a hoof with a negative palmar angle. The intended breakover point is indicated by arrows.

SHOE TYPES

A great variety of shoe types and systems are commercially available, or can easily be manufactured by a farrier or veterinarian. However, despite their simplicity, these shoes reduce the pain, stabilize the distal phalanx and support the healing process of the hoof. Before the application of any shoe, the hoof should be cleaned and trimmed, as described earlier. In this chapter only the most common orthotic devices will be presented.

Foam digital support

This is a simple, inexpensive and quick two-step procedure to support the sole and frog and thereby relieve some of the pressure on the dorsal laminae. Due to the yielding character of the material, the horse can decide which hoof angle provides the most comfort. Horses often show immediate amelioration of lameness after the application of foam digital support, which reflects the obtained pain relief. The foam digital support system is especially recommended in the acute phase of laminitis (Pollitt, 2008).

A 5-6-cm-thick block of foamed polystyrene (Styrofoam®) in the shape of the outline of the hoof should be prepared and can simply be taped to the hoof. The complete hoof and foam block should be wrapped with adhesive tape. This not only keeps the foam block in place, but also preserves it against soil and water (Pollitt, 2008). For reasons of balance, both front or/and both hind feet should be provided with the foam support. After 1 or 2 days the foam block will be compressed by the animal's bodyweight creating an impression of the sole, bars and frog. If the foam block is compressed to a thickness of 1-2 cm, it can be removed. Based on radiographs and a positive hoof-tester response, the position of the dorsal margin of the

distal phalanx can be determined under the sole and marked with a felt-tip pen on the solar surface. This mark is afterwards transferred to the compressed foam block and the part dorsal to the marking is chopped back. The palmar/plantar part serves as a sole and frog pad and is reapplied to the hoof and a new 5-6-cm-thick foam block is superimposed (**Figure 21**). Both are taped in place. This system usually lasts for several days (Pollitt, 2008).

Typically, the conventional shoes are removed prior to foam-pad application, but some practitioners claim that the shoes will reduce slippage of the pads (Reilly, 2010).

A disadvantage of the foam digital support system is that the foam blocks can completely collapse under heavy horses and will require frequent replacement (Reilly, 2010).

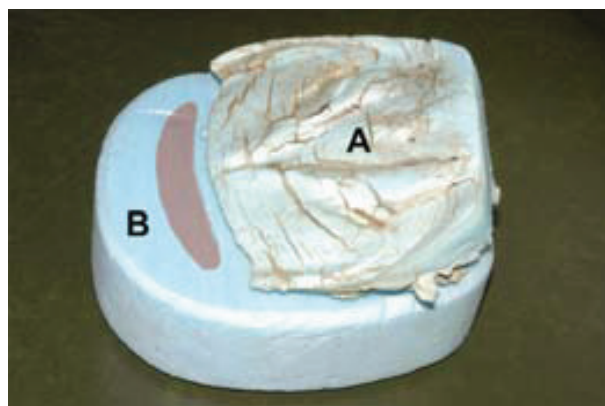


Figure 21: *Foam sole support.* Source: Pollitt, 2008

One foam pad (A) has already been applied to the hoof for approximately 2 days, so it is compressed and the dorsal part that was under the tip of the P3 (shaded area) has been removed. The new foam pad is placed beneath it (B) and both should be reattached to the laminitic hoof.

The Steward Clog

The Steward clog, named after its developer Mike Steward, is a rolled-toe, rolled-heel shoe. It is an orthotic device that offers relocation of the breakover point and even weight distribution over the solar surface (O'Grady, 2010) (**Figure 22, p. 59 below**). It can be combined with sole- and frog-supporting impression material and heel wedges. Commercially, the Steward clog is available in different versions: either made entirely of expanded ethylene vinyl acetate (EVA) or a combination of wood and EVA. The EVA enhances concussion absorption (Steward, n.d.).

The Steward clog can easily be made out of a piece of plywood, sawn out in the shape of the hoof. The toe region should be bevelled back to the favoured breakover point with a sanding disc. The heel edges and sides should also be rounded. This concentrates the load under the

distal phalanx and moves the medial and lateral weight-bearing surfaces axially (O’Grady, 2010; Pollitt, 2008). Because of this full roller motion, the shoe reduces the leveraging forces not only to the dorsal but also to the circumference of the digital dermo-epidermal bond (Steward, n.d.). If the sole of the hoof bulges out under the pressure of the tip of the distal phalanx, the opposing area in the clog should be hollowed out. To avoid the painful nailing procedure, the Steward clog can either be glued or screwed to the hoof. Screws should be placed in pre-drilled holes (O’Grady, 2010; Pollitt, 2008). In cases of mediolateral phalangeal displacement, it is advised to set the Steward clog tight on the affected side while letting it protrude on the opposite side. This technique shifts the weight pressure and the ground reaction force to the unaffected side of the hoof (O’Grady, 2010).



Figure 22: *Steward clog*. Source: photo courtesy of Gareth Keevil

In this case the clog has been nailed to the hoof, as this horse was not suffering from laminitis but from a fractured P3. If the clog is applied to a laminitic hoof it is recommended that it be screwed to the hoof capsule with the help of predrilled holes, or that special shoe-glue be used.

The Heart-bar Shoe

This shoe, that is roughly heart-shaped, engages the frog and heels in weight bearing. As the sole surface is left blank, the shoe doesn’t apply pressure to the solar corium to preserve its circulation (Reilly, 2010). The heart-bar shoe is often successfully used in combination with dorsal wall resection (Eustace and Caldwell, 1989).

The toe of the shoe should be slightly lifted off the ground in a way that resembles the tip of a snow ski, if viewed from the side. By rolling the toe, the breakover point will be shifted backwards. The frog should be trimmed to rest evenly upon the frog support plate, which has to be 2-3 mm above the level of and parallel to the shoe branches. The frog plate embodies a counterforce to the downwards-directed stresses on the digital lamellae. It is important to

know the location of the tip of the distal phalanx, since the frog-support plate must not be placed directly beneath it. On a lateromedial radiograph, a line should be drawn between the tip of the pedal bone and the end of its palmar/plantar processes. A second line is then drawn from the base of the extensor process of the phalanx perpendicularly to the first one. The point where both lines intersect is the correct location for the tip of the frog plate (Pollitt, 2008). The heart-bar shoe is available as a plastic or all-steel adjustable shoe, which can either be nailed or glued to the hoof, although the latter is preferred (Eustace, 1992).

The Wide-Web Aluminium Shoe

The wide-web aluminium shoe is, as its name suggests, a lightweight shoe with a wide robust web and a blunt toe. Its shape can easily be adjusted to the individual hoof conformation of the horse. By tapering the dorsal part and, if desired, the quarters of the shoe with a grinder, the point of breakover is relocated and mediolateral breakover facilitated. Impression material can be placed between the branches of the shoe and heel wedges can be added according to requirements. By means of special hoof adhesives, the shoe can be fixed to the hoof in a painless manner (O'Grady, 2010).

One version of this type of horseshoe is the Natural Balance Shoe™. It is a commercially available steel or aluminium wide-web shoe with rolled toe and is an element of the Equine Digit Support System (EDSS). Furthermore, the EDSS contains silicone impression material, frog pads, heel wedges and a plastic pad with built-in frog support (Pollitt, 2008) (**Figure 23**).



Figure 23: *Equine Digit Support System (EDSS)*. Source: photo courtesy of Gareth Keevil

The EDSS contains silicone impression material, frog pads, heel wedges, a plastic pad with built-in frog support and a steel or aluminium Natural Balance Shoe™. All the components of the EDSS are displayed in the pictures above. It must be mentioned that these photographs are only representative, as they demonstrate a case where the EDSS has been applied to a hoof with mediolateral imbalance, rather than laminitis.

Reverse Shoe

A reverse shoe looks much like a conventional horseshoe with shorter branches, except that it is attached to the hoof the other way round. Hence, the shoe has an open toe, which unburdens the dorsal aspect of the hoof and provides great pain relief since the heels and quarters carry most of the weight. To support these structures, the sole and space between the branches should be filled with impression material. The frog can also be recruited for weight bearing by the use of a reverse heart-bar shoe. In contrast to the original heart-bar shoe, the reverse one also has an open toe (White, 2005).

HOOF CASTING

It may be beneficial in horses with poor quality and integrity of the hoof capsule to apply a foot cast to stabilize the hoof wall and prevent bruising of the hoof. The cast also helps to protect the hoof from soil contamination and moisture, thereby creating a healthier environment for the equine foot (O'Grady, 2010). Hoof casts should be used in combination with appropriate impression material to fill the sole and to support the frog (O'Grady, 2010). Otherwise the rigid cast might cause increased pressure on the sole under the dorsal margin of the third phalanx, thus enhancing the compression of the blood vessels and increasing the pressure on the tip of the bone and the solar corium (Parks, 2003). Another advantage of this method is that the cast can be modulated to relocate the breakover point of the foot or to elevate the heels (O'Grady, 2010). Raising the heels can be accomplished by placing one roll of cast material about 2 cm palmar to the apex of the frog in a horizontal position. It should be adjusted to the structure of the frog, lateral sulci and bars. This should result in a palmar angle of 15-20° (Reilly et al., 2010).

The shape of the cast can either be influenced during the application process when the cast material is still pliable or afterwards by rasping and trimming. Radiographic images from a lateromedial and dorsopalmar/dorsoplantar view should be obtained to check the palmar angle and correct stance of the hoof.

In many cases a properly placed cast can remain on the hoof for more than a month (O'Grady, 2010). However, a regular radiographic examination of the hoof should be carried out to evaluate its position and to trace the progress of the disease.

9.3 MEDICATION

VASODILATORS AND ANTICOAGULANTS

Acepromazine (ACP) is frequently used to induce digital vasodilation and thus counteract possible hypoperfusion or ischemia of the digital lamellae during the developmental and acute phase. However, an increased digital blood supply following the application of ACP has not so far been proven. Nevertheless, due to its sedative effect, ACP discourages movement in the horse and encourages recumbency, which reduces pain and mechanical damage to the lamellae. It also reduces systemic hypertension, which is probably a result of severe digital pain (Rendle, 2006). Rendle (2006) recommends the administration of 0.06 mg/kg intravenously or 0.1-0.2 mg/kg orally 2 to 3 times per day, whereas van Eps (2010a) administers 0.02-0.04 mg/kg intramuscular or intravenous injections 4 times daily.

Isoxsuprine has β -adrenergic agonist and α -adrenergic antagonist properties and is thought to increase the digital blood flow mediated by vasodilation. It is also thought to have some rheologic properties (Parks, 2003). So far isoxsuprine has failed to induce digital and laminar hyperemia in several studies (Belknap, 2001).

Glyceryl trinitrate applied as an ointment to the skin above the digital vessels and to the coronary band can be converted to nitric oxide in the blood-vessel walls, triggering vasodilation. However, this effect has not been scientifically proven (Rendle, 2006). Furthermore, drug tolerance might occur rapidly in horses (Belknap, 2001).

Pentoxifylline, a methylxanthine derivative, has rheologic and anti-inflammatory effects. It causes the inhibition of tumor necrosis factor alpha (van Eps, 2010a). Pentoxifylline improves the blood-cell membrane deformability and consequently decreases blood viscosity (Belknap, 2001). Thus it is supposed to increase blood flow and inhibit platelet aggregation in the extremities and digital lamellae respectively and is usually administered at a dose of 7.5-8.5 mg/kg intravenously (Orsini, 2011; Rendle, 2006). However, recent research has shown that contrary to expectations, pentoxifylline hastens collagen-induced platelet aggregation in equine whole blood, and could consequently cause the deterioration of lamellar ischemia (Kornreich et al., 2010).

Heparin, with its anticoagulant effect, might be able to prevent laminitis if administered during the prodromal phase, but its effectiveness in the acute phase or even later is doubtful (Orsini, 2011; Parks, 2003). During the developmental phase it could inhibit the formation of microthrombi, which have been detected in lamellar tissues of acute laminitic horses (Weiss et al., 1994). As laminitis is usually not detected during this early phase, heparin is often administered too late to be of any use. However, 100-150 IU/kg can be administered subcutaneously twice a day (Rendle, 2006). Caution is advised as heparin can cause erythrocyte autoagglutination and further impair the lamellar blood supply. This detrimental effect has not been detected in combination with low-molecular-weight heparin, which is therefore recommended in the case of equine laminitis (Belknap, 2001).

ANTI-INFLAMMATORY DRUGS

Nonsteroidal anti-inflammatory drugs (NSAIDs), most commonly flunixin meglumine at 1.1 mg/kg or phenylbutazone at a dose of 2.2-4.4 mg/kg intravenously or orally twice a day, have an anti-inflammatory and analgesic effect (Rendle, 2006). Lower doses of only 0.5-1 mg/kg flunixin meglumine can also be effective (van Eps, 2010a). They are used to prevent the inflammation of the lamellar interface as well as against other underlying inflammatory diseases. Because these drugs are non-selective COX inhibitors, their effect on COX-1 receptors might have deleterious effects on the integrity of the gastric mucosa and the kidneys' perfusion and function respectively (Rendle, 2006).

Glucocorticoids, like hydrocortisone, methylprednisolone and betamethasone, are potent anti-inflammatory drugs and might be advantageous in the prevention and early treatment of SIRS-associated laminitis (Orsini, 2011). They should, however, only be administered in low doses as they may contribute to laminitis. In cases of PPID, glucocorticoids should be avoided.

PAIN MANAGEMENT

Reducing severe digital pain in order to lessen the animal's distress is paramount. However, it should be kept in mind that pain relief might encourage the animal to move, thereby aggravating the lamellar damage. It could also mask the clinical symptoms so that a possible deterioration or amelioration of the disease would be difficult to detect.

Nonsteroidal anti-inflammatory drug (NSAID) administration, most commonly flunixin meglumine at 1.1 mg/kg intravenously twice a day or phenylbutazone at a dose of 2.2-4.4 mg/kg intravenously or orally twice a day, results in sufficient analgesia in cases of mild to moderate laminitis. Because these drugs are non-selective COX inhibitors, their effect on COX-1 receptors might have deleterious effects on the integrity of the gastric mucosa and the kidneys' perfusion and function respectively (Rendle, 2006).

Fentanyl patches can be attached to the clipped skin if the digital pain is more severe and cannot be managed with NSAIDs. One or two patches, 10mg each, can be used and their effect usually lasts up to 2 days (Rendle, 2006).

Morphine, at a dose of 0.1 mg/kg, can be given intramuscularly in cases that are unresponsive to NSAIDs. Injections should be repeated every 4 hours. Morphine reduces gastrointestinal motility (Rendle, 2006). Measures should be taken to prevent an intestinal obstruction, for example the administration of paraffin oil via a nasogastric tube.

Lidocaine, administered as an intravenous bolus of 1.3 mg/kg followed by an intravenous infusion of 0.05 mg/kg/minute, can be substituted for morphine in cases where NSAIDs do not provide sufficient analgesia (Rendle, 2006; van Eps, 2010a).

ANTIOXIDANTS

Dimethylsulfoxide (DMSO) is an oxygen free-radical scavenger. Reactive oxygen species are produced as a result of reperfusion injury after a period of ischemia and are believed to trigger pro-MMP secretions as well as their activation (Clutterbuck et al., 2010). Additionally, DMSO inhibits platelet aggregation (Rendle, 2006). DMSO is commonly administered as an intravenous infusion at a dose of 0.1-1 g/kg in a 10% solution (Rendle, 2006). The concentration must remain below 20% to avoid intravascular haemolysis (Pollitt, 2008).

Selenium and Vitamin E can also be used as a feed supplementation in the laminitic horse or pony, based on their antioxidative properties and to support the immune system. The daily intake of selenium should be 0.1 mg/kg of diet at a minimum (Crandell, 1999). The maintenance dosage of vitamin E is about 1 IU/kg bodyweight per day and the amount of vitamin E supplementation should be adjusted to meet the horse's requirement according to the type of diet and general health status (Harper, 2002). Care must be taken when selenium is supplemented, as a dose of more than 2 mg/kg of diet can cause selenium poisoning, which may result in muscle damage, laminitis and even the death of the animal (Crandell, 1999; Stewart, 2003). It is therefore advised to monitor the blood selenium level before and during the period of administration.

ENDOTOXIN NEUTRALIZATION

Polymyxin B is an antibiotic drug used to combat Gram-negative bacteria, which can bind and inactivate lipopolysaccharides (endotoxins). Therefore, it can be auxiliary in cases where endotoxemia is suspected as an underlying disease. 3000-6000 IU/kg can be administered 3 times daily intravenously (van Eps, 2010a). Due to its nephrotoxic property, polymyxin B should be conjugated to dextran, which keeps it in the bloodstream (Belknap, 2001).

INSULIN SENSITIVITY MODULATION

Metformin, an anti-diabetic drug, has been successfully used to increase insulin sensitivity in horses and ponies at an oral dose of 15 mg/kg (van Eps, 2010a). By increasing the insulin sensitivity this drug could help to lower blood-insulin levels. Insulin is thought to trigger laminitis by either vascular changes or MMP activation.

METALLOPROTEINASE INHIBITORS

MMP inhibitors are under investigation in the treatment and control of equine laminitis (Pollitt, 2008). They can be administered as intraosseus infusions. Due to their high prices, systemic administration is usually not practicable (van Eps, 2010a). Doxycycline is infrequently used for its inhibitory effect on metalloproteinases. However, caution is advised, as MMP activity is required for repair and regeneration processes throughout the body, including the digital lamellae (Orsini et al., 2009).

9.4 SURGICAL PROCEDURES

DORSAL HOOF WALL RESECTION

Resection of the dorsal hoof wall provides drainage of haemorrhage and exudate, releases compression on the coronary corium, increases lamellar blood flow, allows removal of the lamellar wedge and necrotic tissue and leads to reorientation of the dermal papillae and tubular-horn growth to re-establish a normal hoof wall structure. Hoof wall resection should be performed at an early stage before the germinal cells of the hoof have suffered irreversible damage (Rucker, 2010). Venographic and radiologic examinations can aid in evaluating the timing of dorsal hoof wall resection. In contrast, Robert A. Eustace (2010) recommends not performing this surgical intervention earlier than 6 weeks after displacement of the distal phalanx. A study by Hertsch and Teschner (2011) established that a phalangeal rotation of at least 8° results in an alteration of the direction of hoof-horn growth, and therefore dorsal-wall resection would be a reasonable therapeutic approach in these cases.

Depending on the amount of hoof wall that is removed, the procedure is called either complete or partial hoof wall resection (**Figure 24**).

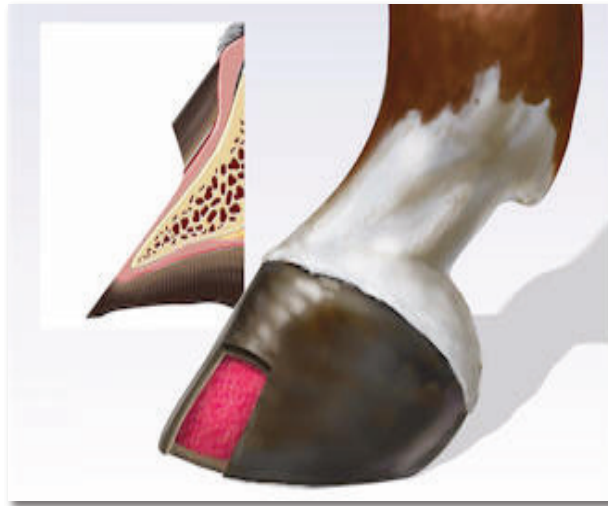

Figure 24: *Partial hoof wall resection.* Source: Parks, 1999

A window is cut into the epidermal layers of the hoof wall to allow drainage of haemorrhage and exudate, debridement of necrotic and hyperplastic tissue and to increase lamellar blood flow.

Strategic partial hoof wall resection, described by Amy Rucker (2010), is conducted by removing only the proximal part of the dorsal hoof wall, which impinges on the coronary band. This is especially necessary in cases where the proximal aspect of the hoof capsule is compressing the coronary corium and thus impairing new horn production. She advises performing venographic examinations to determine the venous-filling deficits of the coronary and sublamellar plexus and thereby estimating the required extent of wall resection (Rucker, 2010).

Generally, hoof wall resection can be carried out on a sedated horse in a standing position and is usually well tolerated by the animal. Prior to the procedure, an abaxial sesamoid nerve block is performed on the relevant limb. Starting beneath the coronary margin, two straight lines are cut into the hoof wall with the help of a rotating high-speed burr, either down to the sole or only as far down as determined by the venous filling deficit on the venogram. Both lines are distally connected. The cuts should continue until the hoof wall is pliable and the last epidermal layer can be cut with a sharp hoof knife. Dissection at the coronary band needs to be performed with great care so as not to damage the coronary papillae and should be done approximately 2 cm below the hairline (Morrison, 2010a; Rucker, 2010). The hoof wall should be cut as deep as the stratum internum. Then the hoof wall is peeled away from the corium using half-round nippers and a sharp hoof knife. Damage to the digital corium usually results in scar formation that will show up on the newly produced horn mass. After ablation of the dorsal part of the hoof wall, the underlying corium is gently massaged to induce haemorrhage and the coronary papillae should be stroked in a distal direction (Rucker, 2010). In cases where a lamellar wedge has formed, the hyperplastic epidermal tissue should be carefully pared back (Collins et al., 2010). A piece of surgical felt should then be cut to the correct shape and soaked in betadine solution before being placed on the exposed corium. Afterwards the hoof should be wrapped in an elasticated bandage so as to apply mild pressure on the corium, thereby preventing excessive granulation tissue formation. The bandage and betadine-soaked felt should be changed daily (Rucker, 2010). Some practitioners cover the exposed corium with sugardine, a mixture of granulated sugar and betadine, before application of the bandage (Eustace and Emery, 2009). To stabilize the hoof and restrict locomotion, the distal limb can alternatively be casted. In this case it might be advisable to place a catheter into the felt, so it can be regularly flushed with betadine solution without removing the cast each time (Rucker, 2010). Depending on the degree of dermal damage, the corium might start to cornify within a few days. The new hoof wall will grow from the coronary band downwards to the ground and the tubular structure will be restored in a parallel

direction to the surface of the distal phalanx (Rucker, 2010). It usually takes less than 12 months before the complete dorsal hoof wall is replaced (Wissdorf et al., 2002).

In some cases it will be enough to remove only a narrow horizontal strip of the dorsal wall distal to the coronary groove. This procedure is also referred to as ‘coronary-band grooving’ (Morrison, 2010a).

Another common method is to remove only the distal part of the hoof wall or, more precisely, the old hoof wall. If the new hoof wall seems to grow in normal parallel relation to the dorsal surface of the third phalanx and does not impinge on the coronary corium, only the part distally to it can be removed to allow debridement of the hyperplastic and necrotized epidermal tissue (O’Grady, 2010).

Some practitioners, however, claim that hoof wall resection would cause increased shearing stresses at the border of the resected part, associated with severe pain, and that the resection weakens the hoof structure significantly (White, 2005).

TOTAL HOOF WALL ABLATION

In cases of distal displacement or fatal founder syndrome, complete hoof wall ablation is frequently indicated. The procedure is followed by transcortical pinning of the cannon bone and limb casting, to keep the foot in a non-weight-bearing position (Floyd, 2007b). Fatal sinker syndrome is frequently seen in mares with septic metritis who develop laminitis with Obel grade 4 lameness and edema in all four limbs (Floyd, 2007b; Rucker, 2010).

The procedure can be performed under general anaesthesia or on the sedated horse with local anaesthesia. If it is done in a standing position, the horse should be supported by a sling. Two transcortical pins are inserted in the metacarpal or metatarsal bone. As the hoof capsule is commonly already loose and easily moveable, it can be removed as a whole with half-round nippers, starting at the heels from medial to lateral. Afterwards the exposed internal hoof structures are tightly covered with betadine-soaked felt and the whole limb, distal to the metacarpal/metatarsal joint, is casted. As the pins are embedded in the cast, the hoof can remain unloaded. The cast is frequently replaced and can be completely removed after 1 to 3 months. Deep digital flexor tenotomy is often indicated after complete wall resection (Floyd, 2007b; Rucker, 2010).

HOOF WALL DRILLING

Disruption of the dermo-epidermal junction, shearing forces caused by locomotion together with the tension exerted by the pull of the deep digital flexor tendon and the displacement of the distal phalanx lead to damage of the digital blood vessels and subsequent haemorrhages or seromas. The accumulation of fluids and edema formation results in an increased pressure against the non-yielding hoof capsule, which causes compression of the vascular beds and contributes to lamellar degeneration. This condition can be referred to as ‘compartment syndrome’. The increased hydrostatic pressure under the hoof capsule is associated with severe pain. To decompress the inner hoof structures, one or several holes can be drilled in the wall of the hoof. If a pocket of fluid is reached, it usually spurts out through the drilled hole due to the high pressure. After decompression the hole can be closed with a cotton swab, soaked in antimicrobial solution. Hoof wall drilling is a quick way to relieve pain and to re-establish lamellar blood flow. However, the fluid accumulation in the hoof is often compartmentalized or diffused and even large fluid-filled pockets cannot be detected on X-ray pictures. Therefore it is often necessary to drill several holes or to expand the procedure into partial hoof wall resection (Eustace, 1992; White, 2005).

DEEP DIGITAL FLEXOR TENOTOMY

Deep digital flexor tenotomy is indicated in uncompensated or recurrent cases of chronic equine laminitis that show no amelioration after other treatments, or in cases where the distal phalanx has stabilized but no hoof sole or wall growth is apparent and the animal displays persistent and severe discomfort (O’Grady, 2010). Deep digital flexor tenotomy can alleviate the pain in the affected hoof and increase the life quality of the horse or pony (Eastman et al., 1998). Additionally, a dramatic increase in horn growth can frequently be detected after the procedure (O’Grady, 2010). Transection of the deep digital flexor tendon (DDFT) shifts the centre of pressure directly beneath the centre of the distal phalanx and reduces the rotational force on the coffin bone, thus decreasing the shearing forces on the dorsal digital lamellae and restoring lamellar perfusion (Kramer, 2006; Morrison, 2010a).

Deep digital flexor tenotomy can be performed either in the mid-cannon or the mid-pastern region, but the latter has to be performed under general anaesthesia (Kramer, 2006). Another advantage of the mid-cannon deep digital flexor tenotomy is that afterwards the distal interphalangeal joint seems to be more stable than after a tenotomy performed in the mid-pastern region (O’Grady, 2010).

The surgical intervention is usually performed on a standing, sedated horse under local anaesthesia (high palmar-palmar nerve block). During the procedure, heel wedges should be placed under the hoof to decrease the tension on the DDFT. In the mid-cannon deep digital flexor tenotomy, a 3 cm long incision is made in the middle third of the metacarpus, between the proximal end of the digital flexor tendon sheath and the distal check ligament insertion site. The superficial digital flexor tendon, the suspensory ligament (interosseus muscle) and the DDFT are bluntly separated from each other and the DDFT is transected. After wound closure, a sterile dressing and a half-limb bandage is applied, which should be changed at least once a week until it can be completely removed after approximately 30 days. The horse should be confined to a stable or small paddock for the following 6 months. Exercise during this period is contraindicated (Kramer, 2006). New tendon fibres between the two ends of the DDFT are often produced after 3 months (Eustace, 1992).

Therapeutic shoeing techniques (plastic glue-on shoes) and hoof trimming should be executed preferably before the surgery to realign the relation of the distal phalanx to the ground and to mildly elevate the heels (2-3°). The latter prevents hyperextension of the distal interphalangeal joint (Morrison, 2010a; O'Grady, 2010).

In a study involving 37 horses suffering from chronic laminitis, deep digital flexor tenotomy in the mid-cannon region had a success rate of 60% (the horses were still alive at least 2 years after surgery). Most horses achieved pasture soundness and 10 horses even returned to light riding (Eastman et al., 1998).

9.5 ALTERNATIVE THERAPIES

CRYOTHERAPY

Cryotherapy of the equine feet during the developmental stage of laminitis has been proven to prevent dermo-epidermal separation, confirmed by histological examinations, and lameness in the oligofructose overload model and in cases of acute severe colitis (Pollitt, 2008). Cryotherapy is therefore thought to decelerate the destructive progress even if applied after the onset of lameness or to ameliorate the clinical outcome. Cooling of the hooves leads to vasoconstriction of the digital blood vessels, which in turn impairs the haematogenous delivery of laminitis trigger factors to the suspensory apparatus of the distal phalanx. A reduction in the lamellar tissue temperature of 10°C can reduce enzyme activity, including metalloproteinases, by 50%. Furthermore, cryotherapy limits pro-inflammatory cytokine production and leukocyte infiltration, and provides analgesia by reducing the conduction

velocity of the peripheral nerves. Although it might seem paradoxical to induce hypoperfusion in view of the fact that hypoperfusion is thought to be a possible pathomechanism in the development of laminitis, the cold-induced hypometabolic state protects the lamellar interface of ischemic injury by reducing its glucose demand (Pollitt, 2008; van Eps, 2010b).

Studies in which cryotherapy successfully prevented major histological lesions of the digital lamellae as well as lameness in the oligofructose overload model and naturally occurring cases of severe colitis, have given some indication of its implementation. The horses were standing in a plastic tub filled with a mixture of ice and water reaching as far as the upper third of the cannon bone. The temperature of the ice and water immersion was always kept below 5°C by refilling regularly with cubed ice. In the first study the duration of the cryotherapy was about 48 hours, while in the subsequent studies it was prolonged to 72 hours. None of the horses showed increased discomfort in association with the cryotherapy and no deleterious effects have been reported in these or other studies (Pollitt, 2008; van Eps, 2010b). The outer hoof wall temperature can be used as a guideline for the temperature that is achieved inside the hoof capsule at the dermo-epidermal junction, as it is usually 2-3°C lower than the inner temperature. During distal limb cryotherapy the hoof wall surface temperature should be maintained below 10°C (van Eps, 2010b). Although ice-packs and cold-gel applications are commercially available for the distal limbs or hooves of horses, they seem to be less effective than the ice and water immersion bath. These commercial cooling devices usually fail to reduce the hoof wall temperature below 20°C (van Eps, 2010b).

Andrew W. van Eps (2010b) generally applies cryotherapy for up to 7 days after the onset of acute laminitis, to relieve pain, reduce lamellar inflammation and inhibit further damage by MMP activity. Furthermore, cryotherapy can be beneficial in the acute phase as it reduces leakage of blood or serum from disrupted blood vessels. However, he points out that cryotherapy is contraindicated in cases where there are infectious diseases inside the hoof, such as abscesses and septic osteitis, as hypothermia reduces the natural inflammatory response (van Eps, 2010b). Rewarming of the limbs after cessation of the treatment should be performed gradually over a period of 12 to 24 hours if possible, to maintain the protective effect of cryotherapy (van Eps, 2010b).

In the later stages of laminitis, cryotherapy is probably of no advantage and could even interfere with the lamellar healing process. Conversely, topical heat application might be beneficial in compensated chronic laminitis, as it increases the connective tissue plasticity and stimulates blood flow to accelerate the healing process (Worster et al., 2001).

MAGGOT DEBRIDEMENT THERAPY

Maggot debridement therapy is a non-invasive and effective method for treating complications of chronic equine laminitis, such as solar penetration, osteitis and tissue necrosis, and can act as a preventive measure against more serious infections (Morrison, 2010b) (**Figure 25**).

The beneficial effect of maggot debridement was first noticed during the 16th century and is nowadays well established for chronic wound management in human patients. Most commonly used are the larvae of the green bottle fly (*Lucilia sericata*), because of their non-invasive character. The freshly hatched larvae measure 1-2 mm and mature to a size of 1cm within 4 to 5 days before they pupate. Only sterile larvae should be used for medical purposes, to prevent wound contamination. The larvae feed on necrotic tissue by secreting/excreting proteolytic enzymes, which degrade extracellular matrix. Their excretions also contain antibiotic substances which combat Gram-negative as well as Gram-positive bacteria. Maggot debridement therapy also enhances wound healing by a not yet completely clarified mechanism (Chan et al., 2007). It is thought that the maggots' physical movement and salivary secretions promote granulation tissue formation (Morrison, 2010b). Maggot debridement therapy is also indicated in cases where antibiotic resistance has developed (Chan et al., 2007).

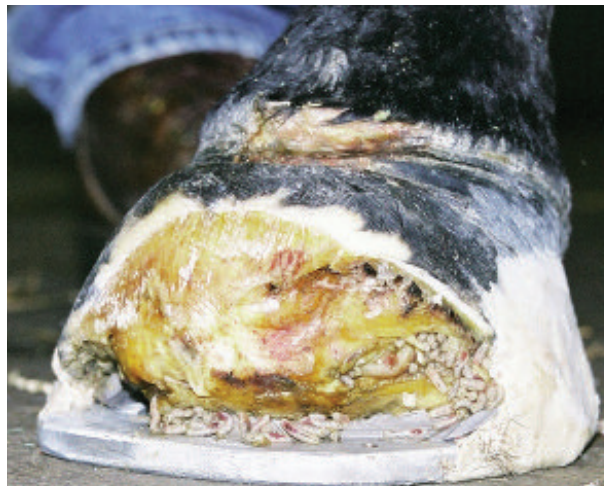

Figure 25: *Maggot debridement therapy.* Source: Jurga, with Morrison, 2006

The image shows maggot debridement therapy in a case of osteitis as a complication of chronic laminitis.

Equine hooves affected by chronic laminitis are usually characterized by compromised blood flow, necrotic tissue and infections. Scott Morrison (2010b) describes maggot debridement as an inexpensive and advantageous therapy in cases of chronic laminitis. The hatched larvae should be applied within 2 to 3 days or kept in a refrigerator if intended for later use. Morrison recommends a dose of 10 larvae per square centimetre of necrotic tissue. The larvae can be applied to a pre-existing (e.g. solar corium and distal phalanx prolapse) or purposely created opening in the hoof capsule (e.g. hoof wall resection or hoof wall drilling). Prior to maggot application, the wound should be cleaned of loose necrotic tissue and flushed with saline. An absorbent layer of gauze is used to cover the site. The hoof can then be cast and a window cut into the cast just above the wound to facilitate wound management (Morrison, 2010b). It is important to ensure sufficient oxygen supply and moisture at the wound site, to maintain an environment in which the larvae are active and can survive (Chan et al., 2007). The gauze should be changed at least every second day and the maggots must be replaced after approximately 5 days, when they have reached maturity (Morrison, 2010b). The only side-effects of maggot debridement therapy observed so far are irritation or allergic reactions at the application site (Morrison, 2010b).

10. PREVENTION

Horses and ponies at risk of laminitis should receive special attention from their owner, their veterinarian and their farrier. Only by the close collaboration of these parties can laminitis be prevented; at least in some cases. Preventive management and measures depend not only on the underlying disease or risk factors for laminitis, but also on the individual animal. Its general health status, bodyweight, hoof conformation, horn quality, environmental circumstances and many other factors can influence the effectiveness of preventive measures. Here the author would like to present briefly some promising general methods for the prevention of laminitis.

Equids, especially ponies, that are obese are prone to become insulin-resistant and are therefore at higher risk of laminitis. Dietary restrictions and regular exercise can improve the body condition. Grazing on lush pastures should be restricted. If the owner wishes to keep the horse on a pasture or if alternatives are limited, a grazing muzzle can decrease the grass consumed, and thus the carbohydrate intake. Horses or ponies that have been diagnosed with insulin resistance or that suffer recurrent bouts of laminitis should be removed from lush pastures and fed feedstuffs with a low glycaemic index. Although it may be rather labour-

intensive as a preventive measure, soaking the hay in cold or hot water for 60 and 30 minutes respectively can remove up to 56% of sugars and fructans (water-soluble carbohydrates or WSC) and this should be included in the management of horses or ponies with acute insulin-induced or carbohydrate overload-induced laminitis to prevent aggravation of the pathological process. After the leaching procedure, the water must be strained off and disposed of, as it will contain the dissolved WSC (Sillence et al., 2007; Watts and Pollitt, 2010).

Research has shown that prophylactic dietary supplementation with 0.05-0.07 g/kg bodyweight short-chain fructooligosaccharides (scFOS) per day might prevent the clinical symptoms, including laminitis, associated with starch overfeeding, by inhibiting the overgrowth of potentially pathogenic bacteria (Respondek et al., 2008). A subsequent study proved that long-term administration of prebiotic fibres, such as short-chain fructooligosaccharides, can increase insulin sensitivity in obese horses. In the course of this trial, horses were provided with 45g scFOS per day for a period of 6 weeks, top-dressed on a meal of grains. All the horses remained healthy, showed an unaltered body condition score or bodyweight, but their acute insulin response to glucose was reduced and their insulin sensitivity enhanced (Respondek et al., 2011). Another approved preventive treatment for carbohydrate overload represents the formulation Founderguard®, containing virginiamycin. If a dosage of 5 g/kg bodyweight is administered at least 4 days before carbohydrate overload, Founderguard® can effectively prevent consequent laminitis by inhibiting the activity of lactic acid-producing bacteria (Pollitt, 2008).

Horses presenting with severe colic or inflammatory conditions that show signs of endotoxemia should receive continuous cryotherapy⁷ to prevent acute laminitis. The duration of the therapy should be at least as long as the clinical symptoms are apparent and should preferably be prolonged for another 24 to 48 hours after their resolution (van Eps, 2010b).

In cases of non-weight-bearing lameness, immediate surgical treatment of the lame limb combined with heel elevation, adjustment of the breakover point, arch support and sufficient stabilization of the non-affected limb can prevent laminitis in the supporting limb (Redden, 2005).

In summary, it can be stated that the best way to prevent equine laminitis is to prevent or control the laminitis risk factors and to provide adequate hoof care.

⁷ Further information can be found under section 9.5.

RETROSPECTIVE STUDY ON EQUINE LAMINITIS

MATERIALS AND METHODS

Medical records of all cases of equine laminitis at the SZIE-ÁOTK Clinic for Large Animals, Üllő, Hungary, between January 1, 2008 and November 20, 2012 were reviewed. The cases for this study were selected on the basis of prolonged appearance of clinical symptoms of acute laminitis, including acute lameness, digital pain, an exaggerated digital pulse and an increased hoof wall temperature, or based on the interpretation of lateromedial X-rays in cases of chronic laminitis. Most of the horses and ponies under investigation were referred to the clinic from Hungary, several from Romania, one horse from Slovakia and one from Denmark. 41 animals were hospitalized at the clinic, while one horse was euthanized after less than 24 hours and 5 horses were simply brought to the clinic for a lameness examination and were released on the same day. The horses' signalment, the progress of laminitis, the underlying cause, the number and type of affected limbs, the treatment during hospitalization and any information about a performed surgery or euthanasia were obtained from the medical records. However, as two of the horses had been purchased just before the onset of laminitis, the history of these horses remained incomplete. In November 2012, information about the current soundness and condition of the hooves of the majority of the horses was obtained from telephone conversations with the owners.

To determine the frequency of laminitis among all hospital patients as well as among all animals with intestinal disorders or lameness, all medical records during the years 2009 and 2010 were counted to receive an average number of horses and ponies that have been treated at the SZIE-ÁOTK Clinic for Large Animals per year. Among these cases, the number of animals with intestinal diseases or lameness was determined according to the information obtained from the medical records.

In cases of acute laminitis, the animals were treated with intramuscular injections of acepromazine and subcutaneous injections of heparin to prevent a progression of the disease. Stallions were not treated with acepromazine because of the possible side effect of penile paralysis. In addition, all horses and ponies received flunixin meglumine or phenylbutazone, orally or intravenously, lidocaine intravenous infusions or intramuscular injections of morphine, according to the degree of pain. In cases where there was pronounced increase in hoof wall temperature, cooling packs were bandaged to the distal limbs at intervals. Three animals with chronic laminitis – one horse with PPID, one horse with severe pleuropneumonia and one pony with EMS – were administered pentoxifylline as oral tablets.

Patients with severe colic symptoms were also treated with dimethylsulfoxide by way of intravenous infusions. In addition to the medical treatment, hoof casts, including heel elevations to achieve a palmar angle of 15-20°, were applied to the hooves of animals with symptoms of acute or progressive chronic laminitis. In most cases of acute front-limb laminitis, the hind limbs were also cast as a preventive measure. The degree of heel elevation was evaluated by means of radiological examinations. A few horses with severe chronic laminitis were treated with Styrofoam or silicone pads prior to the application of hoof casts. Animals with chronic laminitis or those that showed severe pain were confined to horseboxes with soil-covered floors and a deep straw bedding. In cases of compensated chronic laminitis with displacement of the distal phalanx, the hooves were treated by a farrier, working in close collaboration with the equine clinic. The hooves were trimmed to create a normal realignment between the distal phalanx and the hoof capsule. In some chronic compensated cases of laminitis, the hooves were shod with reverse shoes. Other therapeutic hoof treatments conducted by local farriers after the animals' discharge from the clinic could not be documented.

RESULTS

The study involved 42 horses and 5 ponies. Among these 47 animals, there were 21 mares, 9 stallions and 17 geldings. The average age of the horses and ponies was 10.6 years, ranging from 2 to 26. Among the 42 horses were 9 Hungarian Half Breds, 7 Hungarian Sport Horses, 6 English Thoroughbreds and 4 Friesians, with other breeds represented in smaller numbers. 53.66% (22/41) of the animals suffered from acute laminitis only, while in 46.34% (19/41) of the cases, the disease progressed to the chronic stage. In 6 of the acute cases, the animals had to be euthanized during the acute phase of laminitis because of the severity of the concurrent diseases. As a possible progression of the disease was unpredictable in these animals, they were excluded from the previous calculation.

The distribution of the different causes of the development of equine laminitis, rounded to two decimal places, was as follows: 34.04% (16/47) intestinal disorders other than carbohydrate overload; 17.02% (8/47) carbohydrate overload; 8.51% (4/47) respiratory disorders; 4.26% (2/47) supporting limb laminitis; 4.26% (2/47) dystocia; 4.26% (2/47) equine metabolic syndrome (EMS); 2.13% (1/47) pituitary pars intermedia dysfunction (PPID); and 25.53% (12/47) others (**Figure 26, p. 77 below**).

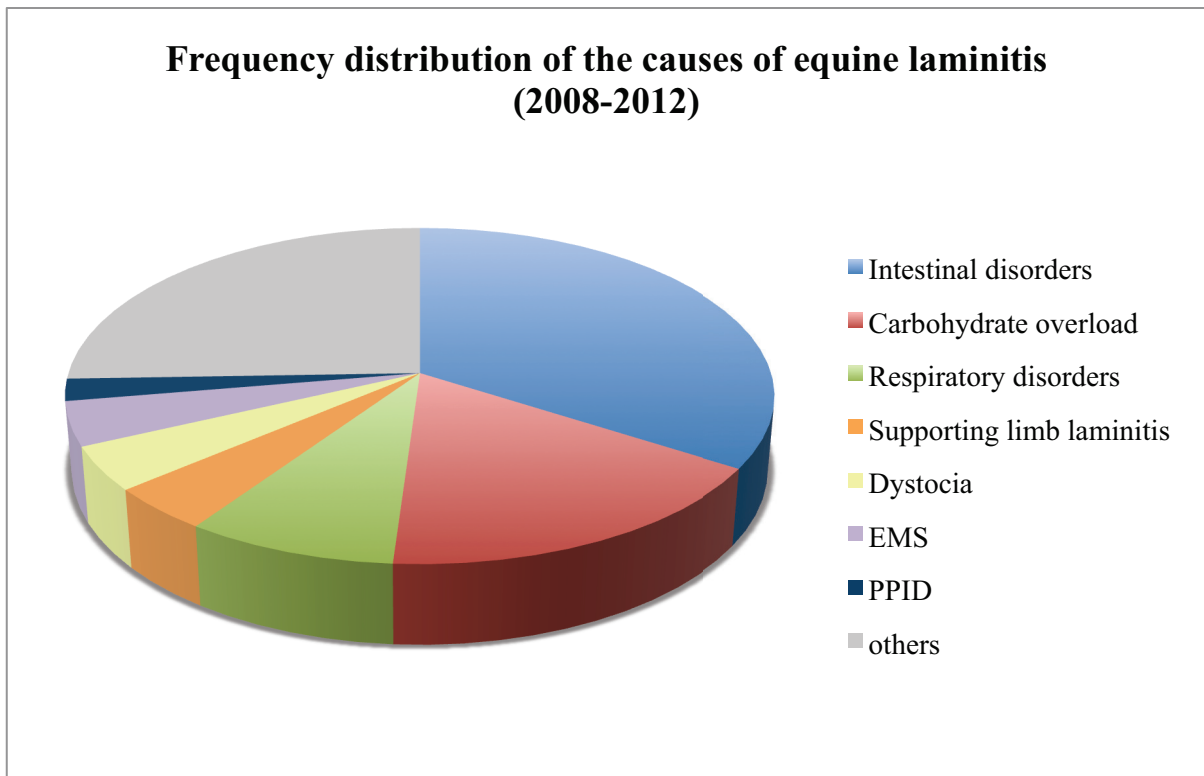


Figure 26: *Frequency distribution of the causes of equine laminitis.* Source: own figure

One pony was suffering from equine metabolic syndrome and large intestinal obstruction at the time of admission, but as it had already developed chronic laminitis at that time, EMS was thought to be the cause of laminitis. Acute carbohydrate overload, as in most cases of grain overfeeding, leads to alterations in the large intestinal flora and deficiency of the mucosal barrier allowing laminitis trigger-factors to enter the blood stream (Pollitt, 2008). Furthermore, in cases of grain overfeeding, most of the horses in this study showed colic symptoms and one horse even underwent colic surgery in order to flush out the large intestine. So carbohydrate overload could also be referred to as an ‘intestinal disorder’. However, due to the fact that the resulting hyperinsulinemia contributes to the development of equine laminitis and may be the main trigger-factor in cases of pasture-induced laminitis, carbohydrate overload has been addressed in a separate category. Among the 8 cases of carbohydrate overload, 6 cases were reported to be caused by excessive grain intake and 2 ponies were suffering from pasture-induced laminitis. The cause of equine laminitis in 12 out of the 47 cases were unspecified. They are summarized under the category ‘others’. Two of these horses had been purchased just prior to the onset of laminitis, so their history was not known. One horse and one pony were presented to the clinic with neurological symptoms and developed acute laminitis during their hospitalization. One horse suffering from chronic laminitis was diagnosed with a malignant melanoma and chronic wasting. As there was no

definite diagnosis, these cases were also included under the category ‘others’. In the remaining 7 indeterminate cases, the horses had no history of other diseases, so it is most probable that laminitis was caused either by carbohydrate overload or concussion of the hooves (road founder).

Of the 25% (3/12) of horses and ponies with laminitis caused by an intestinal disorder, the disease ran a chronic course with rotation and/or distal displacement of the distal phalanx. Most (75%; 9/12) of the animals in this category recovered after the acute phase. Four of the 16 animals with intestinal disorders had to be excluded, as they were euthanized during the acute stage of the disease. The prevalence of chronic laminitis among the animals with carbohydrate-induced laminitis was 62.5% (5/8), including both cases of pasture-induced laminitis, and only 37.5% (3/8) of the cases remained acute. In both ponies with pasture-induced laminitis, the disease progressed to a chronic stage. The two animals with EMS and the horse with PPID both developed chronic laminitis. In the category ‘respiratory disorders’ 2 horses were euthanized during the acute phase of laminitis, whereas the disease ran a chronic course in the remaining 2 horses. Of the 2 horses with dystocia, one suffered from chronic and one only from acute laminitis. Both cases of supporting limb laminitis remained acute. And of the 12 animals with an unspecified cause of laminitis, 58.33% (7/12) horses had acute and 41.67% (5/12) chronic laminitis (**Figure 27**).

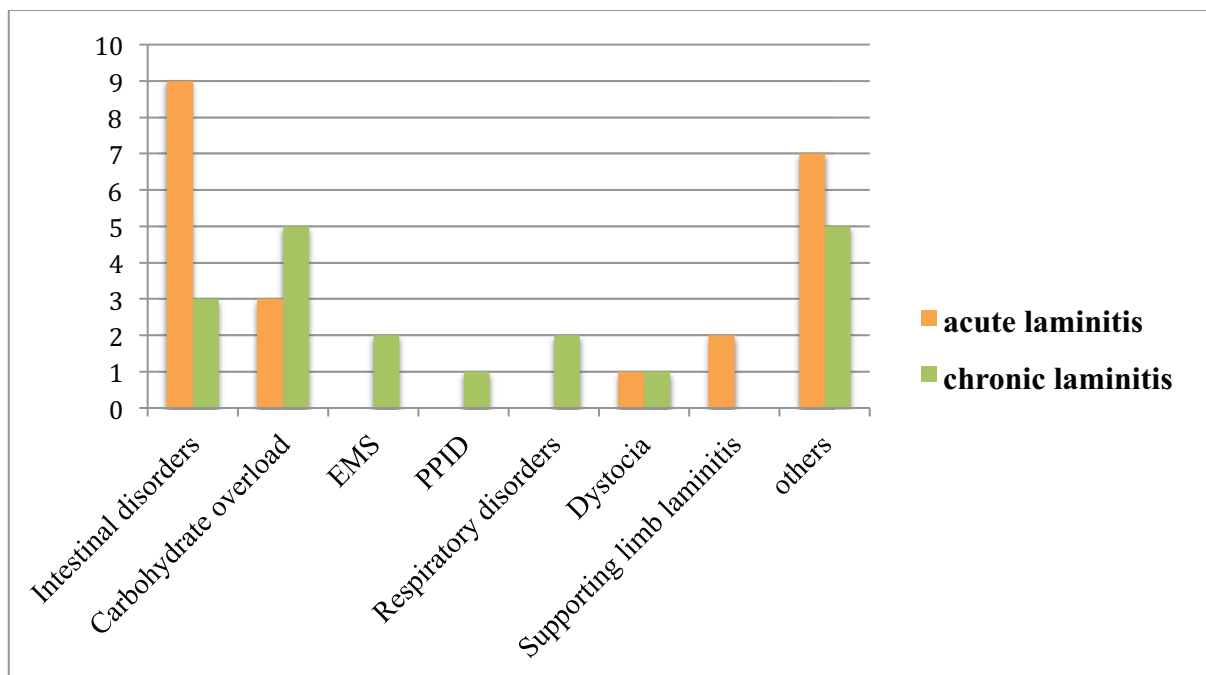


Figure 27: Distribution of acute⁸ and chronic laminitis. Source: own figure

⁸ Animals that were euthanized during the acute phase of laminitis, were not included.

Twenty-two animals developed laminitis during their hospitalization, while the majority of 25 horses and ponies were admitted to the large animal clinic already suffering from equine laminitis. The latter group involved all cases of pasture- and grain-induced carbohydrate overload. Among these 25 cases, 36% (9/25) were acute and 64% (16/25) chronic. Six of the horses that developed laminitis during their treatment at the clinic had to be euthanized during the acute phase of the disease, so were excluded from this category in the following counting. Among the remaining 16 animals, 81.25% (13/16) recovered after the acute phase and only 18.75% (3/16) experienced displacement of the distal phalanx.

The most frequently affected limbs were the front limbs, with a proportion of 84.44% (38/45). In 11.11% (5/45) of the cases, all four hooves were laminitic. Two of these animals suffered from acute laminitis, while the other two were diagnosed with chronic laminitis in all four hooves – one pony with pasture-induced carbohydrate overload and one horse with severe pleuropneumonia. 4.44% (2/45) of the horses had more pronounced clinical symptoms of laminitis in their hind limbs, of which one was an acute case and one was a severe chronic case with prolapse of the distal phalanx and fatal outcome (**Figure 28**). Two horses developed acute laminitis in only one of their front hooves as a consequence of an orthopaedic disorder in the contralateral limb. These cases were excluded from the statistics as the type of limb affected by supporting limb laminitis is predetermined by the site of the underlying orthopaedic disorder.

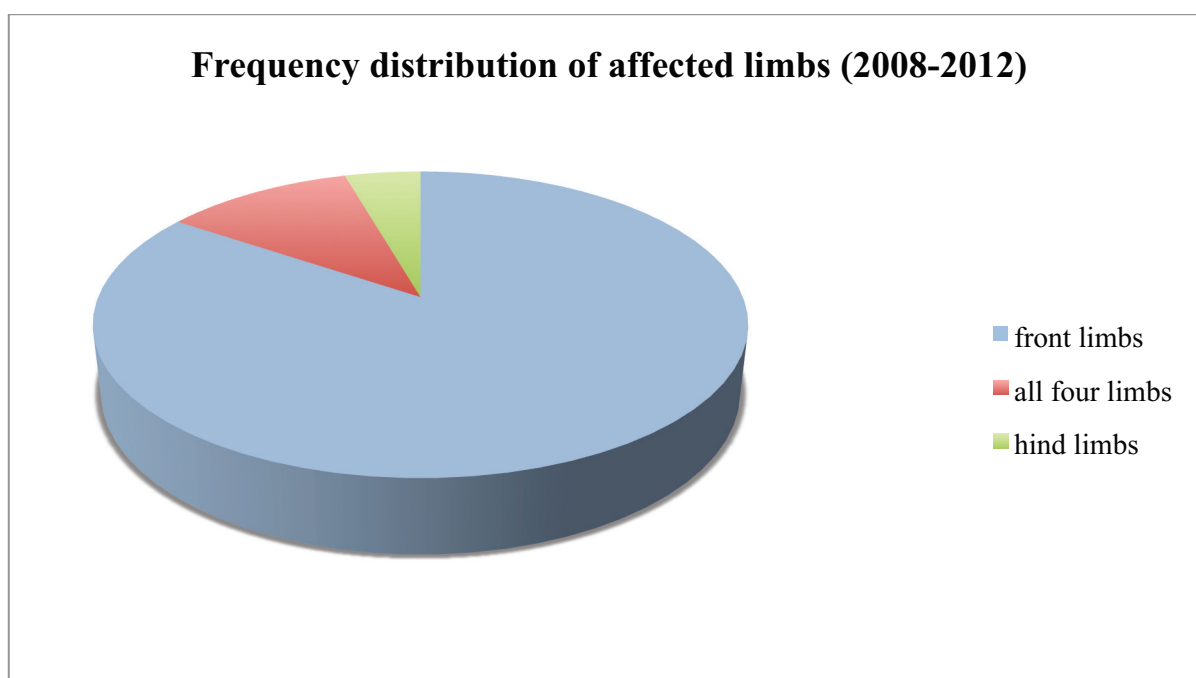


Figure 28: *Frequency distribution of the type of limbs affected by equine laminitis.*

Source: own figure

62.5% (10/16) of the animals with laminitis triggered by intestinal disorders underwent colic surgery, of which 40% (4/10) had to be euthanized afterwards. Both cases of supporting limb laminitis, one case of grain overfeeding and one case of EMS with intestinal obstruction were also treated surgically.

It is worth mentioning that among the animals with intestinal disorders, 2 of the 3 horses that developed chronic laminitis were suffering from chronic intestinal diseases like chronic colitis, while all the other animals had acute intestinal disorders like intestinal strangulation, large colon displacement or intestinal herniation. However, of the animals with acute intestinal disorders, only one horse developed chronic laminitis after it was discharged from the clinic.

According to the information obtained from the owners, the following outcomes can be noted: among the animals with acute laminitis, 80% (12/15) regained their previous performance, whereas 20% (3/15) could only be used for light exercise. However, one of these 3 horses had supporting limb laminitis, thus its impaired performance may be a consequence of the underlying orthopaedic disorder rather than a consequence of acute laminitis. Another of these horses is only used for light exercise because of its advanced age. Among the horses and ponies with chronic laminitis, 57.14% (8/14) were euthanized either because of the chronic hoof disease alone or a combination of chronic laminitis plus the severity of the underlying disease. 28.57% (4/14) animals can perform light exercise, one horse is pasture-sound and only one horse regained its previous performance (**Figure 29**).

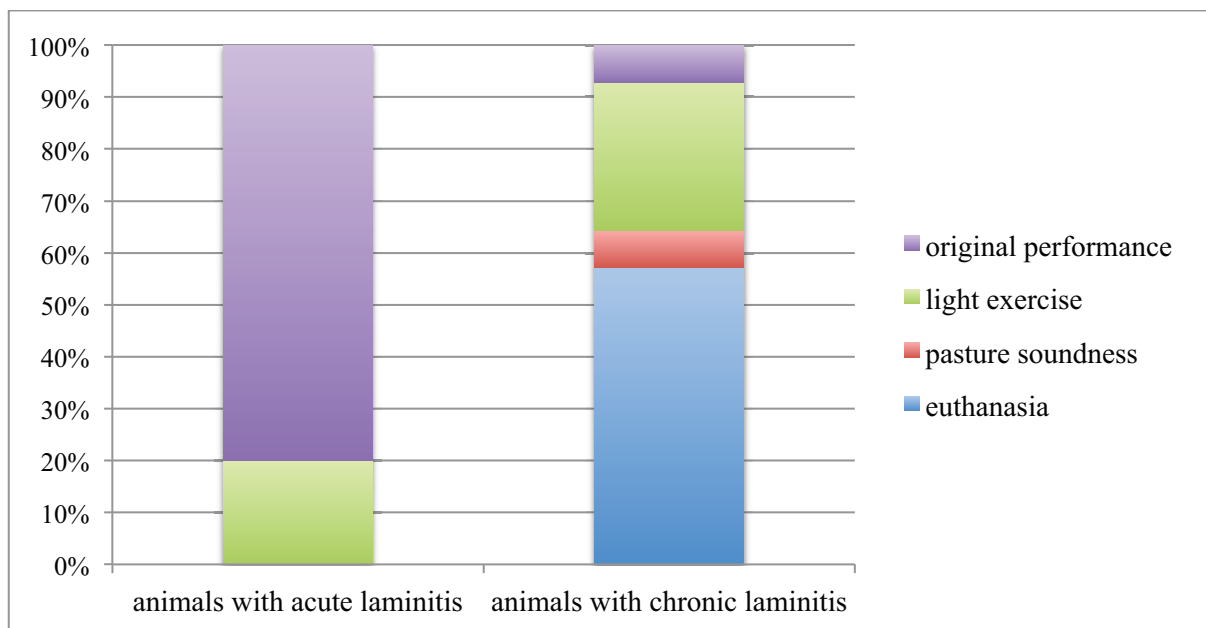


Figure 29: Comparative frequency distribution of the outcomes in acute and chronic laminitis

Source: own figure

Six horses with acute laminitis were excluded from this listing, as they were euthanized because of a disease other than laminitis prior to recovery or progression of the acute phase. In 11 of the 47 cases in this study it was not possible to get in contact with the owner, thus no data about the disease's outcome could be obtained. And one pony, suffering from pasture-induced chronic laminitis in all four hooves, was still hospitalized at the time the survey was conducted. The most recent discharge from the clinic was about 1.5 months prior to the conducted survey and involved one pony with EMS and chronic laminitis that had by then returned to light exercise.

The annual average of the number of equine animals treated during the years 2009 and 2010 was 705. In these two years, the average number of animals that suffered from an intestinal disorder, other than carbohydrate-overload, was 180, and an annual average of 158 animals were examined and/or treated for lameness. The mean number of reported cases of equine laminitis during that period was 12, of which 45.83% of the cases (5.5 individuals on annual average) were caused by intestinal disorders.

DISCUSSION

According to the results presented here, a laminitis frequency of 1.7% was estimated over a two-year period in all hospital out- and inpatients. In comparison with a previous retrospective study on equine laminitis that estimated the overall frequency at 1.5% to 34% (Wylie et al., 2011), the frequency of laminitis cases at the SZIE-ÁOTK large animal clinic was relatively low. However, this result only reflects the laminitis frequency among hospital patients rather than general equine populations.

Equine laminitis is supposed to be responsible for approximately 15% of all cases of equine lameness (Huntington et al., 2009). The proportion of equine laminitis among all equine lameness cases was only at approximately 7.6% in this study.

A general survey conducted by the United States Department of Agriculture in the year 2000 stated that the most commonly listed cause of laminitis in the USA was the pasture-induced type with an incidence of 45% (USDA, 2000). The results presented here show that the most frequent causes of laminitis at the SZIE-ÁOTK Clinic for Large Animals, Üllő, were intestinal disorders, such as intestinal strangulations, inflammations, herniation, obstructions, or displacement of the large intestine. The high proportion of surgery cases in this category reflects the severity of the animals' medical condition.

However, as among the cases with indeterminate causes of laminitis there may also have been several cases of carbohydrate overload, their frequency is probably higher than determined in

the present study. Furthermore, it must be noted that this study only applies to the SZIE-ÁOTK Clinic for Large Animals, Üllő, rather than for the local equine population, as several cases were admitted from other countries, and because many horses and ponies with equine laminitis are treated by self-employed veterinarians and not referred to the clinic. This might especially be the case in pasture-induced laminitis, as there is usually no life-threatening underlying disease.

3.06% of all animals that were admitted to the clinic with intestinal disorders developed laminitis during their hospitalization. This result shows that even though intestinal disorders were the most frequent cause of laminitis determined by this study, the frequency of laminitis in patients with intestinal diseases was rather low. The fact that the proportion of animals with intestinal problems is quite high among all hospital in- and outpatients, contributes greatly to the observation that intestinal disturbances were the most frequently reported cause of laminitis.

In most of the animals that developed laminitis during their hospitalization, mainly triggered by acute diseases, such as intestinal strangulation, dystocia or distal limb fracture, laminitis did not run a chronic course but subsided after the acute phase. Only 3 of the horses experienced displacement of the distal phalanx, despite immediate treatment: one horse with dystocia, one with severe pleuropneumonia and one with chronic colitis. However, the last-mentioned was discharged from the clinic with acute laminitis and the disease progressed to a chronic stage after the animal had been transported back home to Denmark. It seems likely that increased stress, caused by the transportation, and the fact that the horse had to load the laminitic hooves during this extremely long journey may have contributed to the deterioration of the disease, which finally led to euthanasia of the animal.

Even though neither acepromazine nor heparin has been proven effective during the acute stage by previous scientific studies, the present study shows that it might have some positive effect, as most of the horses that received this medical treatment as soon as symptoms of acute laminitis were detected, recovered after the acute phase. Unfortunately, from the 9 cases of stallions in the present study that did not receive acepromazine, no information about possible deleterious effects on the progression of the acute disease by dispensation with acepromazine could be obtained. 2 of the stallions had to be euthanized during the acute phase, 4 stallions already suffered from chronic laminitis at the time of admission, and only the remaining 3 stallions recovered after the acute phase. Even though the theory that vasodilation may contribute to lamellar damage by facilitating the influx of laminitis trigger-factors from the intestine or other sites of inflammation seems reasonable (Pollitt, 2008), a

negative effect of the administration of acepromazine in cases of intestinal disorder couldn't be proven.

Pentoxifylline was administered only in very few cases, due to the financial limitations of the owners. However, the effectiveness of pentoxifylline is doubtful, as a recent study with equine whole blood detected that pentoxifylline hastens collagen-induced platelet aggregation (Kornreich et al., 2010). Microvascular thrombosis would impair the lamellar blood flow, thereby not only delaying the healing process but contributing to ischemic injuries of the suspensory apparatus of the distal phalanx. The capacity of pentoxifylline to inhibit tumor necrosis factor alpha (TNF- α) (van Eps, 2010a), may have an advantageous or preventive effect in the developmental or early acute phase, as TNF- α can induce pro-MMP release and pro-MT-MMP expression in the lamellar basement membrane and is thought to be an important laminitis trigger-factor (Clutterbuck et al., 2010). However, if administered during the chronic phase, any advantageous effect of pentoxifylline is doubtful and the high costs plus the possible side-effect of platelet aggregation may be reasons to exclude it from the treatment plan in chronic cases.

According to the present results, it appears that the longer the animal is exposed to laminitis-predisposing factors, for example a high blood-insulin level, intestine-derived bacterial substances or inflammatory mediators, the more severe is the progression of laminitis. This may also be connected to the circumstance that some chronic medical conditions like chronic inflammations, equine metabolic syndrome, equine Cushing's disease, pasture-induced carbohydrate overload and the resulting hyperinsulinemia can remain undiagnosed for a relatively long period of time. Horses and ponies affected by those chronic disorders often suffer from recurrent mild bouts of laminitis that go undetected by the owner until the disease reaches a more severe stage.

Contrary to the generally satisfactory results of the treatment of acute laminitis, more than half of the horses and ponies with chronic laminitis had to be euthanized on humane grounds. Neither hoof wall resection nor deep digital flexor tenotomy was performed in any of these cases. The author believes that for the future, both of these surgical procedures would offer a relatively encouraging treatment option in chronic cases that are unresponsive to medical treatment and therapeutic shoeing. Deep digital flexor tenotomy at the midcannon level had a success rate of 60% in refractory cases of chronic laminitis presented by another retrospective study (Eastman et al., 1998). Venographic examinations could be introduced as a method to determine the severity of the perfusion deficit of the hoof, thus evaluating the necessity of surgical intervention. In the author's opinion the application of hoof casts may not be the best

treatment option, especially in cases of chronic laminitis. Although it seemed to have no disadvantages if applied during the acute phase, the rigidity of the cast may create increased pressure on the sole, thus enhancing the compression of the blood vessels and increasing the pressure on the tip of the pedal bone and the solar corium (Parks, 2003). Hoof casts present a relatively simple, fast and inexpensive way of raising the heels, thus decreasing the stress on the dorsal laminae and the pain, and might therefore be favoured over commercially available heel wedges. However, to reduce their possible adverse effects, the addition of more pliable sole-support material should be taken into consideration. Additional comfort for the laminitic animal would also be provided by the relocation of the breakover point in cases of rotation of the distal phalanx. The ideal breakover point can easily be determined by means of lateromedial X-rays and can be relocated by either rasping the cured cast material or by moulding it into the desired rolled-toe shape while it is still malleable. However, a wooden clog, which can simply be purchased or made out of a piece of plywood (Pollitt, 2008), would be better suited for this purpose. Another inexpensive, simple and expeditious alternative to hoof casting is the application of sole-supporting foam pads. Even though heel elevation is difficult to achieve, the horse can find a comfortable hoof angle by loading and compressing the foam pad in a way that provides the greatest relief from pain.

The front hooves are generally most frequently affected by equine laminitis, as they experience the greatest weightload – up to 65% of the animal's bodyweight (Pollitt, 2008). This creates additional stress on the digital laminae when they are exposed to laminitis trigger factors. In this study, the front limbs showed easily the most frequent signs of acute or chronic laminitis. However, there have been some acute as well as chronic cases with all four hooves involved: in one case the symptoms of acute laminitis were more pronounced in the hind limbs, and in one case of PPID, severe chronic laminitis and prolapse of the distal phalanx appeared in the hind limbs only. In the latter case the horse was severely overweight when it was admitted to the clinic, already suffering from chronic laminitis in the hind limbs. The hoof-pastern axis, the conformation of the hoof, and the animal's bodyweight probably also have some influence on the type of limbs that are affected most severely by a laminitic insult. Unfortunately, no comparative data have been collected about the hoof angle and conformation before or after the development of laminitis.

For the future, examining the quality of the hooves and keeping a record of the animal's body condition, hoof angle and conformation could aid to identify the animals that are at a higher risk of developing laminitis and may illuminate the observation that, unlike the majority of

laminitic horses and ponies, some animals suffer from more severe laminitis in the hind limbs.

SUMMARY

Although equine laminitis has apparently been known for more than 2000 years (Heymering, 2010), the disease is still not completely understood and requires further research. Numerous treatment strategies are applied, but the overall success rate is still unsatisfactory. Furthermore, the establishment of an efficient treatment plan is complicated by the diversity of underlying diseases and the individual nature of each case.

The results obtained from this retrospective study may contribute to clinical decision-making by presenting outcomes of chronic and acute cases of equine laminitis over a 5-year period. Whereas acute laminitis could be managed adequately by medical and supportive care in the majority of cases, the treatment failed in most of the animals suffering from chronic laminitis. 57.14% of these animals were euthanized during their hospitalization or within a short period following their discharge from the clinic. Some of these horses and ponies might have benefited from surgical intervention, and deep digital flexor tenotomy or hoof wall resection may save those animals that are unresponsive to other treatment strategies.

No adverse effects of acepromazine or heparin during the acute phase were noted in any of the cases. In fact, most animals that received this medical treatment plus hoof casts recovered without progressing to the chronic phase and 80% of all animals with acute laminitis regained their original performance. In addition, those animals that were admitted during or before the onset of the acute phase of laminitis received immediate medical treatment against any underlying diseases. As a result it can be assumed that the faster the underlying diseases, thus the laminitis trigger-factors, are eliminated and the clinical symptoms of laminitis are detected and reacted to, the better are the chances for complete recovery.

The most frequent cause of equine laminitis, determined in this study, was disorders of the equine intestinal tract with a share of 34.04%. Frequent monitoring of the hooves of horses and ponies with prolonged and severe intestinal disorders or inflammatory diseases; prophylactic administration of acepromazine and heparin; and preventive cooling of the distal limbs may help to entirely spare these animals and their owners the distress associated with equine laminitis.

Even though the overall frequency of equine laminitis was rather low in this study (1.7%), the disease is definitely a very serious medical condition which, if allowed to progress, can quite often have a fatal outcome. Many cases of equine laminitis go undetected for a long period of

time until it is too late for the horse or pony to gain a satisfactory degree of recovery and to return to its original performance. Therefore, understanding the numerous risk factors for laminitis and how to prevent or control them, as well as recognizing the symptoms of laminitis are paramount. However, it is equally important to understand the pathomechanisms and the course of the disease in order to create a more targeted and effective treatment plan that can be tailored to individual cases.

APPENDIX 1 – ABBREVIATIONS & ACRONYMS

ACP	-	acepromazine
ACTH	-	adrenocorticotrophic hormone
AD	-	anno domini
AELRU	-	Australian Equine Laminitis Research Unit
AGEs	-	advanced glycation end products
AVAs	-	arteriovenous shunts
BC	-	before Christ
BWE	-	black walnut extract
cm	-	centimetres
COX	-	cyclooxygenase
DAMP	-	danger-associated molecular pattern
DDFT	-	deep digital flexor tendon
DMSO	-	dimethylsulfoxide
EMS	-	Equine Metabolic Syndrome
EVA	-	ethylene vinyl acetate
g	-	grams
GLUT-1	-	insulin-independent glucose transporter 1
GLUT-4	-	insulin-dependent glucose transporter 4
HDPD	-	hoof distal phalangeal distance
HE	-	hematoxylin eosin
IL	-	interleukin
IU	-	international units
kg	-	kilograms
MCP-1	-	monocyte chemotactic protein-1
mg	-	milligrams
ml	-	millilitres
mm	-	millimeters
MMP	-	matrix metalloproteinase
mRNA	-	messenger rionucleic acid
MT-MMP	-	membrane-type matrix metalloproteinase
NO	-	nitric oxide
NSAID	-	non-steroidal anti-inflammatory drug
p.	-	page
P3	-	third phalanx
PAMP	-	pathogen-associated molecular pattern
PAS	-	periodic acid-Schiff staining
PCR	-	polymerase chain reaction
PPID	-	Pituitary Pars Intermedia Dysfunction
RAGE	-	signal transducing receptor
RNA	-	ribonucleic acid
ROS	-	reactive oxygen species
scFOS	-	short-chain fructooligosaccharides
SIRS	-	systemic inflammatory response syndrome
spp.	-	species pluralis
SZIE-ÁOTK	-	Szent István Egyetem, Állatorvos-tudományi Kar
TIMP	-	tissue inhibitors of metalloproteinases
TM	-	trade mark
TNF- α	-	tumor necrosis factor alpha
USA	-	United States of America
WSC	-	water-soluble carbohydrates
μ IU	-	micro international units
$^{\circ}$ C	-	degrees Celsius

APPENDIX 2 – LIST OF REFERENCES

- Acosta de Pérez, O., Teibler, P., Leiva, L., Ríos, E., Sanchez Negrette, M., and Pollitt, C.C. (2006): Equine laminitis: Bites by *Bothrops* spp cause hoof lamellar pathology in the contralateral as well as in the bitten limb. *Toxicon*. 48. vol. 3. no. p. 307-312
- Anderson, E.A., Hoffman, R.P., Balon, T.W., Sinkey, C.A., and Mark, A.L. (1991): Hyperinsulinemia produces both sympathetic neural activation and vasodilation in normal humans. *Journal of Clinical Investigation*. 87. vol. 6. no. p. 2246-2252
- Asplin, K.E., Sillence, M.N., Pollitt, C.C., and McGowan, C.M. (2007a): Induction of laminitis by prolonged hyperinsulinaemia in clinically normal ponies. *Veterinary Journal*. 174. vol. 3. no. p. 530-535
- Asplin, K.E., McGowan, C.M., Pollitt, C.C., Curlewis, J., and Sillence, M.N. (2007b): Role of insulin in glucose uptake in the equine hoof. 25th Annual American College of Veterinary Internal Medicine Forum, Seattle, June 6-June 9, 2007. In: *Journal of Veterinary Internal Medicine: Research Abstract Program of the 25th Annual ACVIM Forum*. p. 668-668
- Bailey, S.R. (2010): Corticosteroid associated laminitis. *Veterinary Clinics of North America: Equine Practice*. 26. vol. 2. no. p. 277-285
- Bailey, S.R., Adair, H.S., Reinemeyer, C.R., Morgan, S.J., Brooks, A.C., Longhofer, S.L., and Elliott, J. (2009): Plasma concentrations of endotoxin and platelet activation in the developmental stage of oligofructose-induced laminitis. *Veterinary Immunology and Immunopathology*. 129. vol. 3-4. no. p. 167-173
- Bailey, S.R., Menzies-Gow, N.J., Marr, C.M., and Elliott, J. (2004a): The effects of vasoactive amines found in the equine hindgut on digital blood flow in the normal horse. *Equine Veterinary Journal*. 36. vol. 3. no. p. 267-272
- Bailey, S.R., Marr, C.M., and Elliott, J. (2004b): Current research and theories on the pathogenesis of acute laminitis in the horse. *Veterinary Journal*. 167. vol. 2. no. p. 129-142
- Baldwin, G.I., and Pollitt, C.C. (2010): Progression of venographic changes after experimentally induced laminitis. *Veterinary Clinics of North America: Equine Practice*. 26. vol. 1. no. p. 135-140
- Belknap, J.K. (2010): Black walnut extract: An inflammatory model. *Veterinary Clinics of North America: Equine Practice*. 26. vol. 1. no. p. 95-101
- Belknap, J.K., Giguère, S., Pettigrew, A., Cochran, A.M., van Eps, A.W., and Pollitt, C.C. (2007): Lamellar pro-inflammatory cytokine expression patterns in laminitis at the developmental stage and at the onset of lameness: innate vs. adaptive immune response. *Equine Veterinary Journal*. 39. vol. 1. no. p. 42-47

- Belknap, J.K. (2001): Medical treatment options in equine laminitis. In: Morris, D.D. (ed.): Compendium on Continuing Education for the Practicing Veterinarian. 23. vol. 10. no. p. 918-921
- Bergsten, C. (2003): Causes, risk factors, and prevention of laminitis and related claw lesions. *Acta Veterinaria Scandinavica*. 44. vol. 1. no. p. 157-166
- Cassens, D.L., and Hooser, S.B. (2005): Laminitis caused by black walnut wood residue. Forestry and Natural Resources Extension Publication. Retrieved September 1, 2012, from: <http://www.extension.purdue.edu/extmedia/FNR/FNR-254.pdf>
- Chan, D.C.W., Fong, D.H.F., Leung, J.Y.Y., Patil, N.G., and Leung, G.K.K. (2007): Maggot debridement therapy in chronic wound care. *Hong Kong Medical Journal*. 13. vol. 5. no. p. 382-386
- Clutterbuck, A.L., Harris, P., Allaway, D., and Mobasheri, A. (2010): Matrix metalloproteinases in inflammatory pathologies of the horse. *Veterinary Journal*. 183. vol. 1. no. p. 27-38
- Collins, S.N., van Eps, A.W., Pollitt, C.C., and Kuwano, A. (2010): The lamellar wedge. *Veterinary Clinics of North America: Equine Practice*. 26. vol. 1. no. p. 179-195
- Cominetti, M.R., Ribeiro, J.U., Fox, J.W., and Selistre-de-Araujo, H.S. (2003): BaG, a new dimeric metalloproteinase/disintegrin from the Bothrops alternatus snake venom that interacts with alpha5beta1 integrin. *Archives of Biochemistry and Biophysics*. 416. vol. 2. no. p. 171-179
- Crandell, K.M. (1999): Selenium – how important is it? *Equine News*. 2. vol. 4. no. p. 9-11. Retrieved November 14, 2012, from: <http://www.ker.com/library/equine/v2n4/v2n409.pdf>
- Dana, M.N., and Lerner, B.R. (1994): Black walnut toxicity. In: Purdue University Cooperative Extension Service, HO-193. p. 1-2. Retrieved November 14, 2012, from: <http://www.extension.purdue.edu/extmedia/HO/HO-193.pdf>
- Davis, R.B., and Palmer, M.J. (1965): Thrombocytopenia and release of platelet amines induced by thrombin and bacterial lipopolysaccharide - Observations after infusion of low molecular weight dextran. *British Journal of Experimental Pathology*. 46. vol. 5. no. p. 554-563
- De Laat, M.A., Pollitt, C.C., Walsh, D.M., McGowan, C.M., and Sillence, M.N. (2012a): Persistent digital hyperthermia over a 48 h period does not induce laminitis in horses. *Veterinary Journal*. 192. vol. 3. no. p. 435-440
- De Laat, M.A., Kyaw-Tanner, M.T., Sillence, M.N., McGowan, C.M., and Pollitt, C.C. (2012b): Advanced glycation endproducts in horses with insulin-induced laminitis. *Veterinary Immunology and Immunopathology*. 145. vol. 1-2. no. p. 395-401

- De Laat, M.A., van Eps, A.W., McGowan, C.M., Silience, M.N., and Pollitt, C.C. (2011a): Equine laminitis: Comparative histopathology 48 hours after experimental induction with insulin or alimentary oligofructose in Standardbred horses. *Journal of Comparative Pathology*. 145. vol. 4. no. p. 399-409
- De Laat, M.A., Kyaw-Tanner, M.T., Nourian, A.R., McGowan, C.M., Silience, M.N., and Pollitt, C.C. (2011b): The developmental and acute phases of insulin-induced laminitis involve minimal metalloproteinase activity. *Veterinary Immunology and Immunopathology*. 140. vol. 3-4. no. p. 275-281
- De Laat, M.A., Mc Gowan, C.M., Silience, M.N., and Pollitt, C.C. (2010): Equine laminitis: Induced by 48 h hyperinsulinaemia in Standardbred horses. *Equine Veterinary Journal*. 42. vol. 2. no. p. 129-135
- Divers, T.J. (2010): Clinical application of current research findings toward the prevention and treatment of acute laminitis in horses with systemic inflammatory diseases: An internist's perspective. *Journal of Equine Veterinary Science*. 30. vol. 9. no. p. 517-524
- Eastman, T.G., Honnas, C.M., Hague, B.A., and Moyer, W. (1998): Deep digital flexor tenotomy as a treatment for chronic laminitis in horses: 37 cases. *AAEP Proceedings*. 44. vol. p. 265-266. Retrieved October 4, 2012, from: <http://www.ivis.org/proceedings/AAEP/1998/Eastman.pdf>
- Eustace, R.A., and Emery, S.L. (2009): Case Report: Partial coronary epidermectomy (coronary peel), dorsodistal wall fenestration and deep digital flexor tenotomy to treat severe acute founder in a Connemara pony. *Equine Veterinary Education*. 21. vol. 2. no. p. 91-99
- Eustace, R.A. (1992): Explaining laminitis and its prevention. Cherokee (AL): Life Data Labs. p. 70
- Eustace, R.A. (1991): Equine pituitary neoplasia. *In Practice*. 13. vol. 4. no. p. 147-148
- Eustace, R.A., and Caldwell, M.N. (1989): The construction of the heart bar shoe and the technique of dorsal wall resection. *Equine Veterinary Journal*. 21. vol. 5. no. p. 367-369
- Faleiros, R.R., Johnson, P.J., Nuovo, G.J., Messer, N.T., Black, S.J., and Belknap, J.K. (2011): Laminar leukocyte accumulation in horses with carbohydrate overload-induced laminitis. *Journal of Veterinary Internal Medicine*. 25. vol. 1. no. p. 107-115
- Floyd, A.E. (2007a): Grading the laminitic horse. In: Floyd, A.E., and Mansmann, R.A.: Equine podiatry. St Louis, Missouri (USA): Saunders Elsevier. p. 320-327
- Floyd, A.E. (2007b): An approach to the treatment of the laminitic horse. In: Floyd, A.E., and Mansmann, R.A.: Equine podiatry. St Louis, Missouri (USA): Saunders Elsevier. p. 347-358

- Floyd, A.E. (2007c): Environmental management of the severely laminitic horse. In: Floyd, A.E., and Mansmann, R.A.: *Equine podiatry*. St Louis, Missouri (USA): Saunders Elsevier. p. 359-369
- Frank, N. (2011): Equine metabolic syndrome. *Veterinary Clinics of North America: Equine Practice*. 27. vol. 1. no. p. 73-92
- French, K.R., and Pollitt, C.C. (2004): Equine laminitis: Glucose deprivation and MMP activation induce dermo-epidermal separation in vitro. *Equine Veterinary Journal*. 36. vol. 3. no. p. 261-266
- Geor, R.J., and Frank, N. (2009): Metabolic syndrome – From human organ disease to laminar failure in equids. *Veterinary Immunology and Immunopathology*. 129. vol. 3-4. no. p. 151-154
- Hamilton-Fletcher, R. (2004): *Veterinary advice on laminitis in horses*. Dorking, Surrey (UK): Ringpress books. p. 48
- Hampson, B.A., and Pollitt, C.C. (2011): Improving the foot health of the domestic horse – The relevance of the feral horse foot model. Canberra (Australia): Rural Industries Research and Development Corporation. p. 46. Retrieved August 7, 2012, from: <https://rirdc.infoservices.com.au/downloads/11-140>
- Harper, F. (2002): Vitamin E in horses. In: University of Tennessee Agricultural Extension Service, AS-H 126. p. 1-5. Retrieved November 14, 2012, from: <http://animalscience.ag.utk.edu/horse/pdf/VitaminEinHorses4-23-03.pdf>
- Hertsch, B., and Teschner, D. (2011): Das Hornwachstum bei der chronischen Hufrehe des Pferdes. *Tierärztliche Praxis Großtiere*. 39. vol. 3. no. p. 163-170
- Heymering, H. (2010): Historical perspective of laminitis. *Veterinary Clinics of North America: Equine Practice*. 26. vol. 1. no. p. 1-11
- Holbrook, T.C., Tipton, T., and McFarlane, D. (2012): Neutrophil and cytokine dysregulation in hyperinsulinemic obese horses. *Veterinary Immunology and Immunopathology*. 145. vol. 1-2. no. p. 283-289
- Hood, D.M. (1999): Laminitis as a systemic disease. *Veterinary Clinics of North America: Equine Practice*. 15. vol. 2. no. p. 481-494
- Huntington, P., Pollitt, C.C., and McGowan, C.M. (2009): Recent research into laminitis. In: Pagan, J.D. (ed.): *Advances in equine nutrition IV*. Nottingham: Nottingham University Press. p. 293-312
- Hurley, D.J., Hurley, K.A., Galland, K.L., Baker, B., Berghaus, L.J., Moore, J.N., and Majerle, R.S. (2011): Evaluation of the ability of aqueous black walnut extracts to induce the production of reactive oxygen species. *American Journal of Veterinary Research*. 72. vol. 3. no. p. 308-317

- Jurga, F., with Morrison, S. (2006): Maggot debridement therapy. Alternative therapy for hoof infection and necrosis. *Hoofcare & Lameness*. 78. vol. p. 28-31. Retrieved November 15, 2012, from: http://www.hoofcare.com/article_pdf/HoofcareMaggotsMorrison.pdf
- Katwa, L.C., Johnson, P.J., Ganjam, V.K., Kreeger, J.M., and Messer, N.T. (1999): Expression of endothelin in equine laminitis. *Equine Veterinary Journal*. 31. vol. 3. no. p. 243-247
- Keen, J.A., McGorum, B.C., Hillier, C., and Nally, J.E. (2012): Short-term incubation of equine laminar veins with cortisol and insulin alters contractility in vitro: Possible implications for the pathogenesis of equine laminitis. *Journal of Veterinary Pharmacology and Therapeutics*. E-pub September 5, 2012
- Kornreich, B., Enyeart, M., Jesty, S.A., Nydam, D.V., and Divers, T. (2010): The effects of pentoxifylline on equine platelet aggregation. *Journal of Veterinary Internal Medicine*. 24. vol. 5. no. p. 1196-1202
- Kramer, J. (2006): Deep digital flexor tenotomy. In: Wilson, D.A., Kramer, J., Constantinescu, G.M., and Branson, K.R.: *Manual of Equine Field Surgery*. St Louis, Missouri (USA): Saunders Elsevier. p. 98-102
- Kyaw-Tanner, M.T., Wattle, O., van Eps, A.W., and Pollitt, C.C. (2008): Equine laminitis: Membrane type matrix metalloproteinase-1 (MMP-14) is involved in acute phase onset. *Equine Veterinary Journal*. 40. vol. 5. no. p. 482-487
- Leise, B.S., Yin, C., Pettigrew, A., and Belknap, J.K. (2010): Proinflammatory cytokine responses of cultured equine keratinocytes to bacterial pathogen-associated molecular pattern motifs. *Equine Veterinary Journal*. 42. vol. 4. no. p. 294-303
- Loftus, J.P., Johnson, P.J., Belknap, J.K., Pettigrew, A., and Black, S.J. (2009): Leukocyte-derived and endogenous matrix metalloproteinases in the lamellae of horses with naturally acquired and experimentally induced laminitis. *Veterinary Immunology and Immunopathology*. 129. vol. 3-4. no. p. 221-230
- Loftus, J.P., Belknap, J.K., and Black, S.J. (2006): Matrix metalloproteinase-9 in laminae of black walnut extract treated horses correlates with neutrophil abundance. *Veterinary Immunology and Immunopathology*. 113. vol. 3-4. no. p. 267-276
- McGowan, C.M. (2005): Diagnosis and treatment of equine Cushings syndrome. *The Veterinarian*. Retrieved August 20, 2012, from: http://www.laminitisresearch.org/downloads/chrispollitt_McGowan%20-%20Clinical%20Review_final.pdf
- McKenzie, E.C. (2007): Polyuria and polydipsia in horses. *Veterinary Clinics of North America: Equine Practice*. 23. vol. 3. no. p. 641-653
- Messer, N.T. (1999): How to diagnose equine pituitary pars intermedia dysfunction. *AAEP Proceedings*. 45. vol. p. 145-147. Retrieved September 24, from: <http://www.ivis.org/proceedings/AAEP/1999/145.pdf>

- Milnovich, G.J., Klieve, A.V., Pollitt, C.C., and Trott, D.J. (2010): Microbial events in the hindgut during carbohydrate-induced equine laminitis. *Veterinary Clinics of North America: Equine Practice*. 26. vol. 1. no. p. 79-94
- Morrison, S. (2010a): Chronic laminitis: Foot management. *Veterinary Clinics of North America: Equine Practice*. 26. vol. 2. no. p. 425-446
- Morrison, S. (2010b): Maggot debridement therapy for laminitis. *Veterinary Clinics of North America: Equine Practice*. 26. vol. 2. no. p. 447-450
- Noschka, E., Moore, J.N., Peroni, J.F., Lewis, S.J., Morrow, J.D., and Robertson, T.P. (2009): Thromboxane and isoprostanes as inflammatory and vasoactive mediators in black walnut heartwood extract induced equine laminitis. *Veterinary Immunology and Immunopathology*. 129. vol. 3-4. no. p. 200-210
- O'Grady, S.E. (2010): Farriery for chronic laminitis. *Veterinary Clinics of North America: Equine Practice*. 26. vol. 2. no. p. 407-423
- Onishi, J.C., Park, J.W., Häggblom, M.M., Fennell, M.J., and Fugaro, M.N. (2012): Chronic laminitis is associated with potential bacterial pathogens in the laminae. *Veterinary Microbiology*. 158. vol. 3-4. no. p. 329-336
- Orsini, J.A. (2011): Laminitis: Prevention and early intervention in surgical and medical case management. *Journal of Equine Veterinary Science*. 31. vol. 10. no. p. 598-603
- Orsini, J.A., Galantino-Homer, H., and Pollitt, C.C. (2009): Laminitis in horses: Through the lens of systems theory. *Journal of Equine Veterinary Science*. 29. vol. 2. no. p. 105-114
- Parks, A.H. (1999): Equine foot wounds: General principles of healing and treatment. *Proceedings of the Annual Convention of the American Association of Equine Practitioners*. 45. vol. p. 180-187. Retrieved November 16, 2012, from: <http://www.ivis.org/proceedings/AAEP/1999/180.pdf>
- Parks, A.H. (2003): Treatment of acute laminitis. *Equine Veterinary Education*. 15. vol. 5. no. p. 273-280
- Peroni, J.F., Moore, J.N., Noschka, E., Grafton, M.E., Aceves-Avila, M., Lewis, S.J., and Robertson, T.P. (2006): Predisposition for venoconstriction in the equine laminar dermis: Implications in equine laminitis. *Journal of Applied Physiology*. 100. vol. 3. no. p. 759-763
- Pollitt, C.C. (2008): Equine laminitis – Current concepts. Canberra (Australia): Rural Industries Research and Development Corporation. p. 116
- Pollitt, C.C. (1991): The role of arteriovenous anastomoses in the pathophysiology of equine laminitis. *Proceedings of the Annual Convention of the American Association of Equine Practitioners*. 37. vol. p. 711-720. Retrieved July 18, 2012, from: http://www.laminitisresearch.org/downloads/chrispollitt_PollittBookChapter.pdf

- Proal, A. (2008): Understanding biofilms. Retrieved October 6, 2012, from: <http://bacteriality.com/2008/05/26/biofilm/>
- Radostits, O.M., Gay, C.C., Hinchcliff, K.W., and Constable, P.D. (2007): *Veterinary medicine – A textbook of the diseases of cattle, horses, sheep, pigs and goats*. Philadelphia (USA): Saunders Elsevier. p. 2156
- Ramsey, G.D., Hunter, P.J., and Nash, M.P. (2011): The effect of hoof angle variations on dorsal lamellar load in the equine hoof. *Equine Veterinary Journal*. 43. vol. 5. no. p. 536-542
- Redden, R.F. (2005): Laminitis: Causes and cures. In: Pagan, J.D. (ed.): *Advances in equine nutrition IV*. Nottingham: Nottingham University Press. p. 439-445
- Redden, R.F. (2004): Preventing laminitis in the contralateral limb of horses with non-weight-bearing lameness. *Clinical Techniques in Equine Practice*. 3. vol. 1. no. p. 57-63
- Reilly, P.T., Dean, E.K., and Orsini, J.A. (2010): First aid for the laminitic foot: Therapeutic and mechanical support. *Veterinary Clinics of North America: Equine Practice*. 26. vol. 2. no. p. 451-458
- Rendle, D. (2006): Equine laminitis 1. Management in the acute stage. *In Practice*. 28. vol. 8. no. p. 434-443
- Respondek, F., Myers, K., Smith, T.L., Wagner, A., and Geor, R.J. (2011): Dietary supplementation with short-chain fructo-oligosaccharides improves insulin sensitivity in obese horses. *Journal of Animal Science*. 89. vol. 1. no. p. 77-83
- Respondek, F., Goachet, A.G., and Julliand, V. (2008): Effects of dietary short-chain fructooligosaccharides on the intestinal microflora of horses subjected to a sudden change in diet. *Journal of Animal Science*. 86. vol. 2. no. p. 316-323
- Rooney, J. (n.d.): White line disease. Retrieved September 13, 2012, from: <http://www.horseshoes.com/farrierssites/sites/rooney/whitlinedisease1/whitlinedisease1.htm>
- Rucker, A. (2010): Chronic laminitis: Strategic hoof wall resection. *Veterinary Clinics of North America: Equine Practice*. 26. vol. 1. no. p. 197-205
- Sakazaki, R., and Miura, S. (1956): The enteric bacterial flora of the intestinal tract of healthy horses. *Japanese Journal of Veterinary Research*. 4. vol. 2. no. p. 57-63
- Scott, E.M., Greenwood, J.P., Vacca, G., Stoker, J.B., Gilbey, S.G., and Mary, D.A.S.G. (2002): Carbohydrate ingestion, with transient endogenous insulinaemia, produces both sympathetic activation and vasodilation in normal humans. *Clinical Science*. 102. vol. 5. p. 523-529
- Sillence, M.N., Asplin, K.E., Pollitt, C.C., and McGowan, C.M. (2007): What causes equine laminitis? The role of impaired glucose uptake. Kingston (Australia): Rural Industries Research and Development Corporation. p. 34

- Steward, M.L. (n.d.): How to apply expanded ethylene vinyl acetate (EVA) and EVA/wooden therapeutic shoes to enhance soundness and healing in equine laminitis. Retrieved August 26, 2012, from: http://www.equicast.us/images/Applying_EVA_Wood_Steward.pdf
- Stewart, J.H. (2003): Feeding to improve hoof quality. Retrieved November 14, 2012, from: <http://www.mitavite.com.au/mitavite06/PDF/Nutritional%20Information%20PDF/Vet%20notes/Feeding%20to%20Improve%20Hoof%20Quality.pdf>
- Suagee, J.K., Corl, B.A., and Geor, R.J. (2012): A potential role for pro-inflammatory cytokines in the development of insulin resistance in horses. *Animals*. 2. vol. 2. no. p. 243-260. Retrieved May 7, 2012, from: <http://www.mdpi.com/2076-2615/2/2/243/pdf>
- Suagee, J.K., Corl, B.A., Crisman, M.V., Hulver, M.W., McCutcheon, L.J., and Geor, R.J. (2011): Effects of acute hyperinsulinemia on inflammatory proteins in horses. *Veterinary Immunology and Immunopathology*. 142. vol. 3-4. no. p. 141-146
- Suganami, T., and Ogawa, Y. (2010): Adipose tissue macrophages: Their role in adipose tissue remodeling. *Journal of Leukocyte Biology*. 88. vol. 1. no. p. 33-39. Retrieved October 6, 2012, from: <http://www.jleukbio.org/content/88/1/33.full.pdf>
- Tadros, E.M., and Frank, N. (2012): Effects of continuous or intermittent lipopolysaccharide administration for 48 hours on the systemic inflammatory response in horses. *American Journal of Veterinary Research*. 73. vol. 9. no. p. 1394-1402
- Tiley, H.A., Geor, R.J., and McCutcheon, L.J. (2007): Effects of dexamethasone on glucose dynamics and insulin sensitivity in healthy horses. *American Journal of Veterinary Research*. 68. vol. 7. no. p. 753-759
- Treiber, K.H., Kronfeld, D.S., Hess, T.M., Byrd, B.M., Splan, R.K., and Staniar, W.B. (2006): Evaluation of genetic and metabolic predispositions and nutritional risk factors for pasture-associated laminitis in ponies. *Journal of the American Veterinary Medical Association*. 228. vol. 10. no. p. 1538-1545
- Tóth, F., Frank, N., Chameroy, K.A., and Bostont, R.C. (2009): Effects of endotoxaemia and carbohydrate overload on glucose and insulin dynamics and the development of laminitis in horses. *Equine Veterinary Journal*. 41. vol. 9. no. p. 852-858
- Tóth, F., Frank, N., Elliott, S.B., Geor, R.J., and Boston, R.C. (2008): Effects of an intravenous endotoxin challenge on glucose and insulin dynamics in horses. *American Journal of Veterinary Research*. 69. vol. 1. no. p. 82-88
- Van Eps, A.W. (2010a): Acute laminitis: Medical and supportive therapy. *Veterinary Clinics of North America: Equine Practice*. 26. vol. 1. no. p. 103-114
- Van Eps, A.W. (2010b): Therapeutic hypothermia (cryotherapy) to prevent and treat acute laminitis. *Veterinary Clinics of North America: Equine Practice*. 26. vol. 1. no. p. 125-133

- Virgin, J.E., Goodrich, L.R., Baxter, G.M., and Rao, S. (2011): Incidence of support limb laminitis in horses treated with half limb, full limb or transfixation pin casts: A retrospective study of 113 horses (2000-2009). *Equine Veterinary Journal*. 43. vol. Suppl. 40 p. 7-11
- Visser, M.B., and Pollitt, C.C. (2011a): Lamellar leukocyte infiltration and involvement of IL-6 during oligofructose-induced equine laminitis development. *Veterinary Immunology and Immunopathology*. 144. vol. 1-2. no. p. 120-128
- Visser, M.B., and Pollitt, C.C. (2011b): Immunohistochemical distribution of laminin-332 and collagen type IV in the basement membrane of normal horses and horses with induced laminitis. *Journal of Comparative Pathology*. 145. vol. 1. no. p. 80-87
- Walsh, D.M., McGowan, C.M., McGowan, T.W., Lamb, S.V., Schanbacher, B.J., and Place, N.J. (2007): Equine Cushing's disease/equine metabolic syndrome: a practitioner field study. In: *The Fourth International Equine Conference on Laminitis and Diseases of the Foot*, West Palm Beach, Florida, USA. Retrieved October 5, 2012, from: <http://www.vet.cornell.edu/labs/Place/docs/31Walshetal.2007.pdf>
- Watts, K.A., and Pollitt, C.C. (2010): Equine laminitis – Managing pasture to reduce the risk. Canberra (Australia): Rural Industries Research and Development Corporation. p. 70. Retrieved July 18, 2012, from: <https://rirdc.infoservices.com.au/downloads/10-063>
- Weiss, D.J., Evanson, O.A., McClenahan, D., Fagliari, J.J., and Jenkin, K. (1997): Evaluation of platelet activation and platelet-neutrophil aggregates in ponies with alimentary laminitis. *American Journal of Veterinary Research*. 58. vol. 12. no. p. 1376-1380
- Weiss, D.J., Geor, R.J., Johnston, G., and Trent, A.M. (1994): Microvascular thrombosis associated with onset of acute laminitis in ponies. *American Journal of Veterinary Research*. 55. vol. 5. no. p. 606-612
- White, N.A. (2005): Equine laminitis. The Waltham International Nutritional Science Symposium, Washington DC, September 14, 2005. Retrieved July 18, 2012, from: http://www.vetmed.vt.edu/emc/welcome/bios/white/equine_laminitis.pdf
- Wissdorf, H., Gerhards, H., Huskamp, B., and Deegen, E. (2002): Praxisorientierte Anatomie und Propädeutik des Pferde. Hannover (GER): M & H Schaper. p. 944
- Worster, A.A., Gaughan, E.M., and Hoskinson, J. (2001): Effects of external thermal manipulation on laminar temperature and perfusion of the equine digit. *AAEP Proceedings*. 47. vol. p. 329-333. Retrieved September 25, 2012, from: <http://www.avis.org/proceedings/AAEP/2001/91010100329.pdf>
- Wylie, C.E., Collins, S.N., Verheyen, K.L., and Newton, J.R. (2011): Frequency of equine laminitis: A systematic review with quality appraisal of published evidence. *Veterinary Journal*. 189. vol. 3. no. p. 248-256

ACKNOWLEDGEMENTS

I wish to express my sincere gratitude to Dr. Péter Tóth, my supervisor, for the opportunity to write this thesis, his professional advice and aid, and also for sacrificing his spare time.

A great dept of gratitude is also owed to my sister, Lina, and my close friend, Jan, for their personal support and their patience at all times.

~

I would like to dedicate this work to my parents, Renate and Dr. med. Frank-Detlev Krampf, who enabled me to study veterinary medicine. I am deeply grateful for their constant encouragement and ineffable support.

COPYRIGHT DECLARATION

HuVetA – SZIA

AGREEMENT OF ELECTRONIC PUBLISHING AND DECLARATION REGARDING COPYRIGHT*

Name:

Contact information (e-mail):

Title of document (to upload):

Publication data of document:

Number of files submitted:

With the acceptance of the present agreement the author or the holder of copyright offers non-exclusive rights for HuVetA and SZIA to archive the above document (including its abstract) converted into PDF format protected against copying without changing its content in order to preserve it and ensure access to it.

The author accepts that HuVetA and SZIA store more than one copy (accessible only for the administrators of HuVetA and SZIA) of the document provided by you exclusively for the purposes of ensuring safe storage and recovery if necessary.

You also declare that the provided document is your own work and/or you are entitled to give the permissions included in the present agreement. You also declare that the document is an original one and you do not know about it violating the copyright of anyone else. If the document has a part which you are not the copyright owner of, you have to remark that you got unlimited permission from the copyright owner to give permission for the use of the document according to the present agreement, and the name of the original author is clearly indicated by the parts the copyright of which belong to a third person.

The copyright owner defines the conditions of access as follows:

I give permission to make the document accessible only within the intranet (IP range) of the Szent István University.

I give permission for the in-house reading of the printed version of my document in the library.

The operators of HuVetA/SZIA do not assume any legal responsibility towards the author or copyright holders or organizations for the case if a user would use the material uploaded with permission to HuVetA or SZIA in an unlawful way.

Budapest, day month 2012

signature author/copyright owner

*The present declaration is based on the rector's order number 5/2011. regarding the database of scientific publications written at the Szent Istvan University.